

## Strut graft vs. traditional plating in the management of periprosthetic humeral fractures: a multicentric cohort study

Giuseppe Rollo<sup>1</sup>, Michele Biserni<sup>2</sup>, Gazi Huri<sup>3</sup>, Christian Carulli<sup>4</sup>, Mario Ronga<sup>5</sup>, Michele Bisaccia<sup>6</sup>, David Gomez-Garrido<sup>7</sup>, Nezhir Ziroglu<sup>8</sup>, Enrico Maria Bonura<sup>9</sup>, Andrea Alberto Ruberti<sup>10</sup>, Andrea Schiavone<sup>11</sup>, Luigi Meccariello<sup>1</sup>

<sup>1</sup>Department of Orthopaedics and Traumatology, Vito Fazzi Hospital, Lecce, Italy, <sup>2</sup>Department of Orthopaedics and Traumatology, Santa Maria della Stella, Orvieto, Terni, Italy, <sup>3</sup>Orthopaedics and Traumatology Department, Hacettepe University School of Medicine, Ankara, Turkey, <sup>4</sup>Orthopaedics Clinic, University of Firenze, Firenze, Italy, <sup>5</sup>Department of Medicine and Health Sciences "Vincenzo Tiberio" University of Molise, Campobasso, Italy, <sup>6</sup>Orthopaedics and Traumatology Unit, Department of Surgical and Biomedical Science, S.M. Misericordia Hospital, University of Perugia, Sant'Andrea delle Fratte, Perugia, Italy, <sup>7</sup>Division of Orthopaedics and Trauma Surgery, Hospital Quirónsalud y Hospital Laboral Solimat, Toledo, Spain, <sup>8</sup>Bakirkoy Dr. Sadi Konuk Training & Research Hospital Istanbul, Turkey, <sup>9</sup> Department of Orthopaedics and Traumatology, Poliambulanza Foundation Hospital, Brescia, Italy, <sup>10</sup>Department of Orthopaedics and Traumatology, Inselspital Bern, Berne, Switzerland, <sup>11</sup>Department of Orthopaedics and Traumatology, Maggiore Hospital, Lodi, Italy

### ABSTRACT

**Aim** The gradual increase in shoulder implants in active elderly patients has appeared in a parallel increase in periprosthetic humeral fractures. The aim of this study was to investigate the advantages of using strut grafting with plate fixation during periprosthetic humerus fractures.

**Methods** Thirty patients diagnosed with periprosthetic humeral fracture were divided into two groups. The first group of 15 patients (PS) underwent plate, ring, screws and strut allografts. The second group with resting 15 patients (PWS) was treated with only plate and screws. The criteria to evaluate the groups during follow-up were the Constant Shoulder Score (CSS) and Oxford Shoulder Score (OSS); the bone healing was measured by X-rays, controls measured by radiographic union score (RUS), and complications. The follow up was terminated at 12nd month in both groups.

**Results** The difference between the two groups in all parameters was not significant. However, all patients gained adequate shoulder motor skills for normal daily living activities. All fractures were healed. Only two complications were registered, and blood loss was minimal.

**Conclusion** We believe a revision to reverse shoulder prosthesis with a long-stem implant with or without cortical strut allograft augmentation to be safe and appropriate in the management of these complex injuries, though technically challenging, and having good results for normal activities daily life.

**Key words:** bone strut, outcomes, bone healing, humeral, ORIF, periprosthetic

### Corresponding author:

Luigi Meccariello

Department of Orthopaedics and Traumatology, Vito Fazzi Hospital  
Piazzetta Muratore, Block:

A Floor:V, 73100, Lecce, Italy

Phone: +39 329 9419 574;

Fax: +39 082 3713 864;

E-mail: drlordmec@gmail.com

ORCID: <https://orcid.org/0000-0002-3669-189X>

### Original submission:

12 February 2019;

### Revised submission:

10 March 2020;

### Accepted:

23 March 2020

doi: 10.17392/1141-20

Med Glas (Zenica) 2020; 17(2): 490-497

## INTRODUCTION

The quality-of-life improvement achieved following total shoulder replacement is satisfactory, which has resulted in a steady increase in the number of shoulder arthroplasties performed each year (1). The gradual increase in shoulder implants in active elderly patients has resulted in a parallel increase of complications like periprosthetic humeral fractures (2), whose incidence varies between 0.6% and 3% of all shoulder prostheses (3). Complications include glenohumeral instability, aseptic loosening, rotator cuff pathology, septic complication, neural injury, deltoid dysfunction and periprosthetic fracture (4). Periprosthetic humeral fractures account for approximately 11% of all complications in shoulder prosthesis (5).

Majority of registered complications were found in patients over the age of 80 years with periprosthetic fracture due to osteoporosis, while in the patients under the age of 75 due to medium or high energy trauma (6). Loss of stem fixation to the humeral bone is rare; however, bone resorption around the humeral stem is more common and can be a risk factor for periprosthetic fracture and failure in the revision surgery (7). Only a few reports have investigated bone resorption after shoulder prosthesis (8,9).

Significant risk factors for periprosthetic fracture include female gender, humeral head replacement accompanying rotator cuff repair, on-growth stem coating, and high size of the implant (7).

Using cortical bone transplants allows the orthopaedic surgeon to combine biological materials with traditional metallic fixation implants.

This study aims to investigate the superiority of bio metallic fixation (plate with allograft bone strut) compared with plate fixation in the surgery of humeral periprosthetic fracture.

## PATIENTS AND METHODS

### Patients and study design

From January 2010 to December 2018, at the seven Trauma Level I Centres (five in Italy, one of each in Turkey and Spain) 30 diaphyseal periprosthetic humeral fractures were treated. Exclusion criteria included: fractures caused by oncological and/or haematological disease, patients under the age of 65 years. Patients who underwent a follow-up of less than 12 months were excluded.

The types of fractures according to the Worland classification (10) were: type A fractures occur about the tuberosities, type B fractures occur about the stem and they are sub-classified by fracture anatomy and implant stability: B1 spiral fractures with a stable implant, B2 transverse or short oblique fractures about the tip of the stem with a stable implant, and B3, those about the stem with an unstable implant; type C fractures occur well distal to the tip of the stem.

The patients were divided into two groups according to their treatment preferences. The first group, plate and strut (PS), was represented by 15 patients treated with plate, strut allografts, screws and cerclage for the humeral periprosthetic fracture. The second group, plate without strut (PWS), was represented by 15 patients suffering from periprosthetic humeral fractures treated solely with plates and screws.

Non-Union Scoring System (NUSS) in retrospective mode was used to examine bone healing (11).

All patients were informed clearly and thoroughly about all possible operative and conservative treatment options. Patients were treated according to the ethical standards of the Helsinki Declaration and read, conceded, approved and signed the informed consent form.

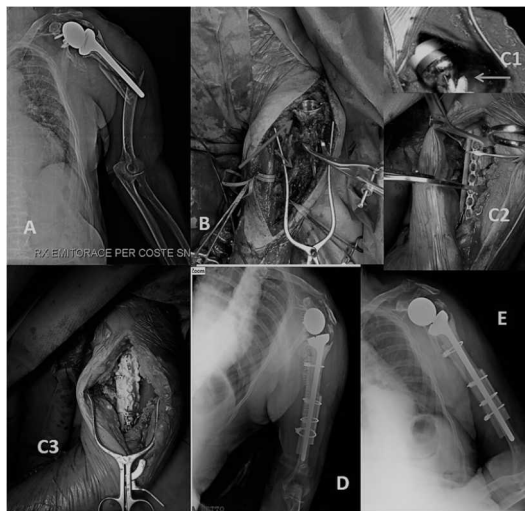
All patients of both groups underwent the same postoperative rehabilitation protocol (see rehabilitation protocol).

Azienda Sanitaria Locale (ASL) Lecce/Italy Ethical Committee approved this research.

### Methods

**Plate and Strut (PS) surgical technique.** Surgery was executed in a beach chair position in 100% of the cases, using the deltopectoral approach with a lateral extension approach. Once the fracture areas were exposed, the previous implants were removed and the fracture line was reduced by surgical means. If the stem was unstable it was revised with a long one. Strut allograft was prepared on a separate table and the humeral shaft plate was temporarily fixed with a K-wire. To stabilize the strut bone allograft and humeral shaft in the bottom, screws were performed. (We used metal cerclage cable in the long stem). Metal cerclage cable was implanted to stabilize medium and top of strut allograft; this was then placed to support the medial humeral wall. Bone

grafts were placed to support the humeral shaft and to fill bone defects (Figure 1). At the end of the operation, the final reduction was evaluated by fluoroscopy in three plans (anterior-posterior - AP, external rotation, and axial).

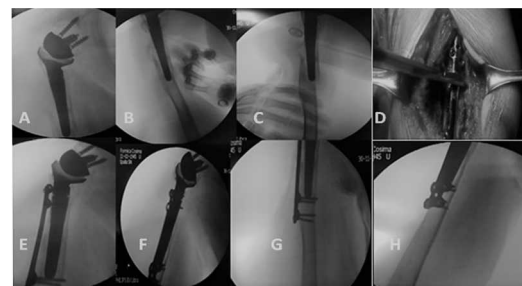


**Figure 1.** A 78-year-old man, who had had a reverse shoulder prosthesis for 10 years, implanted due to fracture of the proximal humerus. A) After a fall from the top, X-ray shows a Type BIII fracture according to Worland; B) the level of fracture and the mobilization of the ascend stem; C1) the re-implantation with long stem and higher size liner (arrow), C2) the osteosynthesis with metal cerclage cables and opposed allograft bone strut, C3) bone chips; D) postsurgical X-ray; E) X-ray inspection after 12 months from surgery (Rollo G, Biserni M, 2017)

**Plate without Strut (PWS) surgical technique.**

In every case, surgery was done in the beach chair position using the deltopectoral approach with the lateral extension approach. After having presented the fracture areas, implants were removed and the fracture was reduced. If the stem was unstable, it was revised with a long one. The humeral shaft plate was provisionally implanted with a k-wire or a clamp. To secure the strut bone allograft and humeral shaft in the bottom, metal cable cerclage and screws were applied. (We used free metal cerclage cable in the long stem). For the stabilization of the medium area, an anatomic pre-shaped low-profile semi-tubular plate was used with multi-planar screw holes (Dyaphesal Humeral Plate, Intrauma Rivoli, Torino, Italy), which provide primary stability to fix the peri-prosthetic fracture (Figure 2). At the end of the procedure, the final fracture was evaluated by fluoroscopy in all plans (anteroposterior, external and internal rotation, and axial view).

**Recovery protocol.** The aim of our protocol was to provide an orientation of postoperative reha-



**Figure 2.** A 71-year-old woman with low-energy trauma to the right upper limb, treated three years before with reverse shoulder prosthesis for total tear rator cuff. A-C) fracture according to Worland type B2; D) treatment with osteosynthesis by locking plate utilizing eccentrically placed screw holes and screws (Dyaphesal Humeral Plate, Intrauma, Rivoli, Torino, Italy); E, F, G) perfect anatomical reduction (Rollo G, 2016)

bilitation course, and to standardize and direct the whole patient population to follow a single physio-kinesiotherapy program to reduce the bias. Stage 1 (first month): Immobilization collar for 4 weeks, Codman exercises, forbidden external rotation movement for the first 6 weeks.

Stage 2 (about weeks 5-9) only if there were clinical data of healing and fragments move as a part, and no displacement was evident on the x-ray, then: lightly passive movement, actively supported forward elevation and abduction, soothing functional use week 3-6 (avoid resistant abduction), progressively decrease help during movement from week 6 on.

Stage 3 (after two months): add isotonic, concentric, and eccentric strengthening activities.

If there was bone healing but joint stiffness, then supplement passive stretching by a physiotherapist.

The chosen principles to evaluate the two groups during the follow-up were: the proximal humeral complication after the two types of surgery, the time of surgery, Constant Shoulder Score (CSS) (12), Oxford Shoulder Score (OSS) (13), radiographic Union Score (RUS) (14), and postoperative complications.

The Constant-Shoulder Score (CSS) (12) is a 100-points scale composed of a number of individual parameters. These parameters define the level of pain and the ability to carry out the normal daily activities of the patient. The Constant-Murley score was introduced to determine the functionality after the treatment of a shoulder injury. The test is divided into four subscales: pain (15 points), activities of daily living (20 points), strength (25 points) and range of motion (forward elevation, external rotation, abduction and internal rotation of the sho-

ulder) (40 points). The higher the score represent the higher the quality of the function. Subjective findings (severity of pain, activities of daily living and working in different positions) of the participants are responsible for 35 points and objective measurements (AROM without pain, measurements exo -and endorotation via reference points and measuring muscle strength) are responsible for the remaining 65 points. The Constant-Murley score is used in almost every language without official translations. In French, a validated translation has been published. The time needed to complete the Constant-Murley test is between 5 to 7 minutes.

The Oxford Shoulder Score (OSS) (13) is a 12-item patient-reported specifically designed and developed for assessing outcomes of shoulder surgery, e.g. for assessing the impact on patients' quality of life of degenerative conditions such as arthritis and rotator cuff problems.

The bone healing was measured by Radiographic Union Score (RUS) (14), the RUS score provided by Litrenta et al. (12) and derived from the RUST scoring system. The RUS provides four component scores of cortical bridging, cortical disappearance, trabecular consolidation, and trabecular disappearance. Each component can be scored from 1 to 3. Similarly, the two trabecular indices were scored from 1-3, each based on consolidation for one of the indices, and fracture line disappearance for the other. The overall RUS score therefore ranged from a minimum of 10 to a maximum of 30.

The follow-up period was set at 12 months in the two groups.

**Statistical analysis**

To summarize the characteristics of this study group and subgroups we used descriptive statistics. This included both means and standard deviations of all continuous variables. The t-test was used to compare continuous outcomes. To compare categorical variables the Fisher exact test was applied (these groups were smaller than 10 patients). The statistical significance was defined as p<0.05. To make a comparison between the predictive score of quality of life and outcomes we used the Pearson correlation coefficient (r). For simplicity of data, mean age was rounded to the closest year, including their standard deviations. Predictive score of outcomes and quality of life and their standard deviations were approximated at the first decimal, while the Pearson correlation coefficient

(r) was approximated at the second decimal. Cohen's kappa (k) was used to determine the reliability and validity of the correlation between functional osteosynthesis and bone healing.

**RESULTS**

The patients of the first group at the time of the injury had a mean age of 76.27 (±12.68; range 68-88), the association between the genders (M: F) was 0.25 (3: 12). Eight (53.33%) patients were due to trauma and the remaining seven (46.67%) due to degenerative joint disease; reverse shoulder implantation was applied. In all cases, cementless implants were applied. The mean in years of survival of the implant before the fracture was 3.2 (±2.34; 1-6). The type of accidents included a fall in six (40.00%), normal daily activities in eight (53.33%), sport in one (6.67%) patient. The types of fractures according the Worland classification (10) were: type A in 0 patients, B1 in five (33.33%), B2 in five (33.33%), B3 in one (6.67%), C in four (26.67%) patients. The most affected dominant side was the left side, in four (26.67%) patients. The average point of the NUSS in PS was 54.89 (±13.74; range 25-70) (Table 1).

**Table 1. Characteristics of the patients treated with (PS) and without plate and strut (PWS)**

| Variable  | PS   | PWS  | p      |
|---|--|--|--------|
| Number of patients  | 15   | 15   | p>0.05 |
| Average age (SD) (years)  | 76.27 (±12.68)   | 76.87(±11.9)   | p>0.05 |
| Range of age (years)  | 68-88  | 66-89  | p>0.05 |
| Gender ratio (M:F)  | 0.25 (3:12)  | 0.25 (3:12)  | p>0.05 |
| Reason for reverse shoulder implant (No, %)                             | Trauma: 8 (53.33)<br>Degenerative joint disease: 7 (46.67)             | Trauma: 8 (53.33)<br>Degenerative joint disease: 7 (46.67)             | p>0.05 |
| Type of implant (No, %)   | Uncemented: 15 (100)<br>Cemented: 0                                    | Uncemented: 15 (100)<br>Cemented: 0                                    | p>0.05 |
| Average implant time before periprosthetic fracture (SD; range) (years) | 3.2 (±2.34; 1-6)   | 3.1 (±2.38 ; 1-7)  | p>0.05 |
| Type of accident (No, %)  | Fall: 6 (40.00)<br>Daily actives: 8 (53.33)<br>Sport: 1 (6.67)         | Fall: 5 (33.33)<br>Daily actives: 8 (55.33)<br>Sport: 2 (13.34)        | p>0.05 |
| Worland Classification (No, %)  | A: 0<br>B1: 5 (33.33)<br>B2: 5 (33.33)<br>B3: 1 (6.67)<br>C: 4 (26.67) | A: 0<br>B1: 4 (26.67)<br>B2: 6 (40.00)<br>B3: 1 (6.67)<br>C: 4 (26.67) | p>0.05 |
| Injured humeral side (No, %)  | Right: 5 (33.33)<br>Left: 10 (66.67)                                   | Right: 5 (33.33)<br>Left: 10 (66.67)                                   | p>0.05 |
| Dominant injured upper limb (No, %)                                     | Right: 2 (13.34)<br>Left: 4 (26.67)                                    | Right: 3 (20.00)<br>Left: 3 (20.00)                                    | p>0.05 |
| Average Nonunion Scoring System (SD)                                    | 54.89 (±13.74)   | 54.9 (±13.79)  | p>0.05 |
| Nonunion Scoring system range   | 25-70  | 25-70  | p>0.05 |

**Table 2. The comparison of the patients treated with (PS) and without plate and strut (PWS)**

| Characteristics   | PS                                       | PWS                                      | p      |
|---|--|--|--------|
| Average surgical time in minutes  | 113.2 (±13.5; range 81 -176)             | 102.6(±13.7; range 79 -175)              | p>0.05 |
| The mean follow up (SD; range) (years) (years)  | 1.4 (±1.8; 1-7)                          | 1.4 (±1.8; 1-7)                          | p>0.05 |
| Average time of X-rays bone healing (SD; range) (days)  | 122.4 (±23.8; 94 -156)                   | 122.7 (±23.7; 95 -158)                   | p>0.05 |
| Type of complications (No, %)   | Blood loss: 465±224.08 mL                | Blood Loss: 474±229.01 mL                | p>0.05 |
|   | Intraoperative fracture: 0               | Intraoperative fracture: 1(6.67)         | p<0.05 |
|   | Postoperative fracture: 1 (6.67)         | Postoperative fracture: 0                | p<0.05 |
|   | Died after 1 year of follow up: 1 (6.67) | Died After 1 year of follow up: 1 (6.67) | p>0.05 |
| Arc of flexion (SD; range)  | 129.57° (±34.36; 67°-168°)               | 129.47° (± 34.28 (66°-169°)              | p>0.05 |
| Arc of extension (SD; range)  | 32.1° (±12.8; 30°-54°)                   | 31.9° (±12.2; 30°-54°)                   | p>0.05 |
| Arc of abduction (SD; range)  | 117.54° (± 36.55; 69°-173°)              | 116.99° (± 36.79; 68°-172°)              | p>0.05 |
| Arc of intrarotation with abduction at 90° (SD; range)  | 61.42° (± 24.54; 38-86)                  | 61.32° (± 24.27; 38-86)                  | p>0.05 |
| Arc of extrarotation in adduction (SD; range)   | 42.20° (± 22.82; 25°-65°)                | 43.20° (± 21.90; 25°-65°)                | p>0.05 |
| Average correlation between osteosynthesis and bone healing at the moment of X-rays bone callus | k=0.8123±0.137795                        | k=0.81236±0.119355                       | p>0.05 |

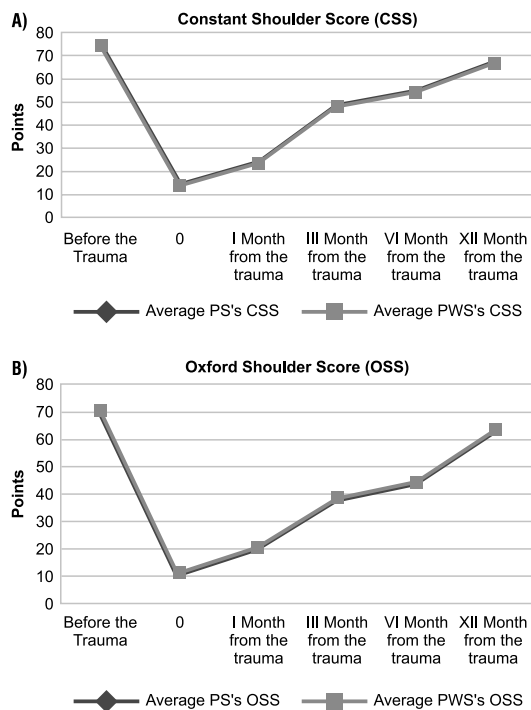
The main purpose of the reverse shoulder implantation was the trauma in eight (53.33%) patients and degenerative shoulder disease in seven (46.67%) patients. In all cases, cementless implants were applied. The mean in years of survival of the implant before the fracture was 3.1 (±2.38; 1-7).

At the endpoint, the complications in PS were: blood loss of 465±224.08 mL, post-operative fracture in one (6.67%), death after one year of follow up in one (6.67%) patient; complications in PWS were: blood loss of 474±229.01 mL, intra operative fracture in one (6.67%), death after one year of follow up in one (6.67%) patient. There was a significant statistical difference between PS and PWS in intra and post-operative fracture (p<0.05) (Table 2).

The average duration of surgical time in the PS group was 113.2 (±13.5; range 81 -176) minutes; in the PWS group it was 102.6 (±13.7; range 79 -175) (p> 0.05). The PS's X-rays bone healing scaled by radiographic union score occurred in our group on average of 122.4 (±23.8; range 94 -156) days after the surgery, while PWS's X-rays bone healing scaled by radiographic union score occurred on average 122.7 (±23.7; range 95 -158) days after the surgery (p>0.05). Also, the arch of abduction averaged 117.54° (± 36.55; range 69°-173°) in group PS and 129,47° (±116.99° (± 36.79; range 68°-172°) in group PWS (p>0.05). The arc of intrarotation with abduction at 90° was in average 61.42°(± 24.54; range 38-86) in PS while 61.32°(± 24.27; range 38-86) in PWS (p>0.05). The arc of extrarotation in adduction was in average 42.20° (± 22.82; range 25°-65°) in PS while 43.20° (± 21.90; range 25°-65°) in PWS (p>0.05) (Table 2).

The objective quality and shoulder function of PS's life before the trauma, measured by CSS, was about 74.3 points (range 46-96) while the quite quality of life before the trauma, measured by CSS, was about 74.2 points (range 48-94) in PWS, p>0.05(Graph.1). At the moment of trauma, in the PS group, the CSS was 14.1 (range 0-30) at the same moment PWS, the CSS was 13.9 (range 0-30) (p>0.05). After 1 month from the revision surgery the CSS score was in 23.5 (range 10-45) PS and 23.6 (range 10-45) in PWS (p>0.05). Also on the third month after the surgery (p>0.05), the difference at three CSS scores was 48.4 in PS (range 25-70 ) and 48.3 in PWS( range 25-70), as well as in the sixth month of follow-up. At 6 months from the revision surgery, in PS the CSS was 54.6 (range 30-85), while in PWS was 54.4 (range 30-85) (p>0.05). At twelve months after the surgery, we had CSS score in PS 66.7(range 30-90), while in PWS was 66.7(range 30-90) (p>0.05) (Figure 3A).

The subjective quality and shoulder function of PS's life before the trauma, measured by OSS, was about 71.2 points (range 40-100), while the quite quality of life before the trauma, measured by OSS, was about 70.9 points (range 40-100) in PWS (p>0.05). At the moment of trauma, in the PS group, the OSS was 11.2 (range 0-24), and in the same moment in PWS, the OSS was 11.1 (range 0-24) (p>0.05). After one month from the revision surgery, the OSS score was in PS 20.4 (range 5-40) and 20.8 (range 5-40) in PWS (p>0.05). At twelve months after the surgery, OSS score in PS was 63.4 (range 40-92), while in PWS it was 63.5 (range 40-92) (p>0.05) (Figure3B).



**Figure 3.** A) Trend of Constant Shoulder Score (CSS) pre and at 1 year after the traumatic event. At twelfth month, there was no statistical differences between PS and PWS group ( $p > 0.05$ ); B) Trend of Subjective Oxford Elbow Score (OES) pre and at 1 year after the traumatic event. At twelfth month, there was no statistical differences between PS and PWS group ( $p > 0.05$ )

The average correlation between osteosynthesis and bone healing at the moment of X-rays was ( $k=0.8123 \pm 0.137795$ ) in PS as in PWS ( $k=0.81236 \pm 0.119355$ ) ( $p > 0.05$ ) (Table 2).

## DISCUSSION

Bone resorption in the humeral stem following shoulder prosthesis has been reported (15), lack of stem fixation to the humeral bone did not happen; nevertheless, the bone nearby the humeral stem can be a risk agent for failure at the time of revision operation and periprosthetic fracture (15). The pathology of humeral bone resorption after total shoulder arthroplasty (TSA) has been described as stress shielding (15). The principal mechanism of osseous absorption following TSA is also considered to be stress shielding (7,8,16). The situation of bone resorption is confined to the proximal zone in TSA, whereas it prolongs more distally in shoulder arthroplasty. Besides, full-thickness cortical bone resorption is rare after TSA (7). Bone resorption was generally seen at the greater tuberosity (Zone 1), lateral diaphysis (Zone 2), and calcar region (Zones 7) (7). Compared to shoulder pro-

sthesis in the humeral, these areas have no traction force from muscles, which may explain the more distal extensivity of bone resorption and a greater tendency towards critical bone resorption (7,8). Another factor is the Rotator cuff gives to osteoporosis at the proximal humerus (17). The lack of weight-bearing can lead to medial cortical reabsorption more easily in humerus than femur (7). Periprosthetic humeral fractures are estimated to account for around 11% of all complications associated with total shoulder prosthesis (16). The latest radiographic studies show that bone resorption was noted: in about 85.7% of patients with humeral stem arthroplasty; full-thickness cortical bone resorption occurred on average 17.7%; mostly happening within the initial year after surgery, and the stress-shielding was exclusively seen with uncemented humeral stems (7,8, 16-18). The biometallic solution associated with stem revision in instability cases is the one most practiced in the treatment of this fracture challenge pattern (2,3,10,11, 19-21). However, even if the stem is not revised and the correct anatomy is not restored, good functional results can be obtained (9). The ability of the humerus to adapt to deformities ( $< 20^\circ$  anterior angulation;  $< 30^\circ$  varus/valgus angulation;  $< 3$  cm shortening) (22), the orthopaedic surgeon does not seek the anatomy and biomechanics needed in the treatment of periprosthetic shoulder fracture (15) or of osteosynthesis failures (23). The time of humeral bone healing or nonunion are also multiple predisposing factors for the origin of these complications: general factors linked to the subject and the situation of fracture (24). Kurowicki et al. (25) describe osteosynthesis method as employing a locking plate using eccentrically disposed screw holes to set "skive screws" in the proximal end of the plate to perform fixation around the stem of the implant. A clinical series of five consecutive cases managed with this procedure was performed with an average follow-up of 29 months (range, 12-48). Two further patients had less than 1-year follow-up. All patients showed fracture healing. Functional outcomes were limited with only patient achieving forward elevation above 90 degrees, and the average American Shoulder and Elbow Surgeons Function score were 28 (25,26). Pain relief was nearly uniform with an average visual analog scale pain score of 0.5 (25). The prosthesis revision should always be performed except in patients with poor prognosis (26). Indeed,

we have reconstituted both in reading and in our study that the revision of periprosthetic fracture (failure) can restore the functionality of the shoulder and its quality of life in most cases to sufficient levels for normal daily life activities and the survival of the system (9, 19-21, 27-30). We have two complications and blood loss normally described in the scientific literature (2,3,9,10, 25-28)

The limitations of the current study were the limited number of patients, non-probability sample of convenience, due to low incidence in the population. Another limit is that it is a retrospective study.

Disadvantages of retrospective studies are inferior level of evidence compared with prospective studies, the patients to confounding (other risk factors may be present that were not measured), cannot determine causation, only association, some key statistics cannot be measured.

Another limitation was that the measurements and intervention were made without randomization of the researcher to the experimental groups, which have the potential for bias. Finally, other limiting factors of the study acknowledged by the authors can be the potential for regression to the mean, the presence of temporal confounders and the mention of the subjective score.

## REFERENCES

1. Boorman RS, Kopjar B, Fehringer E, Churchill RS, Smith K, Matsen FA 3rd. The effect of total shoulder arthroplasty on self-assessed health status is comparable to that of total hip arthroplasty and coronary artery bypass grafting. *J Shoulder Elbow Surg* 2003; 12:158-63.
2. Trompeter AJ, Gupta RR. The management of complex periprosthetic humeral fractures: a case series of strut allograft augmentation, and a review of the literature. *Strat Traum Limb Recon* 2013; 8:43-51.
3. Athwal GS, Sperling JW, Rispoli DM, Cofield RH. Periprosthetic humeral fractures during shoulder arthroplasty. *J Bone Joint Surg Am* 2009; 91:594-603.
4. Sewell MD, Kang SN, Al-Hadithy N, Higgs DS, Bayley I, Falworth M, Lambert SM. Management of peri-prosthetic fracture of the humerus with severe bone loss and loosening of the humeral component after total shoulder replacement. *J Bone Joint Surg Br* 2012; 94:1382-9.
5. Bohsali KI, Wirth MA, Rockwood CA Jr. Complications of total shoulder arthroplasty. *J Bone Joint Surg Am* 2006; 88:2279-92.
6. Bergdahl C, Ekholm C, Wennergren D, Nilsson F, Möller M. Epidemiology and patho-anatomical pattern of 2,011 humeral fractures: data from the Swedish Fracture Register. *BMC Musculoskelet Disord* 2016; 17:159.
7. Inoue K, Suenaga N, Oizumi N, Yamaguchi H, Miyoshi N, Taniguchi N, Munemoto M, Egawa T, Tanaka Y. Humeral bone resorption after anatomic shoulder arthroplasty using an uncemented stem. *J Shoulder Elbow Surg* 2017; 26:1984-9.
8. Spormann C, Durchholz H, Audigé L, Flury M, Schwyzer HK, Simmen BR, Kolling C. Patterns of proximal humeral bone resorption after total shoulder arthroplasty with an uncemented rectangular stem. *J Shoulder Elbow Surg* 2014; 23:1028-35.
9. Carta S, Fortina M, Riva A, Meccariello L, Cataldi C, Colasanti GB, Ferrata P. Is there a rationale in the use of the bone strut allograft for management and internal fixation in periprosthetic humeral fractures? A case report. *EMBJ* 2017; 12:115-8.
10. Kirchoff C, Kirchoff S, Biberthaler P. Periprosthetic humeral fractures: strategies and techniques for osteosynthesis. *Unfallchirurg* 2016; 119:273-80.
11. Calori GM, Colombo M, Mazza EL, Mazzola S, Malagoli E, Marelli N, Corradi A. Validation of the Non-Union Scoring System in 300 long bone non-unions. *Injury* 2014; 45: (Suppl 6):S93-7.
12. Ban I, Troelsen A, Christiansen DH, Svendsen SW, Kristensen MT. Standardised test protocol (Constant Score) for evaluation of functionality in patients with shoulder disorders. *Dan Med J* 2013; 60:A4608.
13. Dawson J, Rogers K, Fitzpatrick R, Carr A. The Oxford shoulder score revisited. *Arch Orthop Trauma Surg* 2009; 129:19-23.

In conclusion, the osteosynthesis of a fracture in general terms has the purpose of obtaining a morphological reconstruction and sufficient mechanical stability to allow early mobilization to cure healing. In the case of periprosthetic fractures, the problems are greater because of the presence of the prosthesis that conditions the use of traditional synthesis means. The use of multiple plaques would have the disadvantage of creating an overly "metallic" engagement, while resorting to the use of bank cortical bone strands has the advantage of supporting a biologically valid biological material as well as osteointegration even if only partially. Finally, we believe a revision to reverse prosthesis with long-stem with or without cortical strut allograft augmentation to be safe and proper in the management of these complex injuries, though technically challenging and having good results for normal daily activities

## FUNDING

No specific funding was received for this study.

## TRANSPARENCY DECLARATION

Conflict of interest: None to declare.

14. Litrenta J, Tornetta P 3rd, Mehta S, Jones C, O'Toole RV, Bhandari M, Kottmeier S, Ostrum R, Egol K, Ricci W, Schemitsch E, Horwitz D. Determination of radiographic healing: an assessment of consistency using RUST and Modified RUST in metadiaphyseal fractures. *J Orthop Trauma* 2015; 29:516-20.
15. Carta S, Fortina M, Riva A, Meccariello L, Manzi E, Di Giovanni A, Ferrata P. The biological metallic versus metallic solution in treating periprosthetic femoral fractures: outcome assessment. *Adv Med* 2016; 2016:2918735.
16. Raiss P, Edwards TB, Deutsch A, Shah A, Bruckner T, Loew M, Boileau P, Walch G. Radiographic changes around humeral components in shoulder arthroplasty. *J Bone Joint Surg Am* 2014; 96:e54.
17. Oh JH, Song BW, Kim SH, Choi JA, Lee JW, Chung SW, Rhie TY. The measurement of bone mineral density of bilateral proximal humeri using DXA in patients with unilateral rotator cuff tear. *Osteoporos Int* 2014; 25:2639-48.
18. Razfar N, Reeves JM, Langohr DG, Willing R, Athwal GS, Johnson JA. Comparison of proximal humeral bone stresses between stemless, short stem, and standard stem length: a finite element analysis. *J Shoulder Elbow Surg* 2016; 25:1076-83.
19. Martinez AA, Calvo A, Cuenca J, Herrera A. Internal fixation and strut allograft augmentation for periprosthetic humeral fractures. *J Orthop Surg (Hong Kong)* 2011; 19:191-3.
20. Kumar S, Sperling JW, Haidukewych GH, Cofield RH. Periprosthetic humeral fractures after shoulder arthroplasty. *J Bone Joint Surg Am* 2004; 86-A:680-9.
21. Wutzler S, Laurer HL, Huhnstock S, Geiger EV, Buehren V, Marzi I. Periprosthetic humeral fractures after shoulder arthroplasty: operative management and functional outcome. *Arch Orthop Trauma Surg* 2009; 129:237-43.
22. Zhang BS, Li WY, Liu XH, Wei J, He L, Wang MY. Comparative results of non-operative and operative treatment of humeral shaft fractures. *Beijing Da Xue Xue Bao* 2017; 49:851-4.
23. Rollo G, Tartaglia N, Falzarano G, Pichierri P, Stasi A, Medici A, Meccariello L. The challenge of non-union in subtrochanteric fractures with breakage of intramedullary nail: evaluation of outcomes in surgery revision with angled blade plate and allograft bone strut. *Eur J Trauma Emerg Surg* 2017; 43:853-61.
24. Calori GM, Colombo M, Bucci MS, Fadigati P, Colombo AI, Mazzola S, Cefalo V, Mazza E. Complications in proximal humeral fractures. *Injury*. 2016; 47(Suppl 4):S54-8.
25. Kurowicki J, Momoh E, Levy JC. Treatment of periprosthetic humerus fractures with open reduction and internal fixation. *J Orthop Trauma* 2016; 30:e369-74.
26. Casier S, Middernacht B, Van Tongel A, De Wilde L. Revision of reversed shoulder arthroplasty: is a reoperation possible? *Obere Extremit* 2017; 12:16-24.
27. Hernandez NM, Chalmers BP, Wagner ER, Sperling JW, Cofield RH, Sanchez-Sotelo J. Revision to reverse total shoulder arthroplasty restores stability for patients with unstable shoulder prostheses. *Clin Orthop Relat Res* 2017; 475:2716-22.
28. Terragnoli F, Zattoni G, Damiani L, Cabrioli A, Li Bassi G. Treatment of proximal humeral fractures with reverse prostheses in elderly patients. *J Orthop Traumatol* 2007; 8:71-6.
29. Rollo G, Rotini R, Pichierri P, Giacomini M, Stasi A, Macchiarola L, Bisaccia M, Meccariello L. Grafting and fixation of proximal humeral aseptic nonunion: a prospective case series. *Clin Cases Miner Bone Metab* 2017; 14:298-304.
30. Rollo G, Pichierri P, Marsilio A, Filippini M, Bisaccia M, Meccariello L. The challenge of nonunion after osteosynthesis of the clavicle: is it a biomechanical or infection problem? *Clin Cases Miner Bone Metab* 2017; 14:372-8.