

Sedation for transesophageal echocardiography: comparison of propofol, midazolam and midazolam-alfentanil combination

Huseyin Toman¹, Atakan Erkilinc², Tuncer Kocak², Fusun Guzelmeric², Omer Faruk Savluk², Mevlut Dogukan³, Goksel Acar⁴

¹Department of Anesthesiology and Reanimation, Canakkale Onsekiz Mart University, School of Medicine, Canakkale, ²Clinic of Anesthesiology and Reanimation, Kartal Kosuyolu High Specialty Education and Research Hospital, Istanbul, ³Department of Anesthesiology and Reanimation, Adiyaman University Training and Research Hospital, Adiyaman, ⁴Clinic of Cardiology, Kartal Kosuyolu High Specialty Education and Research Hospital, Istanbul; Turkey

ABSTRACT

Aim The administration of trans esophageal echocardiography (TEE) may cause nausea, shortness of breath, agitation, emotional distress and pain in patients due to pharyngo-esophageal intubation, which may be partially relieved by sedoanalgesia. The aim of this study was to compare clinical effects of midazolam, midazolam-alfentanil combination and propofol sedation given for sedation and sedoanalgesia to patients with planned diagnostic TEE interventions.

Methods This study was prospectively completed with 90 randomized adult patients in ASA risk groups I-II-III. Group M were given 2.5 mg midazolam, group MA were given 1 mg midazolam and 5 µg/kg alfentanil and group P were given 0.5 mg/kg propofol intravenous bolus. If necessary, additional doses were administered. Patients administered with TEE were evaluated in terms of additional dose requirements, Ramsey Sedation Scale (RSS), modified Aldrete Scoring (MAS), recovery time and duration of stay in the hospital.

Results In the group P additional dose requirements were greater ($p<0.05$), as well as the duration of stay in the recovery unit and hospital were shorter ($p<0.05$). On insertion of the TEE probe, the RSS in the group P was clearly higher than in other groups M and MA ($p<0.05$).

Conclusion During the TEE intervention, the use of propofol, contrary to requirements for additional dose and observation of apnea, appears to be advantageous due to providing more rapid and effective sedation depth without a need of expensive antagonist agents, and allowing early discharge of patients. Additionally, it seems that the use of midazolam combined with alfentanil, is more advantageous comparing to midazolam alone.

Key words: propofol, midazolam, alfentanil, outpatient

Corresponding author:

Huseyin Toman
Department of Anesthesiology and
Reanimation, Canakkale Onsekiz Mart
University, School of Medicine
17100, Canakkale, Turkey
Phone: +90 286 263 5950;
Fax: +90 286 263 5956;
E-mail: huseyintoman@comu.edu.tr

Original submission:

07 July 2015;

Revised submission:

04 August 2015;

Accepted:

07 August 2015.

doi: 10.17392/825-16

Med Glas (Zenica) 2016; 13(1):18-24

INTRODUCTION

Transesophageal echocardiography (TEE) is an imaging method that aids sensitive and correct diagnosis by assessing myocardial contractility, heart valve functions, cardiac volume, thoracic aorta injury, blunt cardiovascular injuries, suspected aorta dissection and some congenital defects (1,2). Compared to transthoracic echocardiography (TTE), TEE has some advantages such as avoiding structures like the chest wall and lung parenchyma from injury, providing increased image quality due to the reduced distance between the probe and the cardiac formations and ability to assess the heart from different angles (3). The fact that TEE requires pharyngo-esophageal intubation to prevent obstruction of the airway is a situation accepted as a disadvantage compared to TTE (4).

No matter how much pharyngo-esophageal intubation during the TEE procedure is accepted as safe, it may cause nausea, shortness of breath, agitation, emotional distress and pain in patients. Fear and anxiety before the procedure may be partially resolved by premedication (4,5). For patients undergoing TEE surficial sedation with topical oropharyngeal anesthesia or other benzodiazepines are used (6). Although midazolam is commonly used as a sedative, it does not have primary analgesic effect. Therefore, this shortfall of midazolam still leads to discomfort during the administration of TEE in most of the patients. Additionally, escape from cumulative hypnotic effect of midazolam takes longer time, thus opioid analgesics can provide better sedoanalgesia in sedation when they combined with low dose of benzodiazepines (7). For sedation alfentanil is used together with benzodiazepines, propofol and sedative hypnotic medications and additionally reduces the dose of the sedative medication it is combined with (8). In addition to the use of propofol may be used for general anesthesia induction in the operating room, it may also be used for sedation aside from the surgery. While low dose propofol creates primary sedation and anxiolysis, increasing the dose produces hypnosis; however there is little to no amnestic effect (9).

The aim of this study was to compare clinical effects of midazolam, midazolam-alfentanil combination and propofol sedation, used for sedation and sedoanalgesia, on the ease of the procedure, hemodynamic response, efficacy, side effects and

duration of hospital stay when used for patients undergoing planned diagnostic TEE intervention.

PATIENTS AND METHODS

This study obtained approval from Istanbul Kartal Koşuyolu Specialization Training and Research Hospital Local Ethics Committee (Kosuyolu/2009). After getting informed consents from patients with planned TEE in the Cardiology Clinic, the prospective and randomized study was completed with 90 outpatient, stable, ASA (American Society of Anesthesiologists) I-II-III risk group (10) adult patients. Each patient who agreed to participate in the study as a volunteer signed the written informed consent forms in accordance with the Declaration of Helsinki.

The patients with severe cardiopulmonary disease, obesity, suspected or confirmed pregnancy, history of allergic reaction to the medications used in the study and those who could not communicate were not included in the study. All patients were asked not to take oral food and fluid for at least 6 hours, and were monitored (Petaş KMA 800) including non-invasive blood pressure, electrocardiogram (ECG) and peripheral oxygen saturation (SpO₂). All cases had venous access provided through a 20 gauge cannula in the back of the right hand and 0.9% saline infusion was begun. Patients undergoing TEE were randomized in sequence and divided into three groups containing 30 patients each: Group M, Group MA and Group P. Topical oropharyngeal anesthesia was provided by 10% lidocaine spray (Xylocaine pump spray, AstraZeneca İlaç San. ve Tic. Ltd. Sti. Istanbul, Turkey). After the patients were positioned as lying on their left side the following anesthetic agents were given for sedation and sedoanalgesia according to group.

Group M patients were given 2.5 mg midazolam (dormicum, Roche İlaç Sanayi A.S. Turkey) for sedation as an intravenous bolus dose. If necessary additional 1 mg or a total maximum dose of 8 mg at 5 minute intervals was administered intravenously. Group MA patients were given 1 mg midazolam and 5 µg/kg alfentanil (rapifen, Johnson & Johnson Sıhhi Malzeme San. ve Tic. Ltd. Sti. Turkey) for sedation as an intravenous bolus dose. According to the hemodynamics and sedation degree of patients, dose titration was completed with an additional dose of 0.5 mg mi-

dazolam as necessary or a total maximum dose of 5 mg at 5 minute intervals, and an additional dose of 2,5 µg/kg alfentanil as required or a total maximum dose of 1000 µg at 5 minute intervals. For sedation of Group P patients 0.5 mg/kg propofol (propofol-lipuro 1%, B. Braun Melsungen AG, Germany) intravenous bolus dose was administered. According to the hemodynamics and sedation degree of the patient, dose titration was completed with an additional dose of 0.25 mg/kg propofol as necessary for the total maximum dose of 300 mg administered.

Two minutes after the intravenous medication administration the TEE probe was inserted. The ease of insertion of the TEE probe (very easy: 1, easy: 2, slightly difficult: 3, very difficult: 4, impossible: 5), the duration of swallowing the probe (in seconds) (duration from entering the mouth to passing the cricopharyngeus), and the duration of the transesophageal echocardiography probe remained in the esophagus for the whole procedure (in min) were recorded. Mean arterial blood pressure (MAP), heart rate (HR), SpO₂ and complications, along with the ease and quality of the procedure, were assessed. The patients were also evaluated using the Ramsey Sedation Scale (RSS) (11) every 5 minutes during the procedure and at the end of the procedure. According to the hemodynamic situation of the patients (increase of more than 10% to 20% in arterial pressure and pulse count per minute) medication titration of the stated dose was given for sedation. Extra dose requirements were recorded. After the transesophageal echocardiography (TEE probe removal, 5th minute, 10th minute, 15th minute, 20th minute, 25th minute, 30th minute and during discharge) at each 5 minute assessment before leaving the transesophageal echocardiography unit, the Modified Aldrete Score (MAS) (11) was used. All TEE procedures were carried out by experienced cardiologists. The procedure was completed with IE33 (Philips Healthcare, Eindhoven, Netherlands) and General Electric Vivid 7 Dimension models (General Electric Company, GE Healthcare, Horten, Norway). During this time intervention was carried out for hypoventilation (<8 respirations/minute), apnea (no respiration for 30 s) and airway obstruction, and oxygen was given through a nasal cannula at 6 L/min for SpO₂ below 93%. If hypoventilation developed the jaw-thrust ma-

neuver was administered. For SpO₂ below 90% hypoxemia was evaluated and recorded.

When evaluating the data, in addition to descriptive statistical methods (mean, standard deviation), the One Way Anova test was used to compare quantitative data with normal distribution between the groups, while the Posthoc Tukey test was used for comparisons within the groups. The χ^2 square test was used to compare categorical data. The results were evaluated with the 95% confidence interval with significance assessed at $p < 0.05$ level.

RESULTS

The study was completed with 90 patients aged between 18 to 77 years undergoing TEE with male/female ratio of 38/52. There was no significant difference between the groups in terms of demographic data ($p > 0.05$) (Table 1).

Table 1. Demographic characteristics of patients who underwent transesophageal echocardiography

	Group M (n=30)	Group MA (n=30)	Group P (n=30)	P
Age (years)	42.8±15.2	44.3±16.9	48.8±18.7	0.83
Gender (M/F)	13/17	12/18	13/17	0.97
Weight (kg)	72.1±13.3	68.5±13.6	68.7±13.4	0.38
Height (cm)	164.4±7.3	163.4±7.2	164.2±7.2	0.43
ASA (I/II/III)	14/14/2	16/13/1	15/9/6	0.59

ASA, (American Society of Anesthesiologists) Physical Classification System (10)

There was no statistically significant difference found between the groups in terms of MAP, HR and SpO₂ values among patients participating in the study at basal time while the TEE probe was inserted, every 5 minutes during the procedure and when the TEE probe was removed ($p > 0.05$).

The total medication amount used was 2.98±0.39 mg midazolam in Group M, 1.60±0.60 mg midazolam and 493±89 µg alfentanil in Group MA and 52±13 mg propofol in Group P. The patient numbers requiring additional medication were observed to be statistically significant when compared between the groups ($p < 0.05$) (Table 2).

There was no statistically significant difference in terms of basal RSS values of the cases when compared between the groups ($p > 0.05$). On insertion of the TEE probe, RSS values remained the same in Group M, fell in Group MA and increased clearly in Group P and this was statistically significant ($p < 0.05$). Comparing Group M with Group

Table 2. Distribution of patients requiring additional medication

Patient's group (medication)	No (%) of patients requiring additional medication
M (2.98±0.39 mg midazolam)	3 (7.9)
MA (1.60±0.60 mg midazolam and 493±89 µg alfentanil)	9 (23.7)
P (52±13 mg propofol)	26 (68.4)

MA and Group P separately in the 5th minute of the procedure, there was a statistical fall in RSS observed ($p < 0.05$). In the 10th and 15th minutes of the procedure the RSS in Group MA was found to be much higher than in Group M ($p < 0.05$). In the 20th and 25th minutes and when the TEE probe was removed the RSS in all 3 groups was not found to be statistically significant when compared among themselves ($p > 0.05$) (Figure 1).

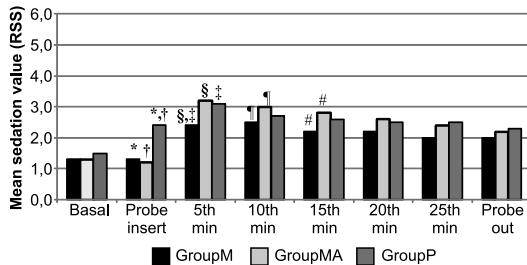


Figure 1. Ramsey sedation scale (RSS) insertion transesophageal echocardiography probe time graphic in the three groups of patients

*RSS higher for Group P compared to Group M while probe is inserted ($p < 0.05$); †RSS higher for Group P compared to Group MA while probe is inserted ($p < 0.05$); ‡RSS higher for Group MA compared to Group M in the 5th minute of the procedure ($p < 0.05$); §RSS higher for Group P compared to Group M in the 5th minute of the procedure ($p < 0.05$); ¶RSS higher for Group MA compared to Group M in the 10th minute of the procedure ($p < 0.05$); #RSS higher for Group MA compared to Group M in the 15th minute of the procedure ($p < 0.05$)

When the duration to swallow the TEE probe of the cases is examined, comparison between the groups found no significant difference ($p > 0.05$). On comparison between the groups of ease of TEE probe swallowing, no statistically significant difference was observed ($p > 0.05$). Comparison of the duration the TEE probe remained in the esophagus did not identify any significant statistical differences between the 3 groups ($p > 0.05$). Comparing the MAP, HR and SpO₂ values measured every 5 minutes after the procedure and during discharge for patients participating in the study between the groups, there was no statistically significant difference found between the 3 groups ($p > 0.05$).

When the TEE probe was removed the MAS in Group M was found to be statistically higher

compared to Group P ($p < 0.05$). In the 5th and 10th minute in the recovery unit, the MAS values of Group P were found to be high compared to Group M and Group MA ($p < 0.05$). The patients in Group P were all discharged before the 10th minute. The patients in Group MA were discharged before the 20th minute while the patients in Group M were discharged by the 30th minute on average (Figure 2).

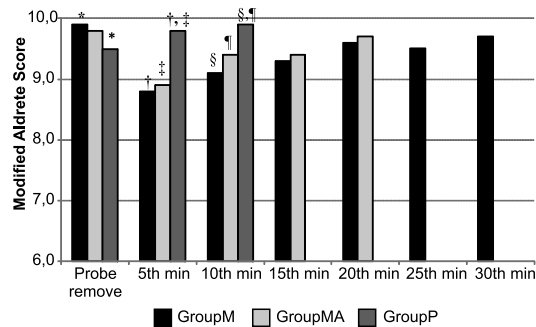


Figure 2. Modified Aldrete Score (MAS) insertion transesophageal echocardiography probe time graphic in the three groups of patients

*MAS higher for Group M compared to Group P as probe is removed ($p < 0.05$); †MAS higher for Group P compared to Group M in 5th minute in recovery unit ($p < 0.05$); ‡MAS higher for Group P compared to Group MA in 5th minute in recovery unit ($p < 0.05$); §MAS higher for Group P compared to Group M in 5th minute in recovery unit ($p < 0.05$); ¶MAS higher for Group P compared to Group MA in 10th minute in recovery unit ($p < 0.05$)

Comparing the duration of recovery of patients after the procedure in the three groups, a statistically significant difference was observed ($p < 0.05$). In Group P the duration of stay in hospital was shorter compared to Group M and Group MA ($p < 0.05$). Comparing the total hospital stay of Group M and Group MA, no statistical significance was found ($p > 0.05$) (Table 3).

Table 3. Recovery duration after the procedure in the three groups of patients

Patient's group (medication)	Recovery duration (minutes)*	Total hospital stay duration (minutes)†
M (2.98±0.39 mg midazolam)	18±7	32±8
MA (1.60±0.60 mg midazolam and 493±89 µg alfentanil)	14±7	28±9
P (52±13 mg propofol)	6±2	18±5

* $p < 0.05$ (shorter in the Group P compared to Group M and Group MA); † $p > 0.05$ (Group M and Group MA)

Of 90 patients undergoing TEE in the study, four patients in Group M, one patient in Group MA and five patients in Group P required nasal mask due to SpO₂ dropping below 93%. In all three groups one patient had nausea. Two patients in Group P developed apnea.

DISCUSSION

The results of this study have shown that patients sedated with propofol required more additional doses than those patients sedated with midazolam and low dose midazolam combined with alfentanil. Moreover, the patients given propofol entered sedation more quickly than those given midazolam or low-dose midazolam combined with alfentanil, staying in the recovery unit for less period of time resulting in shortened hospital stays.

Though TEE entered widespread clinical use at the beginning of the 1980s, sedation with the TEE procedure only began to be discussed at the beginning of the 1990s (12). Within this time interval, though a variety of sedatives were used, midazolam was one of the most frequently used agents (13,14). Here the most important reason for choosing midazolam, we believe, is that sedation is administered by cardiologists more than anesthetists and in negative situations that may occur it can be antagonized with flumazenil. The duration of effect of flumazenil is short, so it may require repeated doses to prevent the reoccurrence of sedation (15). Additionally, in this duration, monitoring of the patient and the cost of the medication appear as negative factors. Our aim was to find the ideal sedative agent, providing rapid sedation, requiring no expensive antagonists after the procedure ends and allowing rapid recovery.

It is observed in many studies that different doses of midazolam, alfentanil and propofol have been used for sedation. While 0.02 mg/kg intravenous bolus midazolam was used by Pratila et al. (16), Renna et al. (7) administered 2.5 mg intravenous bolus. McHardy et al. (17) combined 0.015 mg/kg midazolam with 5 mcg/kg alfentanil while Smith et al. (18) recommended the use of bolus intravenous propofol of 0.2-0.7 mg/kg. In the present study 2.5 mg of midazolam was administered as an intravenous bolus dose for sedation in midazolam group of patients, 1 mg intravenous dose of midazolam and 5-10 µg/kg alfentanil in midazolam-alfentanil group, and 0.5 mg/kg of propofol in propofol group of patients. Additional dose requirements were provided by dose titration depending on the hemodynamics and degree of sedation of the patients.

The onset of effect of the sedation doses of the medications is less than 1 minute for propofol,

1-2.5 minutes for midazolam and 55 seconds for alfentanil (19,20). The onset duration may differ depending on many factors such as the dose of medication, duration of administration and patient age, cardiovascular situation, metabolism speed, etc (21). In our study the sedation score for propofol was high when the TEE probe was inserted and 5 minutes after insertion; we believe this may be due to the very short onset of effect of propofol. The sedation score for the low-dose midazolam and alfentanil combination was high 5 minutes after the TEE probe was inserted, showing onset only after 2 minutes due to the synergistic effects of the combination in intravenous administration. Though the sedation level with midazolam was at the requested level, in the 5th minute after probe insertion it was high, which shows that the onset of the combination only occurred 2 minutes after intravenous administration.

The mean duration of action of the medications is 3-10 minutes for propofol, 30-60 minutes for midazolam and 10 minutes for alfentanil (20,22,23). A synergistic effect occurs with the combination of midazolam and alfentanil, and this synergistic effect changes according to the dose and ratio of midazolam and alfentanil in the combination (24). As a result, very different durations of action may be encountered. In our study the mean duration of action of the combination of low-dose midazolam and alfentanil, while much longer than propofol, appeared to be shorter than midazolam alone. As a result the additional medication requirements were highest for patients given propofol and lowest for those patients given midazolam alone.

The recovery duration is determined by the elimination half-life of used anesthetic medications, repeated doses especially lengthen the elimination half-life and lengthen recovery duration (25). For rapid removal of sedation and quick recovery sedative agents with high clearance and short elimination half-life should be used. Propofol is one of the medications with shortest half-life of any current intravenous agents, and this duration is 30-60 minutes, with plasma clearance of 2000 ml/min, thus more rapid recovery (26). Midazolam is the agent with shortest elimination half-life among benzodiazepines at 90-150 minutes with plasma clearance of 300-500 mL/min (27). Alfentanil has an elimination half-life of 90-111

minutes, with plasma clearance of 356 mL/min (20). During alfentanil sedation the midazolam dose is reduced, recovery time shortens and good sedoanalgesia is provided (28). In our study patients given propofol with shortest mean duration of action had quicker recovery, this was followed by recovery of patients given midazolam alfentanil combination and it was observed that the patients given midazolam alone recovered latest. Modified Aldrete Score is a scale used during recovery to show when the patient has fully awoken from sedation, and the stages of hemodynamic protective reflexes and motor activity returning to normal. The MAS shows parallels to the recovery duration. In our study patients sedated with propofol had MAS of 9-10 in the first 10 minutes and were discharged from the hospital. Patients sedated with midazolam and alfentanil combination had MAS of 9-10 in the 20th minute and were completely discharged. All patients sedated with midazolam alone were discharged by the 30th minute.

During sedation with propofol hypoxemia or rarely apnea may be observed (29), oxygen given through a nasal cannula increases the patient's pO₂ levels preventing or reducing the creation of apnea. In our study two patients sedated with propofol were observed to develop apnea and required intervention was completed.

According to the results of our study during TEE procedure though propofol use required additio-

nal dose and apnea was observed, it appears to have advantages such as providing more rapid and effective sedation depth without the need for expensive antagonist agents and allowing earlier discharge of patients from hospital. Additionally, it seems that the use of midazolam together with alfentanil is more advantageous than the use of midazolam alone.

In conclusion, during sedation and sedoanalgesia for TEE administration, hemodynamic and respiratory stability was provided, and choosing agents with shorter duration of action provides significant advantages by shortening patient recovery and duration of hospital stay. We have found that the use of propofol was much more advantageous for recovery time and the length of hospital stay, which is consistent with other studies; however midazolam-alfentanil combination could also be used as an alternative to propofol. Additionally, as patients with planned TEE generally have cardiac risks, similar studies of patients with advanced age or higher ASA score measuring cardiac stress markers will provide more information related to the effects of alternative medications.

FUNDING

No specific funding was received for this study

TRANSPARENCY DECLARATION

Competing interests: None to declare.

REFERENCES

- Vignon P, Boncoeur MP, François B, Rambaud G, Maubon A, Gastinne H. Comparison of multiplane transesophageal echocardiography and contrast-enhanced helical CT in the diagnosis of blunt traumatic cardiovascular injuries. *Anesthesiology* 2001; 94:615-22.
- Goarin JP, Cluzel P, Gosgnach M, Lamine K, Coriat P, Riou B. Evaluation of transesophageal echocardiography for diagnosis of traumatic aortic injury. *Anesthesiology* 2000; 93:1373-7.
- Daniel WG, Mügge A. Transesophageal Echocardiography. *N Eng J Med* 1995; 332:1268-79.
- Blondheim DS, Levi D, Marmor AT. Mild sedation before transesophageal echo induces significant hemodynamic and respiratory depression. *Echocardiography* 2004; 21:241-5.
- Daniel WG, Erbel R, Kasper W, Visser CA, Engberding R, Sutherland GR, Grube E, Hanrath P, Maisch B, Dennig K, Scharl M, Kremer P, Angermann C, Illiceto S, Curtius JM, Mügge A. Safety of transesophageal echocardiography. A multicenter survey of 10,419 examinations. *Circulation* 1991; 83:817-21.
- Wenzel RR, Bartel T, Eggebrecht H, Philipp T, Erbel R. Central-nervous side effects of midazolam during transesophageal echocardiography. *J Am Soc Echocardiogr* 2002; 15:1297-300.
- Renna M, Chung R, Li W, Maguire C, Mullen MJ, Chambers J, Henein MY. Remifentanyl plus low-dose midazolam for outpatient sedation in transesophageal echocardiography. *Int J Cardiol* 2009; 136:325-9.
- Vinik, HR, Bradley EL Jr, Kissin I. Triple anesthetic combination: propofol-midazolam-alfentanil. *Anesth Analg* 1994; 78:354-8.
- Ferreira AO, Cravo M. Sedation in gastrointestinal endoscopy: Where are we at in 2014? *World J Gastrointest Endosc* 2015; 16:102-9.
- Koo CY, Hyder JA, Wanderer JP, Eikermann M, Ramachandran SK. A meta-analysis of the predictive accuracy of postoperative mortality using the American Society of Anesthesiologists' physical status classification system. *World J Surg* 2015; 39:88-103.
- Heidari SM, Loghmani P. Assessment of the effects of ketamine-fentanyl combination versus propofol-

- remifentanil combination for sedation during endoscopic retrograde cholangiopancreatography. *J Res Med Sci* 2014; 19:860-6.
12. de Belder MA, Leech G, Camm AJ. Transesophageal echocardiography in unsedated outpatients: technique and patient tolerance. *J Am Soc Echocardiogr* 1989; 2:375-9.
 13. Sutaria N, Northridge D, Denvir M. A survey of sedation and monitoring practices during transoesophageal echocardiography in the UK: are recommended guidelines being followed? *Heart* 2000; 84:19.
 14. Eren G, Dogan Y, Demir G, Tulubas E, Hergunsel O, Tekdos Y, Dogan M, Bilgi D, Abut Y. Hypnosis for sedation in transesophageal echocardiography: a comparison with midazolam. *Ann Saudi Med* 2015; 35:58-63.
 15. Maeda S, Miyawaki T, Higuchi H, Shimada M. Effect of flumazenil on disturbance of equilibrium function induced by midazolam. *Anesth Prog* 2008; 55:73-7.
 16. Pratila MG, Fischer ME, Alagesa R. Propofol versus midazolam for monitored sedation, a comparison of intraoperative and recovery parameters. *J Clin Anesth* 1993; 5:268-4.
 17. Mchardy FE, Fortier J, Chung F, Krishnathas A, Marshall SI. A Comparison of midazolam, alfentanil and propofol for sedation in outpatient intraocular surgery. *Can J Anaesth* 2000; 47: 211-4.
 18. Smith I, Monk TG, White PF, Ding Y. Propofol infusion during regional anaesthesia, sedative, amnesic and anxiolytic properties. *Anesth Analg* 1994; 79:313-9.
 19. Triantafillidis JK, Merikas E, Dimitrios N, Papalois AE. Sedation in gastrointestinal endoscopy: Current issues. *World J Gastroenterol* 2013; 28; 19:463-81.
 20. Janssen. Products, Rapifen. <https://www.janssen.com.au>. (10 May 2015)
 21. José GM, Silva CE, Ferreira LD, Novaes YP, Monaco CG, Gil MA, Linhares RR, Rodrigues MS, Moraes AS, Ortiz J. Effective dose of sedation in transesophageal echocardiography: relation to age, body surface area and left ventricle function. *Arq Bras Cardiol* 2009; 93: 576-81, 623-9.
 22. Horn E, Nesbit SA. Pharmacology and pharmacokinetics of sedatives and analgesics. *Gastrointest Endosc Clin N Am* 2004; 14:247.
 23. Bahn EL, Holt KR. Procedural sedation and analgesia: a review and new concepts. *Emerg Med Clin North Am* 2005; 23:503.
 24. Vinik HR, Bradley EL Jr, Kissin I. Midazolam-alfentanil synergism for anesthetic induction in patients. *Anesth Analg* 1989; 69:213-7.
 25. Morgan GE, Mikhail MS, Murray MJ, Eds. *Nonvolatile Anesthetic Agents*. In: *Clinical Anesthesiology*. 3rd ed. New York: Lange Medical Books/MC Graw-Hill Medical Publishing Division, 2002.
 26. Drugs. Propofol-Lipuro 1 % (10 mg/ml) <http://www.drugs.com> (11 June 2015)
 27. Data Farm. Emc. Midazolam Injection BP 5 mg/ml solution for injection or infusion Summary of Product Characteristics <http://www.medicines.org.uk/emc/medicine/26596> (25 June 2015)
 28. Maltepe F, Kocaayan E, Ugurlu BS, Akdeniz B, Guneri S. Comparison of remifentanil and fentanyl in anaesthesia for elective cardioversion. *Anaesth Intensive Care* 2006; 34:353-7.
 29. Clarkson K, Power CK, O'connell F, Pathmakanthan S, Burke CM. A comparative evaluation of propofol and midazolam as sedative agents in fiberoptic bronchoscopy. *Chest* 1993; 104:1029-31.