

Stereological analysis of terminal villi, intervillous space and fibrinoid of adolescent placentas and birth weight of newborns

Sergije Marković¹, Anis Cerovac^{2,3}, Suad Kunosić⁴, Suada Ramić¹, Emir Bećirović⁵

¹Department of Histology and Embryology, School of Medicine, University of Tuzla, Tuzla, ²Department of Gynaecology and Obstetrics, General Hospital Tešanj, Tešanj, ³Department of Anatomy, School of Medicine, University of Tuzla, Tuzla, ⁴Department of Physics, School of Natural Sciences and Mathematics, University of Tuzla, Tuzla, ⁵Clinic for Internal Diseases, University Clinical Centre Tuzla, Tuzla, Bosnia and Herzegovina

ABSTRACT

Aim To determine stereological structural parameters of the parenchymal part of the placenta, placental weight and volume of adolescent pregnant women and their correlation with newborns' birth weight.

Methods This prospective study was conducted on a total of 60 human placentas of term pregnancy, divided into two groups according to the age of pregnant women. Experimental group consisted of 30 placentas of pregnant women aged 13-19 years. Control group consisted of 30 placentas of pregnant women aged 20-35 years. Stereological analysis was performed.

Results Volumetric density of terminal villi of adolescent placentas was significantly higher than the one of control group ($p < 0.0001$). The volumetric density of fibrinoid of adolescent placentas was significantly lower than of the control group ($p < 0.0001$). Total volume of terminal villi of adolescent placentas was significantly higher than of the control group ($p < 0.0001$). The total volume of fibrinoid of adolescent placentas was significantly lower than of the control group ($p < 0.0001$). Newborns of adolescent pregnancies had in average lower birth weight of 439.01 g compared to the newborns of the control group ($p < 0.00001$).

Conclusion Adolescent pregnancy affects placental structure, weight and volume. Newborns of adolescent pregnancy have optimal body weight.

Key words: adolescent pregnancy, histological techniques, maternal-fetal exchange

Corresponding author:

Anis Cerovac
General Hospital Tešanj
Braće Pabrić 17, 74260 Tešanj,
Bosnia and Herzegovina
Phone: +387 32 650 662;
Fax: +387 32 650 605;
E-mail: a.cerovac@hotmail.com
Sergije Marković ORCID ID: <https://orcid.org/0000-0002-6304-214X>

Original submission:

25 June 2019;

Revised submission:

13 August 2019;

Accepted:

22 August 2019.

doi: 10.17392/1055-20

INTRODUCTION

Adolescence is a dynamic lifespan in which an individual passes from childhood to a full maturity period, a period of rapid growth and development in which progressive anatomical, physiological and mental changes occur. According to modern concepts, adolescence is considered a period of 10 to 19 years of age, and the optimal age for pregnancy and birth is from the age of 20 to 29 (1). Problems of pregnancy and childbirth at this age require a specific approach, because complications during pregnancy and childbirth are the leading cause of death for 15 to 19 year-old girls globally (2). Pregnancy in the adolescent age is associated with an increased risk of adverse outcome of pregnancy like premature birth, low birth weight of the newborn, preterm premature rupture of membranes, premature rupture of membranes and a high rate of morbidity and mortality in the first year of life (2-6).

Despite socioeconomic progress, because the global population of adolescents continues to grow, projections indicate the number of adolescent pregnancies will increase globally by 2030 (7). The annual number of adolescent births amounts to 18.5 million, which is 14% of the total number of deliveries, and 95% of this number belongs to developing countries, which includes Bosnia and Herzegovina (B&H) (1,8).

Mechanisms involved in mediating the effects of the adolescent age on fetal growth and development remain insufficiently known, but are thought to be related primarily to the placenta (9). Research dedicated to the histological and especially the stereological analysis of the placenta in adolescent pregnancy and its impact on human pregnancy are very scarce. The results suggest an increase in placental efficiency, or the ability of compensatory mechanisms to support fetal growth per gram of placenta. This points to the fact that the adolescent placenta promotes fetal growth and development by increasing their functional efficacy, but at the same time there are changes in the placental weight and structure (9-11).

Numerous studies analysed the parameters of terminal villi, intervillous space and fibrinoid, but not the one of the placenta of adolescent pregnant women (12-16). Despite of the great global significance of the course and outcome of adolescent pregnancy in B&H there were no such studies.

The aim of the study was to determine the stereological structural parameters of the parenchymal part of the placenta (volumetric density and total volume of terminal villi, intervillous space and fibrinoid), adolescent placental weight and volume and their correlation with newborns' birth weight.

PATIENTS AND METHODS

Patients and study design

The study of the morphological structure of placenta was performed at the Department of Histology and Embryology at the School of Medicine, University of Tuzla. The study was conducted on a total of 60 human placentas of term pregnancy, divided into two groups according to the age of pregnant women. The first group consisted of 30 placenta of pregnant women aged 13-19 (experimental group). The second group consisted of 30 placenta of pregnant women aged 20-35 (control group).

A total of 300 newborns were divided into two groups. The first group consisted of 150 newborns of mothers aged 13-19. The second group consisted of 150 newborns of mothers aged 20-35.

The survey was approved by the Ethics Committee of the University Clinical Center Tuzla.

Methods

From each examined placenta, the amniotic membranes and umbilical cord were firstly removed. The weight of the placenta was determined by weighing on the digital weigh (Mettler-Toledo PB 602-S), and the measured weight being rounded to the nearest 1 gram value. The volume of the placenta was determined indirectly, by measuring the amount of fluid discharged according to the Archimedes principle (17).

For histological processing, tissue samples were taken through the thickness of the entire organ, from the chorionic to the basal plate (parenchymal part). From each placenta five tissue samples were taken (dimension of 1 cm³). The tissue was fixed in a 10% aqueous neutral formalin solution, moulded into paraffin and cut into cuts of 8 μ m thickness. The deparaffinized cuts are coloured by hemalaun and eosin (HE).

The compiled hierarchical model of the placenta contained a detailed parenchymal part of the organ that was the subject of quantitative analysis.

Photographing histological preparations was done at the Department of Pathology, Polyclinic for Laboratory Diagnostics, UCC Tuzla. For this purpose, the research microscope (Olympus BX 51) with an integrated digital camera (Olympus DP 70) was used. On the same microscope, calibration was performed using digital imaging processing software using application software (Olympus DP-BSW Ver. 02.01). Analysis of histological compositions was done on 10x magnification.

Computer assisted morphological analysis of images of histological preparations using stereological methods was performed. For the stereological analysis, the reference area was the parenchymal part of the placenta: terminal villi, intervillous space and fibrinoid.

The size of the sample, or the required number of stereological measurements for each of the investigated variables in both groups of pregnant women was determined by the De Hoff procedure (17).

Stereological analysis was carried out by the multipurpose test system using a 10x lens. The quantitative analysis included the relative and total variables of the relevant structures.

Relative stereological variables represent the fraction of the tested structure in the volume unit. Volumetric density (V_v) is a relative stereological variable that indicates the volume of the investigated structure in the organ's volume unit (mm^3).

The volumetric density of terminal villi (V_{vtv}), volumetric density of the intervillous space (V_{vivs}) and volumetric density of the fibrinoid (V_{vf}) of adolescent placentas and the placenta of the control group were determined.

Absolute stereological variables represent the proportion of the examined structure in the volume of the entire organ. Absolute variables were calculated by numerical results of relative stereological variables and absolute organ volume. Certain absolute volume placenta allows a calculation of the total volume indirectly.

The total volume (V) denotes the total volume of the investigated structural components within the entire organ's volume (cm^3). Total volume of terminal villi (V_{tv}), total volume of intervillous space (V_{ivs}) and total volume of fibrinoid (V_f) of adolescent placentas and control group were determined.

The newborns' body weight was measured immediately after birth with the mechanical weight,

where the weight was rounded to the nearest 10 grams. All planned measurements were made according to the provisions of the International Biological Program, anthropological methods and standardized instruments (18).

Statistical analysis

The t-test (statistical comparison test), the χ^2 test (frequency comparison test), and the z-test (proportional test) were used. Statistically significant difference was set to less than 5%.

RESULTS

The examined adolescent placental weight ranged from 359 to 640 g (average of 480.3 ± 84.606 g). The placental weight of control group ranged from 504 to 685 g (average of 575.1 ± 47.343 g) ($p < 0.0001$).

Adolescent placental volume was in the range of $320\text{--}655 \text{ cm}^3$ (average 481.2 ± 86.277), and placental volume in the control group $490\text{--}670 \text{ cm}^3$ (average 563.066 ± 48.312) ($p < 0.0001$).

The volumetric density of the terminal villi of adolescent (V_{vtva}) and control group (V_{vtvc}) placentas was in the range of $0.58\text{--}0.738 \text{ mm}^3$ and 0.342 to 0.542 mm^3 , respectively (Figure 1).

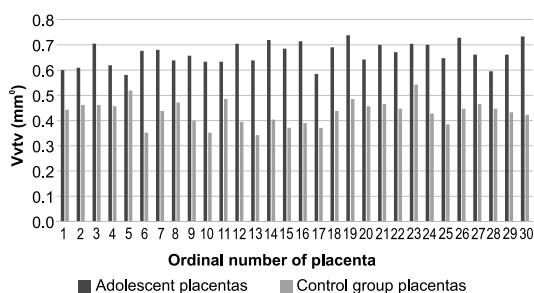


Figure 1. Volumetric density of terminal villi (V_{vtv}) of adolescent and control group placentas

The average V_{vtva} was significantly higher than V_{vtvc} , $0.665 \pm 0.0455 \text{ mm}^3$ and $0.433 \pm 0.0486 \text{ mm}^3$, respectively ($p < 0.0001$).

The volumetric density of intervillous space of adolescent placentas (V_{vivsa}) women ranged from 0.214 to 0.395 mm^3 , and 0.4 to 0.604 mm^3 of the placentas of the control group (V_{vivsc}). The average value of V_{vivsa} and V_{vivsc} was $0.297 \pm 0.045 \text{ mm}^3$ and $0.497 \pm 0.052 \text{ mm}^3$, respectively ($p < 0.0001$).

The volumetric density of fibrinoid of adolescent placentas (V_{vfa}) ranged from 0 to 0.076 mm^3

and the fibrinoid placenta of control group (Vvfc) from 0.028 to 0.08 mm^o (Figure 2).

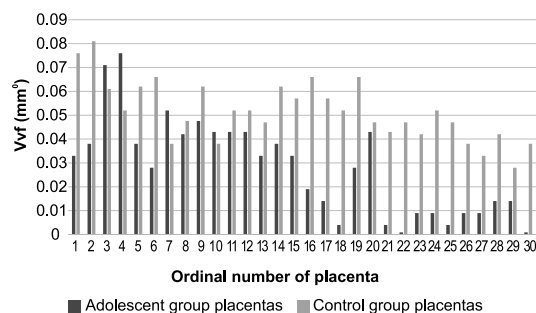


Figure 2. Volumetric density of fibrinoid (Vvf) of adolescent and control group placentas

The average of Vvfa was significantly lower than Vvfc, 0.028±0. mm^o and 0.052±0.012 mm^o, respectively (p <0.0001).

The total volume of terminal villi of adolescent placentas (Vtva) ranged from 219.428 to 417.952 cm³, and in the placenta of control group (Vtvc) it ranged from 173.485 to 325.428 cm³ (Figure 3).

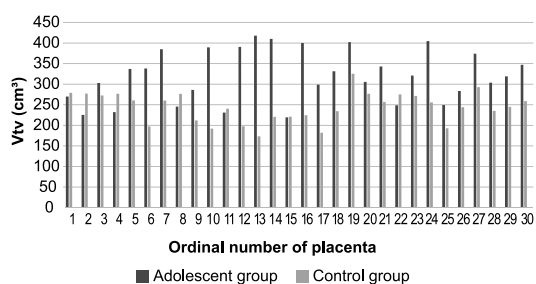


Figure 3. Total volume of terminal villi (Vtv) of the adolescent and control group placentas

The average value of the Vtva was significantly higher than Vtvc, 320.367 ± 62.533 cm³ and 244.223 ± 36.764 cm³, respectively (p <0.0001).

The total volume of the intervillous space of adolescent placentas (Vivsa) ranged from 89.904 to 215.428 cm³, and in the placenta of the control group (Vivsc) ranged from 200.8 to 325.833 cm³ (Figure 4).

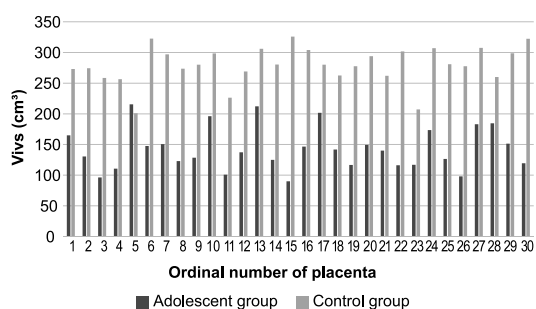


Figure 4. Values of the total volume of intervillous space (Vivs) of the adolescent and control group placentas

The average value of the Vivsa was 143.138±34.797 cm³, and Vivsc 279.496 ± 30.438 cm³ (p<0.0001).

The total volume of fibrinoid of adolescent placentas (Vfa) ranged from 0 to 30.714 cm³, and in the placenta of the of the control group (Vfc) it ranged from 16.142 to 48.571 cm³. The average Vfa was significantly lower than the Vfc, 13.498 ± 9.435 cm³ and 29.399±8.131 cm³, respectively (p<0.0001).

The average body weight of newborns of adolescent pregnancies was 3012.66 ± 507.93 g, in the control group it was 3451.67±477.5 g. Newborns from adolescent pregnancies have in average lower birth weight for 439.01 g compared to newborns of the control group (p<0.00001).

DISCUSSION

This research was done with the aim of establishing the morphometric structural parameters of the parenchymal part of the placenta in adolescent pregnancy and to determine the influence of the adolescent age on the course of pregnancy, intrauterine growth and the condition of the newborn at birth.

The results of our study showed adolescent placentas were on average 94.8 g lower weight comparing to control group, but placental weights in both groups were within the optimum value, as other studies showed as well (9,11,19). Adolescent placental volume of 81.86 cm³ was (significantly) lower in comparison with the control group although obtained placental values of both examined groups were within the optimal values, which correlates with a study of Balihallimath et al (11). It is important to point out that the weight and volume of the placenta are in direct and significant correlation with the weight of the newborn (9,11,19,20), as our results showed.

The conducted morphometric studies (11,21) have shown a significant correlation between weight, volume, thickness and total placental surface area with the weight of the newborn and gestation length. Studies on the weight and volume of adolescent pregnant placenta reveal a positive correlation with preeclampsia, lower Apgar scores and fetal distress, pointing out that the decrease in weight and volume of the placenta is associated with an adverse pregnancy outcome (19,20). A significant decrease in volume and placental weight was also demonstrated in the study

of adolescent pregnant women with preterm delivery (21), and in other studies as well (10).

A (significant) difference of 23.2% of the average V_{vtv} , of 20% of the average V_{vivs} and 2.38% of the average V_{vf} between adolescent and the control group was found in our study. Much better and more important indicators of total growth and structural adjustment of the placenta are absolute values of stereological variables, as opposed to relative variables that are indirect indicators of these changes (22). A complete understanding of pathological structural changes requires a complete and joint observation of all relative and total stereological variables in one place (22). Growth and development of terminal villi pass through significant structural changes in complicated pregnancies such as adolescent pregnancy, leading to changes in the intervillous space (23,24).

Our results of a stereological analysis for the relative and total variables of the parenchymal part of the placenta deduce that the volumetric density and total volume of terminal villi of adolescent pregnant women placentas were significantly higher in relation to the same variables in the control group of pregnant women. It was a matter of extreme expansion of terminal villi, which by their spiralling occupied 66.5% of the parenchymal part of the placenta in an attempt to provide optimum maternal fetal exchange by increasing volumetric values (23). The difference in the V_{tva} in adolescent pregnancies compared to the placenta of the control group of 76.144 cm³ was found in our study, suggesting compensatory placenta response to the prevailing hypoxia; but the response was pronounced by a branching that did not correspond to a rise in normal pregnancy as shown by Burton et al. study (12).

Thanks to a significant increase in the volume parameters of terminal villi of adolescent pregnant women placentas (20% in our study), there has been a compensatory decrease in volume density and total volume of the intervillous space of placenta adolescent pregnancies, which could lead to a reduction in the total amount of maternal blood in that area, and thus in another way endanger the fetus (14).

Fibrin deposits are the result of cascading blood coagulation reactions, and its role is to fill the cracks formed on the surface of syncytiotropho-

blasts. It can be found in each placenta and is not a pathological finding, except when it is found in a larger quantity (14). In the results of our study, a significantly lower total volume of fibrinoid in the adolescent placentas could be explained by a significantly higher preterm birth in adolescent pregnancies with an average duration of pregnancy of 35.428 gestational weeks, suggesting that there was no time for developing this degenerative process until the end of pregnancy on a larger scale.

Placenta is a vital organ responsible for maintaining pregnancy and promoting normal fetal development and health. The outcome of pregnancy and the condition of the newborn are under the negative influence of structural pathological changes in the placenta (23,24). Different causes, including adolescent pregnancies, may lead to a decrease in placental weight and uteroplacental insufficiency and consequent delay in fetal growth (11).

Postnatal assessment of intrauterine growth of neonates is based on standards specific to each environment (25). In our study for estimating intrauterine growth of newborns we used percentile growth curves for the Tuzla Canton (18). The direct and distant prognosis of each newborn depends on three basic characteristics, body mass, gestational maturity and functional maturity (18,25,26). Interventions and actions in terms of reducing the total number of adolescent pregnancies will have little effect on the adverse outcome of pregnancy if social, health, and socio-economic factors are not included (8,26).

In conclusion, the outcome of adolescent pregnancy for newborn birth weight was relatively favourable, but at the same time, the compensatory mechanisms of adolescent placenta were exhausted, which reflected on the weight and volume of these placenta as well as on stereological variables. For this reason future research is necessary for better understanding of the morphological correlates of the efficiency of the parenchymal part of the adolescent placenta and their influence on fetal development.

FUNDING

No specific funding was received for this study.

TRANSPARENCY DECLARATION

Conflict of interest: None to declare.

REFERENCE

1. World Health Organization. Adolescent pregnancy. Key facts. <http://www.who.int/mediacentre/factsheets/fs364/en/> (18 March 2019)
2. World Health Organization. Deaths by cause, age, sex, by country and by region, 2000-2015. https://www.who.int/healthinfo/global_burden_disease/estimates_regional_2000_2015/en/ (18 March 2019)
3. Socolov DG, Iorga M, Carauleanu A, Ilea C, Bli-daru I, Boiculescu L, Socolov RV. Pregnancy during adolescence and associated risks: An 8-year hospital-based cohort study (2007-2014) in Romania, the country with the highest rate of teenage pregnancy in Europe. *BioMed Res Int* 2017; 2017:9205016.
4. Sedgh G, Finer LB, Bankole M, Eilers A, Singh S. Adolescent pregnancy, birth, and abortion rates across countries: levels and recent trends. *J Adolesc Health* 2015; 56:223-30.
5. Moreira AIM, Sousa PRM, Sarno F. Low birth weight and its associated factors. *Einstein (Sao Paulo)* 2018; 16: eAO4251.
6. Marković S, Bogdanović G, Cerovac A. Premature and preterm premature rupture of membranes in adolescent compared to adult pregnancy. *Med Glas (Zenica)* 2020; 17:18-22.
7. Every Woman Every Child. The global strategy for women's, children's and adolescents' health (2016-2030) <http://www.everywomaneverychild.org/global-strategy/> (18 March 2019)
8. Mulu Kassa G, Arowojolu AO, Odukogbe AA, Yal-ew AW. Prevalence and determinants of adolescent pregnancy in Africa: a systematic review and meta-analysis. *Reprod Health* 2018; 15:195.
9. Hayward CE, Greenwood SL, Sibley CP, Baker PN, Jones RL. Effect of young maternal age and skeletal growth on placental growth and development. *Placenta* 2011; 32: 990-8.
10. Salavati N, Smies M, Ganzevoort W, Charles AK, Erwich JJ, Plosch T, Gordijn SJ. The possible role of placental morphometry in the detection of fetal growth restriction. *Front Physiol* 2019; 9:1884.
11. Balihallimath RL, Shirol VS, Gan AM, Tyagi NK, Bandankar MR. Placental morphometry determines the birth weight. *J Clin and Diagn Res* 2013; 7:2428-31.
12. Burton GJ, Reshetnikova OS, Milovanov AP, Teleshova OV. Stereological evaluation of vascular adaptations in human placental villi to differing forms of hypoxic stress. *Placenta* 1996; 17:49-55.
13. Dairi AS, Elbarrany WG, Moulana AAR, Himayda ASA, Hakeem IM. Quantitative morphometric study of the chorionic villi in hypertensive mothers. *Egyptian J Hospital Med* 2017; 69:2315-22.
14. Mayhew TM, Bowles C, Orme G. A stereological method for testing whether or not there is random deposition of perivillous fibrin-type fibrinoid at the villous surface: description and pilot applications to term placentae. *Placenta* 2000; 21:684-92.
15. Haeussner E, Schmitz C, Frank HG, Edler von Koch F. Novel 3D light microscopic analysis of IUGR placentas points to a morphological correlate of compensated ischemic placental disease in humans. *Sci Rep* 2016; 6:24004.
16. Lahti-Pulkkinen M, Cudmore MJ, Haeussner E, Schmitz C, Pesonen AK, Hamalainen E, Villa PM, Mehtälä S, Kajantie E, Laivuori H, Reynolds RM, Frank HG, Räikkönen K. Placental morphology is associated with maternal depressive symptoms during pregnancy and Toddler psychiatric problems. *Sci Rep* 2018; 8:791-803.
17. Kališnik M. Temelji stereologije. Ljubljana: Društvo za stereologijo in kvantitativno analizo slike: DSKAS, 2002.
18. Muratović S, Skokić F, Fatušić Z, Nevačinović E. Birth weight, length and head circumference percentiles by gestational age and gender of term neonates in Tuzla canton. *Acta Medica Saliniana* 2011; 40:45-51.
19. Balihallimath RL, Shirol VS, Tyagi NK, Gan AM, Desai SP. Maternal determinants of placental morphometry and birth weight. *Int J Med Sci Public Health* 2015; 4: 508-15.
20. Ashgarnia M, Poorghorban M, Atrkar-Roshan Z. Placental weight and its association with maternal and neonatal characteristics. *Acta Med Iran* 2008; 46:467-72.
21. Zaidi T, Arshad M, Vasenwala SM, Faruqi NA, Khan AA, Khan S. Histomorphometry of preterm and term human placentas. *Int J Morphol* 2013; 31:409-13.
22. Mayhew TM. Stereology and the placenta: where's the point? – a review. *Placenta* 2006; 27:17-25.
23. Burton GJ, Fowden A. The placenta; a multifaceted, transient organ. *Philos-Trans R Soc Lond B Biol Sci* 2015; 370:20140066.
24. Burton GJ, Jauniaux E. What is the placenta? *Am J Obstet Gynecol* 2015; 213:6-8
25. Nevačinović E, Cerovac A, Bogdanović G, Grgić G. Perinatal characteristics and prevalence of low birth weight infants in the Federation of Bosnia and Herzegovina: prospective multicentric study. *Med Glas (Zenica)* 2019; 16:92-97.
26. Gausman J, Langer A, Austin SB, Subramanian SV. Contextual variation in early adolescent childbearing: A multilevel study from 33,822 communities in 44 low- and middle-income countries. *J Adolesc Health* 2019; 64:737-45.