

Possibilities of differentiation of solitary focal liver lesions by computed tomography perfusion

Irmina Sefić Pašić¹, Anes Pašić², Spomenka Kristić¹, Adnan Beganović¹, Aladin Čarovac¹, Amra Džananović¹, Lidija Lincender³, Sandra Vegar Zubović¹

¹Radiology Clinic, ²Oncology Clinic; Clinical Center of Sarajevo University, ³Academy of Sciences and Arts of Bosnia and Herzegovina; Sarajevo, Bosnia and Herzegovina

ABSTRACT

Aim To evaluate possibilities of computed tomography (CT) perfusion in differentiation of solitary focal liver lesions based on their characteristic vascularization through perfusion parameters analysis.

Methods Prospective study was conducted on 50 patients in the period 2009-2012. Patients were divided in two groups: benign and malignant lesions. The following CT perfusion parameters were analyzed: blood flow (BF), blood volume (BV), mean transit time (MTT), capillary permeability surface area product (PS), hepatic arterial fraction (HAF), and impulse residual function (IRF). During the study another perfusion parameter was analyzed: hepatic perfusion index (HPI). All patients were examined on Multidetector 64-slice CT machine (GE) with application of perfusion protocol for liver with i.v. administration of contrast agent.

Results In both groups an increase of vascularization and arterial blood flow was noticed, but there was no significant statistical difference between any of 6 analyzed parameters. Hepatic perfusion index-values were increased in all lesions in comparison with normal liver parenchyma.

Conclusion Computed tomography perfusion in our study did not allow differentiation of benign and malignant liver lesions based on analysis of functional perfusion parameters. Hepatic perfusion index should be investigated in further studies as a parameter for detection of possible presence of micro-metastases in visually homogeneous liver in cases with no lesions found during standard CT protocol

Key words: CT protocol, contrast media, hepatic perfusion index

Corresponding author:

Irmina Sefić Pašić
Radiology Clinic, Clinical Center of
University of Sarajevo
Bolnička 25, 71000 Sarajevo, Bosnia and
Herzegovina
Phone : +387 33 297 731;
Fax : +387 33 297 811;
E-mail : irmina.sefic@gmail.com

Original submission:

22 May 2015;

Revised submission:

06 July 2015;

Accepted:

08 July 2015.

INTRODUCTION

The liver is the most common site of metastases from gastrointestinal tumors (1,2). High blood flow (about 25% of cardiac output), favorable microscopic anatomy (liver sinusoids and gaps in subendothelial basement membrane), and rich biochemical environment favor the rapid growth of metastatic deposits in the liver (1,2). In malignant diseases diagnosis of the extent of the primary tumor and staging of a potential spread of the disease have fundamental importance. Without this information, an appropriate therapy is not possible (1,2). A significant problem for all diagnostic imaging methods in the staging of malignant disease is a relatively high incidence of benign lesions (1,3). For this reason high diagnostic specificity is a major requirement in order to distinguish various benign lesions that may affect the therapeutic decisions in case of misinterpretation (1,3).

In general, detection of metastases with diagnostic methods is based on micro and macrostructure changes that distinguish tumor tissue from normal liver tissue (1,2).

Because many pathological conditions of the liver leading to changes in regional or whole blood flow, perfusion imaging of the liver proved to be a method with high sensitivity and specificity in differentiating of liver lesions (3,4).

Kinkel et al. analyzed in meta-analysis a sensitivity of different diagnostic methods in diagnosing metastasis and showed that in liver tumors over 1 cm (sensitivity 55-90%), or for lesions less than 1 cm sensitivity is much lower (below 50%), and microscopic lesions remain occult (3). Smith et al. pointed that CT perfusion is one of the last achievements in the field of physiological imaging, which can provide new opportunities for the use of imaging as a biomarker (5).

Since it was first described by Miles et al. (6), CT perfusion has been successfully applied in a variety of clinical conditions including assessment of liver cirrhosis (7), characterization of liver tumors (8,9), and evaluation of therapy response in liver diseases (9-11)

The aim of this study was to analyze CT perfusion parameters (blood flow, blood volume, hepatic arterial fraction, mean transit time, capillary permeability surface area product, impulse resi-

dual function) and to determine whether one or more of the six parameters significantly stand out in differentiating pathological lesions to benign and malignant. The purpose of the study was to evaluate the possibility of the application of CT perfusion imaging in the differentiation of focal hepatic lesions based on the perfusion analysis.

PATIENTS AND METHODS

The prospective study included 50 patients in the period 2009-2012 at the Radiology Clinic of Clinical Center of Sarajevo University. All patients were examined on Multidetector 64-slice CT machine (Light Speed VCT) (GE Medical Systems, Milwaukee, WI, USA) with application of CT perfusion protocol for liver with i.v. administration of contrast agent.

Solitary liver characteristics changes and their division into benign and malignant were confirmed by at least two radiological methods (ultrasound, computerized tomography or magnetic resonance) with follow up of focal lesion over a certain period of time, and based on clinical parameters. All patients had previously performed an ultrasound examination of the abdomen with a special focus on the liver to verify solitary focal lesion in liver. Based on the differences in perfusion parameter results, further categorization of tumors or secondary deposits (based on histological diagnosis) into subgroups of solitary liver lesions was made.

Tube voltage 120 kV, power tubes 60mA, exposure time 50 sec, thickness 0.5 cm, and the beam width 4 cm were used as an examination protocol. The amount of contrast agent that is administered was 0.5 mL/kg body weight of the patient at a flow rate 4 mL/sec.

Before administration of contrast material all patients signed a consent for the application, and were informed about adverse reactions.

The study was approved by the Ethics Committee of the Clinical Center of University of Sarajevo and all patients signed informed consents for inclusion in study.

Six perfusion parameters were analyzed (12).

Blood flow (BF) (mL/min/100 g tissue), which was carried out both in arterial and in the portal phase, is the volume of blood flow through blood vessels including large collecting blood vessels, arteries, arterioles, venules, veins and sinuses.

Mean transit time (MTT) is measured in seconds. Blood moves through the blood vessels at different speed so that there is no universally defined time flow of blood from the arterial network in the vein. Distribution of flow time and MMT represent median time of that distribution. Capillary permeability surface area product (PS) (mL/min/100 g tissue) is the flow of the contrast medium through the capillary endothelium in interstitial space. Hepatic arterial fraction (HAF) (%) is the percentage of blood that supplies hepatic arteries in relation to the portal vein in the liver. Impulse residual function (IRF) (mL/min/100 g) is the ratio of arterial and interstitial concentration of the contrast medium.

Functional perfusion parameters were analyzed by Deconvolution (13,14) method and compartmental model (15,16).

The balance between the arterial and portal inputs was expressed by the hepatic perfusion index (HPI), which represents the ratio of arterial blood flow (Fa) and total hepatic flow Ft (Fa + Fp).

Statistical analysis was done by using chi-square test, Student's t-test, analysis of variance (ANOVA), and to determine the degree of mutual dependence (correlation) of certain parameters Spearman's rank correlation coefficient was used. Testing the sensitivity of some parameters was carried out by analyzing the area under the ROC curve (receiver operator curve). For statistical analysis of hepatic perfusion index, control group was introduced referring to the values of normal liver parenchyma, and it was compared with the values obtained in pathologic lesions (it only applies on HPI parameter)

RESULTS

A total of 30 women and 20 men was included in the study.

Analysis by gender revealed that women were more frequently represented in the group of benign lesions, 18 (69.2%), than men, eight (30.8%), while in the group with other lesions the same number of men and women was recorded, 25 in each (50%) ($p > 0.05$).

The patients with benign lesions were (on average) slightly older (60.7 ± 9.6 years; range 44-80 yr.) than the patients with other lesions (57.8 ± 13.5 years; range 27-83 years) ($p > 0.05$).

Of the 24 malignancies 10 had histological diagnosis, be it a primary tumor or a secondary deposit.

Analysis of blood flow showed that patients with malignant lesions had a little higher value, but without significant statistical difference ($p > 0.05$), with emphasis that the significant difference was not shown among the subgroups, e.g., metastases vs. metastases with pathohistological diagnosis (phd).

There was no statistically significant difference found in blood volume or arterial or in the portal series ($p > 0.05$).

Values for the MTT, HAF, SF and IRF (including both arterial and portal phase), showed no statistically significant differences.

Analysis of the parameters of aortic blood flow showed that the highest sensitivity in differentiating between benign and malignant lesions has shown surface permeability (53.8%), and the lowest one hepatic arterial fraction (42.9%) with no statistical differences (Figure 1).

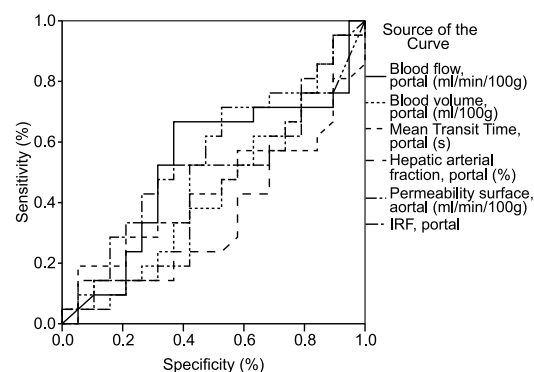


Figure 1. Specificity and sensitivity of aortic blood flow in both groups of patients (benign and malignant lesions)

Analysis of the parameters of the portal system showed that the highest sensitivity in differentiating between benign and malignant lesions has shown permeability surface (56.8%), and the lowest one volume hepatic blood volume (42.3%) without statistically significant difference between individually observed parameters (Figure 2).

A statistically significant correlation between the groups, e.g., benign and malignant lesions, and six perfusion parameters tested in both arterial and portal phase was not observed in any case.

The highest correlation between perfusion parameters in differentiating benign from malignant lesions showed blood flow in the aortic

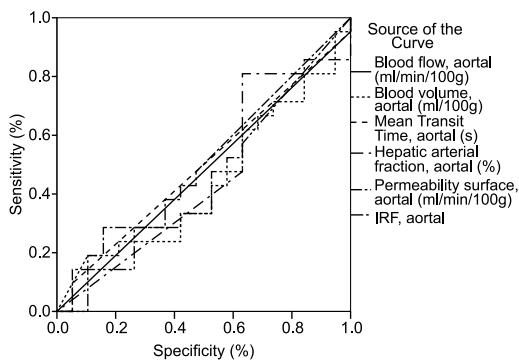


Figure 2. Sensitivity and specificity of portal blood flow in both groups of patients (benign and malignant lesions)

blood stream ($R_o = 0.137$) followed by hepatic arterial fraction aortic ($R_o = 0.133$) and blood volume – portal ($R_o = 0.133$), then the permeability surface - portal ($R_o = -0.118$), and hepatic arterial fraction – portal ($R_o = 0.108$) followed by other parameters with less than 10% effect on the differentiation of groups (Table 1). The patients with benign lesions had an average HPI slightly higher (55.7 ± 5.1 ; range 50 to 65.5%) than the patients with other lesions (54.6 ± 3.95 ; range 50 to 66.9 %) with no statistically significant differences ($p > 0.05$).

Table 1. Correlations between groups (benign and malignant lesions) and between each of six perfusion parameters

	Correlation coefficient	
	Benign	Malignant
Blood flow (mL/min/100g) - aortal	0.137	0.342
Blood volume (mL/100g) - aortal	0.011	0.939
Mean transit time (sec) - aortal	0.009	0.951
Hepatic arterial fraction - aortal	0.133	0.357
Permeability surface (mL/min/100g) - aortal	-0.073	0.613
Impulse residual function - aortal	0.082	0.573
Blood flow (mL/min/100g) - portal	0.069	0.632
Blood volume (mL/100g) - portal	0.133	0.357
Mean transit time (sec) - portal	0.019	0.894
Hepatic arterial fraction - portal	0.108	0.455
Permeability surface (mL/min/100g) - portal	-0.118	0.415
Impulse residual function - portal	0.05	0.73

The analysis of HPI showed that sensitivity in differentiating benign lesions from other lesions on the basis of this parameter was 8.4% (Figure 3). A comparison of HPI values in focal liver lesions (benign and malignant) with values of normal liver parenchyma has shown statistically significant difference ($p < 0.05$).

The Spearman’s correlation coefficient indicated that with 82.6% certainty the patients with normal values of hepatic perfusion index in liver parenchyma belonged to the control group and

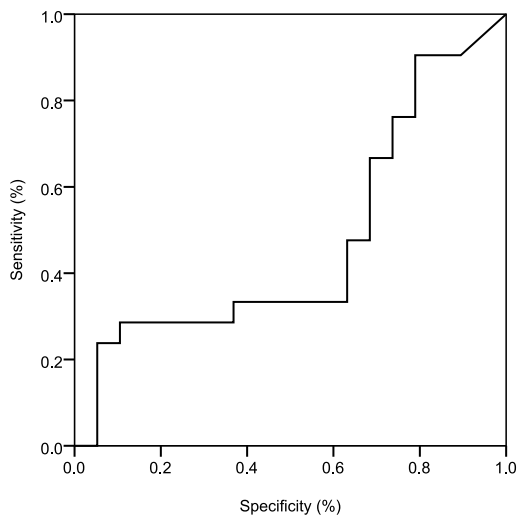


Figure 3. Sensitivity and specificity of hepatic perfusion index in hypervascular benign lesions

patients with elevated values belonged to the group with benign or malignant lesions.

DISCUSSION

Quantitative measurement of perfusion CT provides information about the processes that affect the structure and function of the tissue. The concept is based on monitoring the first pass bolus of iodinated contrast agents through blood vessels of a certain tissue. This method allows non-invasive monitoring of changes in malignant process, as well as the results of treatment, and considering that CT perfusion provides data on angiogenesis activity may be useful in monitoring the treatment of angiogenesis inhibitors (17).

In patients with known metastatic disease, an elevated arterial perfusion was noticed with values of about 40-50 mL/min/100 mL m versus 17-19 mL/min/100 mL in the healthy control group (values of normal liver parenchyma). Therefore, HPI was significantly higher in patients with metastatic disease, which was proven by Miles et al. (18-20) and Blomley et al. (21).

In our study, the value of HPI in solitary lesions ranged between 50 and 60%, with no significant differences by type of lesion. Also, benign and malignant lesions had the same value of HPI, considering that the benign lesions in this study represent only hemangiomas, which are basically hypervascular lesions. The results of this study indicated that CT perfusion is not the method of choice in the diagnosis of hemangioma, be-

cause they can be diagnosed with the standard protocol that is used during the CT examination. Certainly, HPI parameter can be used to prove the presence of micrometastases in visually homogeneous liver, where a standard way of CT protocols showing no enhancement after contrast administration (4,18). Any increase in the value of HPI favors of the changes with intense vascularization, which comes from the hepatic artery, but without the possibility of characterization of these lesions, so that this parameter remains highly sensitive, but not specific enough (4,18). In rats, Cuenod et al. used deconvolution technique and found colon cancer metastasis in the liver with increased HPI and reduction in hepatic perfusion due to the reduction of portal perfusion. They also observed decrease in distribution volume and increase in MTT (18).

Further sub-analyses of the two groups (benign and malignant lesions) in the present study revealed that patients with histologically verified malignant lesions had no significant differences in perfusion parameters values compared to patients with malignant change without histopathologic verification.

Modification of hepatic perfusion can be found not only in patients with visible liver metastases, but also in patients with occult metastases that develop liver metastases at follow-up examinations (21). Leggett et al. described changes in hepatic perfusion in patients with visible metastases, reduction of portal perfusion and increased HPI in patients with occult metastases in whom the disease is detected at follow-up (4). Routine CT and MRI are insensitive to discover occult and early stage hepatic micrometastasis of tumors (22). Hemangioma is one of the common benign liver tumors; however, it is sometimes misdiagnosed as a malignant tumor (23). Although there is no apparent abnormality in morphology, computed tomography perfusion can display changes in hemodynamics through its functional imaging (24). An increase in both HAP and HPI can declare the possibility of liver micrometastasis (15). Cuenod et al. (13-17) used the deconvolution method to study liver hemodynamic changes caused by occult hepatic micrometastasis in rats and found micrometastases in normal liver leading to 34% decrease in portal blood flow and 25% increase in MTT, suggesting that resistance is increased in sinusoidal capillaries.

Limitation of CT perfusion arises from the large number of parameters that require dual model of hepatic microcirculation. The liver perfusion models, measurements are taken during the first passing of the contrast (25). In cases of the existence of liver nodules or in chronic liver disease, where there is a modification of a sinusoidal permeability and interstitial volume, it is required to have more complex models (26,27). Little attention is devoted to biomarkers resulting from radiological examinations. CT perfusion is one of the recent developments in the field of physiological imaging, which can provide new opportunities for the use of imaging as a biomarker (28). Preliminary evidence suggests that measurement of liver perfusion can be connected with the survival of the patients with visible metastasis and patients with micrometastasis, where conventional CT protocol did not detect changes in liver parenchyma. Many cancer patients undergo CT examinations of the liver, and consequently, recurrent tumors are identified after a primary treatment. For colorectal carcinomas, intensified follow-up in this way is associated with decreased mortality (29) and the American Association of Clinical Oncologists now recommends annual CT examinations of the lungs and abdomen in the first three years after the primary therapy in patients with high risk of recurrent disease (30). CT perfusion could be incorporated into such programs. CT perfusion is especially suitable for the assessment of the response to biological therapy, which affects the tumor blood vessels, giving quantitative information, and more importantly, studies have shown that obtained perfusion parameters correlate with histological measurements of angiogenesis (31-34). The possibility of identifying high risk of liver metastases in common diseases such as colorectal cancer can help with decisions on adjuvant chemotherapy, but also can avoid unnecessary treatment of patients who are at low risk of developing liver metastases (9,34).

Computed tomography is the most common modality for evaluating cancer patients. In our study CT perfusion did not allow differentiation between benign and malignant focal liver lesions. However, it is possible that larger patient population should be studied. CT perfusion can be ea-

sily included as a part of standard CT protocol in order to provide functional information about the solitary change. It is an available method, easy to perform, allows repeated examinations and applicable to all organic systems.

REFERENCES

1. Leen E. The detection of occult liver metastases of colorectal carcinoma. *J Hepatobiliary Pancreat Surg* 1999; 6:7–15.
2. Seto S, Onodera H, Kaido T, Yoshikawa A, Ishigami S, Arii S, Imamura M. Tissue factor expression in human colorectal carcinoma: correlation with hepatic metastasis and impact on prognosis. *Cancer* 2000; 88:295–301.
3. Kinkel K, Lu Y, Both M, Warren RS, Thoeni RF. Detection of hepatic metastases from cancers of the gastrointestinal tract by using noninvasive imaging methods (US, CT, MR imaging, PET): a meta-analysis. *Radiology* 2002; 224:748–56.
4. Miles KA, Hayball MP, Dixon AK. Functional images of hepatic perfusion obtained with dynamic CT. *Radiology* 1993; 188:405–11.
5. Smith JJ, Sorensen AG, Thrall JH. Biomarkers in imaging: realizing radiology's future. *Radiology* 2003; 227:633–8.
6. Miles KA, Hayball M, Dixon AK. Colour perfusion imaging: a new application of computed tomography. *Lancet* 1993; 337:643–5.
7. Ronot M, Asselah T, Paradis V, Michoux N, Dorvillius M, Baron G, Marcellin P, Van Beers BE, Vilgrain V. Liver fibrosis in chronic hepatitis C virus infections: differentiating minimal from intermediate fibrosis with perfusion CT. *Radiology* 2010; 256:135–42.
8. Sahani DV, Holalhere NS, Mueller PR, Zhu AX. Advanced hepatocellular carcinoma: CT perfusion of liver and tumor tissue-initial experience. *Radiology* 2007; 243:736–43.
9. Hayano K, Desai GS, Kambadakone R, Fuentes JM, Tanabe KT, Sahani DV. Quantitative characterization of hepatocellular carcinoma and metastatic liver tumor by CT perfusion. *Cancer Imaging* 2013; 13:512–9.
10. Ippolito D, Capraro C, Casiraghi A, Cestari C, Sironi S. Quantitative assessment of tumour associated neovascularisation in patients with liver cirrhosis and hepatocellular carcinoma: role of dynamic-CT perfusion imaging. *Eur Radiol* 2012; 22:803–11.
11. Jiang T, Kambadakone A, Kuikarni NM, Zhu AX, Sahani DV. Monitoring response to antiangiogenic treatment and predicting outcomes in advanced hepatocellular carcinoma using image biomarkers, CT perfusion, tumor density and tumor size (RECIST). *Invest Radiol* 2012; 47:11–7.
12. Miles KA. Measurement of tissue perfusion by dynamic computed tomography. *Br J Radiol* 1991; 64:409–12.
13. Cuenod C, Leconte I, Siauve N, Resten A, Dromain C, Poulet B, Frouin F, Clément O, Fria G. Early changes in liver perfusion caused by occult metastases in rats: detection with quantitative CT. *Radiology* 2001; 218:556–61.
14. Fournier LS, Cuenod CA, de Bazelaire C, Siauve N, Rosty C, Tran PL. Early modifications of hepatic perfusion measured by functional CT in a rat model of hepatocellular carcinoma using a blood pool contrast agent. *Eur Radiol* 2004; 14:2125–33.
15. Materne R, Van Beers BE, Smith AM, Leconte I, Jarmart J, Dehoux JP, Keyeux A, Horsmans Y. Non-invasive quantification of liver perfusion with dynamic computed tomography and a dual-input one-compartmental model. *Clin Sci (Lond)* 2000; 99:517–25.
16. Van Beers BE, Leconte I, Materne R, Smith AM, Jarmart J, Horsmans Y. Hepatic perfusion parameters in chronic liver disease: dynamic CT measurements correlated with disease severity. *AJR Am J Roentgenol* 2001; 176:667–73.
17. Pandharipande Pari V, Krinsky Glenn A., Rusinek H., Lee Vivian S. Perfusion imaging of the liver: current challenges and future goals. *Radiology* 2005; 234:661–673.
18. Dugdale PE, Miles KA. Hepatic metastases: the value of quantitative assessment of contrast enhancement on computed tomography. *Eur J Radiol* 1999; 30:206–13.
19. Miles KA, Leggett DA, Kelley BB, Hayball MP, Sinnatamby R, Bunce I. In vivo assessment of neovascularization of liver metastases using perfusion CT. *Br J Radiol* 1998; 71:276–81.
20. Miles KA, Kelley BB. Altered perfusion adjacent to hepatic metastases. *Clin Radiol* 1997; 52:162–3.
21. Blomley M, Coulden R, Dawson P. Liver perfusion studied with ultrafast CT. *J Comput Assist Tomogr* 1995; 19:424–33.
22. Kinkel K, Lu Y, Both M, Warren RS, Thoeni RF. Detection of hepatic metastases from cancers of the gastrointestinal tract by using noninvasive imaging methods (US, CT, MR imaging, PET): a meta-analysis. *Radiology* 2002; 224:748–56.
23. Semelka RC, Sofka CM. Hepatic hemangiomas. *Magn Reson Imaging Clin N Am* 1997; 5:241–53.
24. Smith JJ, Sorensen AG, Thrall JH. Biomarkers in imaging: realizing radiology's future. *Radiology* 2003; 227:633–8.
25. Cuenod CA, Leconte I, Siauve N, Frouin F, Dromain C, Clément O, Fria G. Deconvolution technique for measuring tissue perfusion by dynamic CT: application to normal and metastatic liver. *Acad Radiol* 2002; 9:S205–11.
26. Kapanen MK, Halavaara JT, Hakkinen AM. Assessment of vascular physiology of tumorous livers: comparison of two different methods. *Acad Radiol* 2003; 10:1021–9.
27. Kapanen MK, Halavaara JT, Hakkinen AM. Open four-compartment model in the measurement of liver perfusion. *Acad Radiol* 2005; 12:1542–50.

FUNDING

No specific funding was received for this study

TRANSPARENCY DECLARATION

Competing interests : None to declare

28. Smith JJ, Sorensen AG, Thrall JH. Biomarkers in imaging: realizing radiology's future. *Radiology* 2003; 227:633–8.
29. Jeffrey GM, Hickey BE, Hider P. Follow-up strategies for patients treated for non-metastatic colorectal cancer (Cochrane Review). In: *The Cochrane Library*. Issue 2. Oxford: Update Software, 2003.
30. Desch CE, Benson AB 3rd, Somerfield MR, Flynn PJ, Krause C, Loprinzi CL, Minsky BD, Pfister DG, Virgo KS, Petrelli NJ. Colorectal cancer surveillance: 2005 update of an American Society of Clinical Oncology practice guideline. *J Clin Oncol* 2005; 23:8512–19.
31. Hayashi K, Tozaki M, Sugisaki M, Yoshida N, Fukuda K, Tanabe H. Dynamic multislice helical CT of ameloblastoma and odontogenic keratocyst: correlation between contrast enhancement and angiogenesis. *J Comput Assist Tomogr* 2002; 26:922–6.
32. Jinzaki M, Tanimoto A, Mukai M, Ikeda E, Kobayashi S, Yuasa Y, Narimatsu Y, Murai M. Double-phase helical CT of small renal parenchymal neoplasms: correlation with pathologic findings and tumor angiogenesis. *J Comput Assist Tomogr* 2000; 24:835–42.
33. Wang ZQ, Li JS, Lu GM et al. Correlation of CT enhancement, tumor angiogenesis and pathologic grading of pancreatic carcinoma. *World J Gastroenterol* 2003; 9:2100–4.
34. Zhong L, Wang WJ, Xu JR. Clinical application of hepatic CT perfusion. *World J Gastroenterol* 2009; 15: 907–11.

Mogućnost diferencijacije solitarnih fokalnih jetrenih lezija putem perfuzije kompjuteriziranom tomografijom

Irmina Sefić Pašić¹, Anes Pašić², Spomenka Kristić¹, Adnan Beganović¹, Aladin Čarovac¹, Amra Džananović¹, Lidija Lincender³, Sandra Vegar Zubović¹

¹Klinika za radiologiju; Univerzitetski klinički centar Sarajevo, ²Klinika za onkologiju; Univerzitetski klinički centar Sarajevo, ³Akademija nauka i umjetnosti Bosne i Hercegovine; Sarajevo, Bosna i Hercegovina

SAŽETAK

Cilj Utvrditi mogućnosti perfuzije kompjuteriziranom tomografijom u diferencijaciji solitarnih fokalnih lezija jetre na osnovu njihove karakteristične vaskularizacije, a putem analize parametara perfuzije.

Metode Prospektivna studija je obuhvatila 50 pacijenata koji su pregledani u periodu od 2009. do 2012. godine. Pacijenti su podijeljeni u dvije grupe, odnosno u grupu s benignim i malignim lezijama jetre. Analizirano je šest parametara CT perfuzije: protok krvi (BF), volumen krvi (BV), produkt kapilarne površne permeabilnosti (PS), jetrena arterijska frakcija (HAF) i impulsna rezidualna frakcija (IRF). Tokom studije analiziran je dodatni parametar perfuzije, jetreni perfuzioni indeks (HPI). Svi pacijenti pregledani su na multidetektorskom 64-slojnom CT aparatu (GE) uz primjenu protokola za perfuziju jetre i uz i.v. aplikaciju kontrastnog sredstva.

Rezultati Kod obje grupe pacijenata dokazana je povećana vaskularizacija i povišen arterijski protok, ali nije utvrđena signifikantna razlika između analiziranih šest parametara perfuzije. Vrijednosti HPI-a bile su povišene kod svih lezija u komparaciji s normalnim jetrenim parenhimom.

Zaključak Perfuzija kompjuteriziranom tomografijom u našoj studiji nije omogućila diferencijaciju benignih i malignih lezija na osnovu analize funkcionalnih parametara perfuzije. Jetreni perfuzioni indeks trebao bi se u budućim studijama ispitati kao parametar za otkrivanje potencijalnog prisustva mikrometastaza u vizuelno homogenoj jetri u slučajevima kada se lezije nisu otkrile tokom pregleda standardnim CT-protokolom.

Ključne riječi: CT-protokol, kontrastno sredstvo, jetreni perfuzioni indeks