

A rare case of high-grade synovial sarcoma of the hindfoot

Chiara Comisi^{1,2,†}, Tommaso Greco^{1,3,†}, Camillo Fulchignoni^{1,2}, Antonio Mascio^{1,2}, Francesco Farine^{1,2}, Elisa Troiano⁴, Nicola Mondanelli⁴, Giulio Menichini⁵, Elisabetta Pataia^{1,2}, Giulio Maccauro^{1,2}, Carlo Perisano^{1,2}

¹Department of Aging, Orthopaedic and Rheumatologic Sciences, Orthopaedics and Trauma Surgery Unit, Fondazione Policlinico Universitario Agostino Gemelli IRCCS, Rome, ²Orthopaedics and Trauma Surgery, Università Cattolica del Sacro Cuore, Rome, ³Department of Life Sciences, Health, and Healthcare Profession, Link Campus University, Rome; Italy, ⁴Department of Medicine Surgery and Neurosciences, University of Siena, Siena, ⁵Plastic and Reconstructive Microsurgery - Careggi University Hospital - Florence, Italy.

ABSTRACT

Aim To report our personal experience in hindfoot reconstruction using an anterolateral thigh (ALT) free flap following radical resection of a high-grade synovial sarcoma.

Methods The patient underwent clinical and imaging assessments, and a biopsy of the lesion confirmed the diagnosis of synovial sarcoma (SS) of the hindfoot. A multidisciplinary team was involved to define the most appropriate therapeutic strategy.

Results After radical resection of the tumor mass, soft tissue coverage of the extensive skin defect was achieved using an ALT free flap. No local recurrences were observed during the follow-up period. At approximately twenty-four months after surgical treatment, the patient is able to ambulate independently, with no significant limitations in daily activities.

Conclusion The complex management of this rare disease requires a dedicated reference centre for foot and ankle surgery, supported by a multidisciplinary team including expert orthopaedic and plastic surgeons, as well as specialized oncologists, to ensure accurate diagnosis and appropriate treatment.

Key words: flap, foot, limb salvage, reconstructive surgical procedures, soft tissue sarcoma

INTRODUCTION

Synovial Sarcoma (SS) is a rare mesenchymal-origin neoplasm (1) accounting for about 1% of all tumours and about 5–10% of all soft tissue sarcomas (STS) (2,3). It can occur at any age, but it is most commonly seen in older children and younger adults, where the prognosis is generally more favourable compared with SS in adults patients (3-5). Typically, in adult patients, it is considered an aggressive high-grade malignancy with a poor prognosis and a life expectancy of 5 years (6,7). Moreover, SS has a high metastatic potential (3), and its prognosis depends not only on the presence of metastases but also on factors such as size, grade, and location (4,6,8).

The SS is defined by the specific genetic translocation between chromosomes X and 18, leading to the expression of SS18:SSX fusion proteins. This translocation is pathognomonic for SS diagnosis and is an important diagnostic tool (9,10). According to the World Health Organization (WHO) classification (1) of STS, SS commonly affects the extremities, trunk wall, and retroperitoneum (2). While the lower extremities are the most involved site, SS occurrence in the hindfoot is partic-

ularly rare, with only limited data available in the literature. A definitive diagnosis can only be obtained through a biopsy of a valid and representative tissue sample, which should be performed prior to any definitive surgery (11).

Several different therapeutic approaches have been described in the literature. Surgical radical resection remains the gold standard for treatment of SS, significantly impacting overall outcomes and survival rates (12). Neoadjuvant and adjuvant radiotherapy is recommended for larger tumours (>5 cm), or in any case where a close margin may be required to preserve a major neurovascular structure or bone (11). It can play an important role in achieving local disease control by reducing the risk of recurrence, particularly in cases with localized SS. In patients with metastasis, lesion locally advanced, or unresectable tumours, radiotherapy (RT) can be useful for palliative purposes (3,12,13). The role of chemotherapy in SS management remains controversial, with current evidence that it may be beneficial in selected cases, such as advanced or metastatic disease, while its routine use is not yet well established (14,15). Limb preservation and the achievement of an acceptable function have become the major goal of oncological and reconstructive surgery, and a multidisciplinary approach is required (16,17).

The aim of this study was to report a rare case of high-grade SS of the hindfoot, treated with wide surgical resection and reconstruction with an ALT free flap. To the best of our knowledge, this is one of the few cases in which this flap has been used for the soft tissues reconstruction of the foot in a patient affected by a malignant tumour.

*Corresponding author: Tommaso Greco

Department of Life Sciences, Health, and Healthcare Profession, Link Campus University, Rome, Italy

Phone: +39 3807582118

E-mail: greco.tommaso@outlook.it

PATIENT AND METHODS

Patient and study design

A 54-year-old man with no significant comorbidities came for the first time to the Outpatient Clinic of Orthopaedics and Traumatology Department. He reported about twelve-year history of a progressively evolving soft tissue lesion located on the posteromedial aspect of the heel. Initially evaluated by several orthopaedic specialists, the patient underwent various diagnostic investigations, including ultrasound (US), X-ray, and magnetic resonance imaging (MRI); however, none of these allowed for a definitive diagnosis. A core needle biopsy was subsequently performed to obtain a histological specimen, which yielded a negative result.

At the time of the visit, the patient reported increasing difficulty in walking and severe heel pain, which had significantly worsened over the preceding months. A recent MRI confirmed progression of the lesion. On clinical examination, the patient presented an antalgic gait and a poorly defined, painful, and hard ovular mass located on the posteromedial aspect of the heel, measuring approximately 7x5 cm of size (Figure 1).

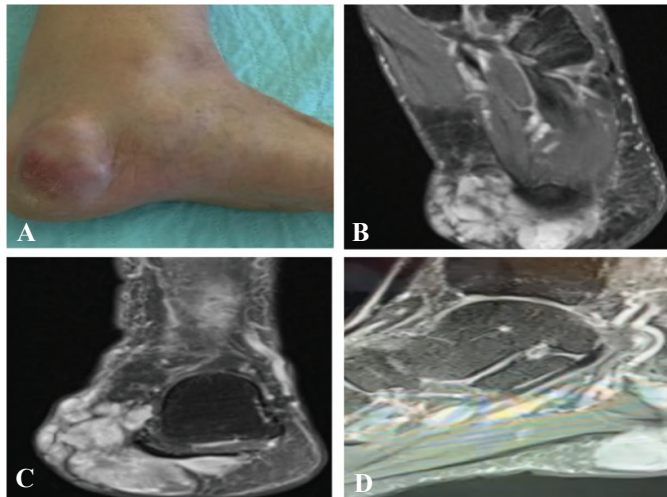


Figure 1. Clinical examination of A) hard, tender, and oval mass, B) axial, C) coronal, and D) sagittal Magnetic Resonance Imaging projections of the lesion

Methods

A CT-guided incisional biopsy was promptly performed to obtain a representative tissue sample for histopathological analysis. Under general anaesthesia, the patient was placed in a supine position with a pneumatic ischemic transitory tourniquet at the apex of the thigh. Initially, the first stage of surgery was the demolitive phase. A diamond-shaped incision, including the entire lesion, was performed. The tumour lesion was identified and, after its careful dissection and blunt dissection from surrounding tissues, it was excised en-bloc for the histological examination (Figure 2). Subsequently, a tangential resection of the medial bony margin of the heel was performed, and an intraoperative biopsy was carried out, yielding a negative result. At this stage, it is crucial to perform a meticulous curettage of the lesion and ensure that it has been completely excised en-bloc in order to prevent local recurrences, so that the bone resection and soft tissue debridement were carried out with wide margins. Following this, the second stage, the reconstructive phase, was performed with the assistance of the orthopaedic plastic surgeon. A double sterile operative field, including the contralateral lower limb,

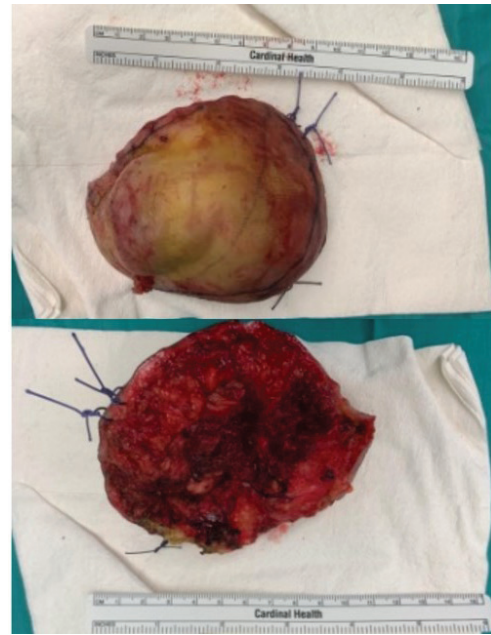


Figure 2. Demolitive phase: en-bloc tumour mass resected

was set up. After identifying the perforating vessels in the thigh contralateral to the lesion, using a Doppler probe, a large pedicled flap (12x15 cm) was prepared. Following check-up of the adequate perfusion of the flap, it was positioned at the recipient site to ensure sufficient coverage of the tissue loss. Microsurgical anastomoses were performed using Ethilon 9.0 sutures between one artery and two veins with the corresponding recipient vessels of the posterior tibial bundle, previously identified and prepared (Figure 3). This very delicate phase typically requires two surgeons at the microscope with a third assisting in the procedure. The donor site (wider than 8 cm) was covered with a dermo-epidermal graft harvested, using a specific dermatome, from the antero-medial aspect of the same-side thigh. A drainage tube was inserted and removed approximately 48 hours later.

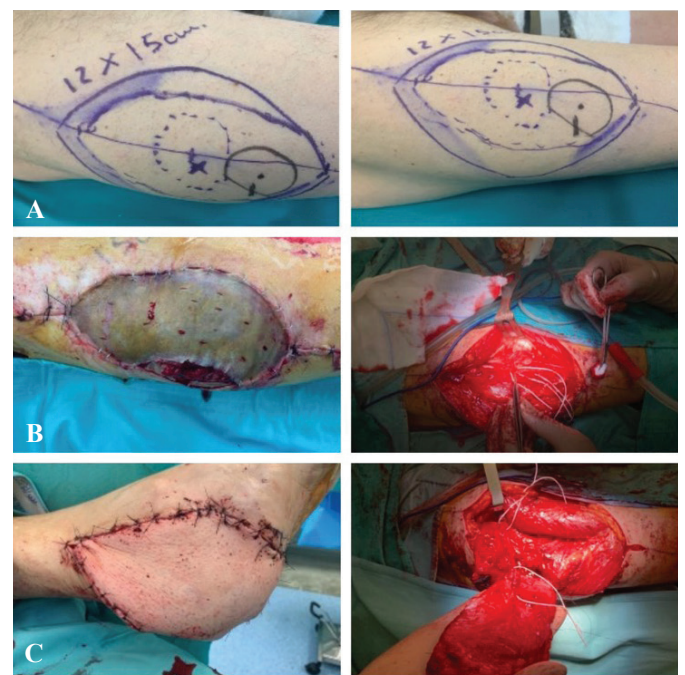


Figure 3. Reconstructive phase with anterolateral thigh (ALT) free flap. A) Intraoperative planning of flap harvesting; B) Harvesting of the ALT flap with dermo-epidermal skin grafting at the donor site; C) Microvascular anastomosis of the ALT flap to cover the skin defect on the heel

RESULT

Histopathological analysis confirmed the diagnosis of high-grade SS of the hindfoot soft tissues (Figure 4).

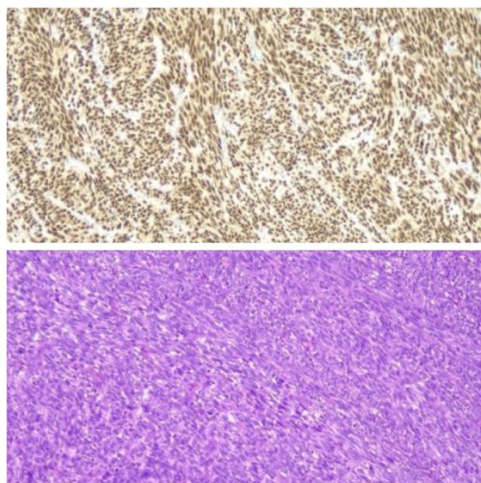


Figure 4. The neoplastic cells tested positive, in immunohistochemical investigations for SS18-SSX and focally for TLE1 and CD99 (above); Malignant mesenchymal neoplasm with spindle cells consistent with synovial sarcoma (below)

A subsequent total-body CT scan revealed the presence of pulmonary metastases.

Following a multidisciplinary team board, we decided not to proceed with preoperative radiotherapy due to the urgency of surgical intervention, given the rapid progression in lesion size, and the presence of pulmonary metastases. Additionally, in light of the planned soft tissue reconstruction using a free flap, we aimed to avoid the well-documented complications of radiotherapy such as delayed wound healing, dehiscence, and reduced flap vitality. Therefore, the patient underwent wide en-bloc tumour resection and soft tissue reconstruction, using an ALT free flap during the same surgical time. Following surgery, the patient immediately began a dedicated chemotherapy regimen. The patient was instructed to avoid weight-bearing for 30 days, and a dual anticoagulant and antiplatelet therapy was prescribed. Additionally, meticulous medications and daily refill test of the flap were performed. In this case, post-operative management was carried out as we typically handle flaps at our institution. During the first few postoperative days, the lower limb was maintained in an anti-gravitational position, ensuring that nothing, not even the pillow, could compress or make pressure on the flap site. After 48 hours, the first dressing change was performed by the plastic surgeon, and the patient was assisted in standing and walking with crutches, while adhering to the weight-bearing restrictions.

After discharge, strictly post-operative controls were performed after 7, 15, and 30 days after the surgery. The dressings were performed using Betadine, fat gauze, sterile gauze, and non-tight bandages.

No peri-operative and early post-operative complications were noted. The patient immediately began a dedicated chemotherapy regimen and came to visit at two, three, six, nine, and twelve and twenty-four months. He subsequently underwent CT-total body and MRI which respectively showed no diffuse or local recurrences. Partial and full weight bearing free of pain were allowed in 30 and 45 days. The patient returned to daily life activities in three months (Figure 5).

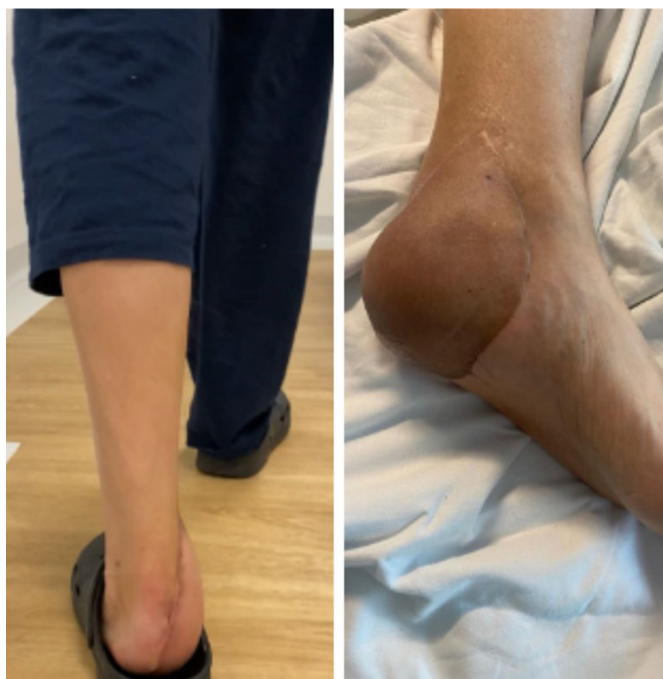

Figure 5. Clinical outcomes after 24 months of follow-up with complete wound healing and the patient able to walk independently

DISCUSSION

Radical oncological excision combined with limb-salvage treatment has become increasingly common in the management of STS. This approach, supported by a well-coordinated multidisciplinary assessment, has significantly improved local control of the disease, drastically reducing the need for amputations.

In modern clinical practice, free flaps have become an effective strategy for limb preservation and functional restoration, particularly in cases involving extensive tissue loss due to complex trauma, extensive oncological resections, or severe infections (18-20). These challenging scenarios require not only advanced surgical expertise but also a global approach to patient care. A multidisciplinary team including orthopaedic and plastic surgeons, oncologists, radiologists, physiotherapists, and other specialists, plays a crucial role in evaluating the patient globally. This comprehensive approach improves functional outcomes and quality of life, reducing local and general complications.

Particularly in the field of limb-salvage surgery, the use of advanced reconstructive techniques, such as free flaps, has revolutionized patient care (21). Their versatility to provide well-vascularized tissue, which can be shaped and adapted to the defect, makes them an indispensable option in complex reconstructive surgery (22,23). This not only optimizes surgical outcomes but also supports long-term rehabilitation, supporting patients to recover mobility and maintain a high quality of life. Considerations in reconstruction include adequate tissue stock for defect coverage, minimal donor site morbidity, availability of diverse tissue types on one pedicle, feasibility of simultaneous two team approach, consistent anatomy, the potential for reinnervation, as well as sufficiently large and long pedicle (24,25).

Several studies have demonstrated the advantages of free flaps in covering large lower limbs defects following radical oncological resection of STS, demonstrating their crucial role in optimizing both functional and aesthetic outcomes. Latt et al.

(26) reported a series of patients with STS of the foot who underwent wide resection followed by plastic surgery reconstruction. Various reconstructive options were utilized, including the latissimus dorsi, the lateral arm flap, and the free fibula flap with its fascio-cutaneous component. Similarly, Battiston et al. (18) described a case of dorsal midfoot reconstruction using a free serratus and rib flap.

Among the available techniques, the ALT free flap provides significant coverage, and their vascular pedicles ensure safe microsurgical transfer, even to the most anatomically challenging locations (27). While the ALT flap is widely recognized for its applications in head and neck reconstruction (24,28,29), its use in limb salvage has gained increasing attention (30). Since its first description by Song et al. (31) in 1984, the ALT flap has become one of the most commonly used options for the reconstruction of large soft tissue defects (27). Its combination of a broad, thin skin paddle and a long, reliable vascular pedicle makes it highly versatile and adaptable to a variety of clinical scenarios (23,32-34). Moreover, Koshima et al. (35) have highlighted the advantages of using the ALT flap, emphasizing how its large skin surface and long vascular pedicle allow optimal adaptation to post-oncological reconstructive needs (36). It can be employed as a cutaneous, fascio-cutaneous, or muscular flap depending on the requirements, offering a personalized option for patients (37-39).

Reconstruction of the hindfoot and soft tissues following surgical resection of STS using the ALT flap has been rarely documented in the current literature. Ozkan et al. (20) reported a series of five cases involving patients with unspecified tumours, three located in the distal leg and two in the foot, all successfully treated with the ALT flap. Similarly, Maruccia et al. (21) described a case of a 35-year-old woman with a recurrent sarcoma of the hindfoot. Following wide surgical excision, a significant soft tissue defect remained, necessitating reconstruction with an ALT free flap. The procedure provided durable coverage and restored limb integrity (40). It described a 55-years-old patient who had undergone wide excision of a synovial sarcoma in the distal lower leg and reconstruction with ALT free flap and vascularized fascia lata, to cover wide defect including skin and muscles (40).

The strength of our study lies in advocating the application of the ALT flap as a valid and effective solution for the tissue loss coverage in the hindfoot. Its versatility and reliability make it particularly suitable for treating large tissue defects following oncological resections, especially in areas where preserving functionality and mobility is critical for the patient. Moreover, the ALT free flap has proven to be suitable for covering large skin and soft tissue defects due to fractures, post-traumatic injuries, and osteomyelitis (41,42).

The study has several limitations. Firstly, as a case report, the conclusions drawn are based on a single clinical case, which limits the reproducibility of the outcome. However, we are actively expanding our case series and aim to systematically employ this flap in suitable patients, allowing for a broader evaluation of its effectiveness and potential indications in various clinical scenarios.

Another limitation is the relatively short follow-up period. However, although the duration of the follow-up may not have been extensive, we can assess that its use is suitable and indicated in terms of healing, adaptability, and functionality. Early

postoperative outcome has been promising, with the flap integrating well into the recipient site and providing stable coverage. Longer-term follow-up studies will be crucial to assess the durability of the results and monitor for any late complications, but the current data already suggest that this flap is a reliable reconstructive option. In our case, we did not observe flap failure as a complication. Unfortunately, this remains a possible outcome despite all precautions and appropriate medical therapies. In those cases, wound care should still be debrided and refreshed in order to promote bleeding. In cases of definitive failure, alternative flaps should be considered, many of which are well-suited to covering skin defects based on their size and complexity. It would be both interesting and useful to further investigate this topic in the literature.

Despite these limitations, the study is significant as it highlights the potential of ALT free flap to serve as a viable alternative in reconstructive surgery. By documenting its successful application, we hope this report will encourage surgeons to consider this flap among their choices for managing complex lower limb tissue defects.

Limb salvage surgery is the new challenge in the treatment of malignant bone and soft tissues tumours involving lower extremities; plastic surgical techniques can frequently reduce functional impairment and cover soft-tissue defects, particularly in cases of large tumour size or localization adjacent to critical anatomic structures, thereby improving the quality of life for these patients (43-45).

This case adds to the growing body of evidence supporting its utility, and with further studies, we aim to provide even more robust guidance for its use in reconstructive practices.

A major reference centre is necessary so that oncologists, orthopaedics, and plastic surgeons can establish an appropriate diagnostic-therapeutic assessment for each patient.

In conclusion, SS is a rare and aggressive high-grade malignancy, and it requires complex management. Our experience demonstrates a good and effective outcome using the ALT flap in patients with soft tissue tumours of the lower limbs, providing a valid and safe solution to ensure adequate tissue coverage and rapid return to limb functionality. In the future, further research is warranted to explore specific indications for the use of the ALT flap in combination with other reconstructive techniques and to analyse new surgical approaches to additionally reduce complication rates. This would help further improve both functional and aesthetic outcomes in oncological patients.

AUTHORS CONTRIBUTIONS

Conceptualization, C.C.; methodology, A.M.; validation, E.P., C.F.; formal analysis, F.F., N.M.; investigation, C.F.; resources, E.P.; data curation, C.C.; writing—original draft preparation, C.C.; writing—review and editing, T.G.; visualization, C.F., E.T.; supervision, G.M., C.P.; project administration, C.P. All authors have read and agreed to the published version of the manuscript.

FUNDING

No specific funding was received for this study.

TRANSPARENCY DECLARATION

Competing interests: None to declare.

REFERENCES

- Fletcher CDM (Ed.). Pathology and genetics of tumours of soft tissue and bone. Lyon: IARC Press, 2002: 427.
- Mastrangelo G, Coindre JM, Ducimetière F, Dei Tos AP, Fadda E, Blay JY, et al. Incidence of soft tissue sarcoma and beyond: a population-based prospective study in 3 European regions. *Cancer* 2012; 118(21):5339–48.
- Mangla A, Gasalberti DP. Synovial Cell Sarcoma. In: StatPearls [Internet]. Treasure Island (FL): StatPearls Publishing; 2025. <http://www.ncbi.nlm.nih.gov/books/NBK587366/> (accessed April 21, 2025).
- Vlenterie M, Ho VKY, Kaal SEJ, Vlenterie R, Haas R, van der Graaf WTA. Age as an independent prognostic factor for survival of localised synovial sarcoma patients. *Br J Cancer* 2015; 113(11):1602–6.
- Herzog CE. Overview of sarcomas in the adolescent and young adult population. *J Pediatr Hematol Oncol* 2005; 27 (4):215–8.
- Ferrari A, Miceli R, Casanova M, Gronchi A, Collini P, Meazza C, et al. Adult-type soft tissue sarcomas in paediatric age: a nomogram-based prognostic comparison with adult sarcoma. *Eur J Cancer Oxf Engl* 2007; 43(18):2691–7.
- Ferrari A, Gronchi A, Casanova M, Meazza C, Gandola L, Collini P, et al. Synovial sarcoma: a retrospective analysis of 271 patients of all ages treated at a single institution. *Cancer* 2004; (101):627–34.
- Ferrari A, Bisogno G, Alaggio R, Cecchetto G, Collini P, Rosolen A, et al. Synovial sarcoma of children and adolescents: the prognostic role of axial sites. *Eur J Cancer Oxf Engl* 2008; 44(9):1202–9.
- Crew AJ, Clark J, Fisher C, Gill S, Grimer R, Chand A, et al. Fusion of SYT to two genes, SSX1 and SSX2, encoding proteins with homology to the Kruppel-associated box in human synovial sarcoma. *EMBO J* 1995; 14(10):2333–40.
- Kadoch C, Crabtree GR. Reversible disruption of mSWI/SNF (BAF) complexes by the SS18-SSX oncogenic fusion in synovial sarcoma. *Cell* 2013; 153(1):71–85.
- Gazendam AM, Popovic S, Munir S, Parasu N, Wilson D, Ghert M. Synovial Sarcoma: A Clinical Review. *Curr Oncol* 2021; 28(3):1909–20.
- Randall RL, Schabel KLS, Hitchcock Y, Joyner DE, Albritton KH. Diagnosis and Management of Synovial Sarcoma. *Curr Treat Options Oncol* 2005; 6(6):449–59.
- O’Sullivan B, Davis AM, Turcotte R, Bell R, Catton C, Chabot P, et al. Preoperative versus postoperative radiotherapy in soft-tissue sarcoma of the limbs: a randomised trial. *Lancet* 2002; 359(9325):2235–41.
- Xu G, Aiba H, Yamamoto N, Hayashi K, Takeuchi A, Miwa S, et al. Efficacy of perioperative chemotherapy for synovial sarcoma: a retrospective analysis of a Nationwide database in Japan. *BMC Cancer* 2021; 21:773.
- Eilber FC, Brennan MF, Eilber FR, Eckardt JJ, Grobmyer SR, Riedel E, et al. Chemotherapy is associated with improved survival in adult patients with primary extremity synovial sarcoma. *Ann Surg* 2007; 246(1):105–13.
- Guadagnolo BA, Zagars GK, Ballo MT, Patel SR, Lewis VO, Pisters PWT, et al. Long-term outcomes for synovial sarcoma treated with conservation surgery and radiotherapy. *Int J Radiat Oncol Biol Phys* 2007; 69(4):1173–80.
- Ghert MA, Abudu A, Driver N, Davis AM, Griffin AM, Pearce D, et al. The Indications for and the Prognostic Significance of Amputation as the Primary Surgical Procedure for Localized Soft Tissue Sarcoma of the Extremity. *Ann Surg Oncol* 2005; 12(1):10–7.
- Battiston B, Artiaco S, Piana R, Boux E, Tos P. Midfoot reconstruction with serratus anterior–rib osteomuscular free flap following oncological resection of synovial sarcoma. *J Orthop Traumatol* 2015; 16(4):347–50.
- Popov P, Tukiainen E, Asko-Seljaavaara S, Huuhtanen R, Virolainen M, Virkkunen P, et al. Soft tissue sarcomas of the lower extremity: surgical treatment and outcome. *Eur J Surg Oncol* 2000; (26):679–85.
- Ozkan O, Coşkunfirat OK, Ozgentaş HE. The use of free anterolateral thigh flap for reconstructing soft tissue defects of the lower extremities. *Ann Plast Surg* 2004; 54(5):455–61.
- Maruccia M, Elia R, Caizzi G, Carrozzo M, Vicenti G, Moretti B, et al. Free flap and kickstand external fixator in foot and ankle soft tissue reconstruction. The versatility of a microsurgical-friendly application of an orthopedic device. *Injury* 2018; 49:S105–9.
- Ferguson PC. Surgical considerations for management of distal extremity soft tissue sarcomas. *Curr Opin Oncol* 2005; 17(4):366–9.
- Kuo Y-R, Seng-Feng J, Kuo FM, Liu YT, Lai PW. Versatility of the free anterolateral thigh flap for reconstruction of soft-tissue defects: review of 140 cases. *Ann Plast Surg* 2002; 48(2):161–6.
- Smith RK, Wykes J, Martin DT, Niles N. Perforator variability in the anterolateral thigh free flap: a systematic review. *Surg Radiol Anat* 2017; 39(7):779–89.
- Chana JS, Odili J. Perforator flaps in head and neck reconstruction. *Semin Plas. Surg* 2010; 24(3):237–54.
- Latt LD, Turcotte RE, Isler MH, Wong C. Soft-tissue sarcoma of the foot. *Can J Surg* 2010; 53(6):424–31.
- Wei FC, Mardini S. Free-style free flaps. *Plast Reconstr Surg* 2004; 114 (4):910–6.
- Trojanowski P., Szymański M, Trojanowska A, Andrzejczak A, Szczepanek D, Klatka J. Anterolateral thigh free flap in reconstruction of lateral skull base defects after oncological resection. *Eur Arch Otorhinolaryngol* 2019; 276(12):3487–94.
- Kimata Y, Uchiyama K, Ebihara S, Yoshizumi T, Asai M, Saikawa M, et al. Versatility of the free anterolateral thigh flap for reconstruction of head and neck defects. *Arch Otolaryngol Head Neck Surg* 1997; 123(12):1325–31.
- Yildirim S, Avci G, Aköz T. Soft-tissue reconstruction using a free anterolateral thigh flap: experience with 28 patients. *Ann Plast Surg* 2003; 51(1):37–44.
- Song YG, Chen GZ, Song Y. The free thigh flap: a new free flap concept based on the septocutaneous artery. *Br J Plast Surg* 1984; 37(2):49–59.
- Chen H, Tang Y. Anterolateral thigh flap: an ideal soft tissue flap. *Clin Plast Surg* 2003; 30(3):383–401.
- Masquelet AC, Romana MC. Vascularization of the skin of the limbs and surgical applications. *Rev Chir Orthop* 1988; 74(7):669–76.

34. Landuyt KV. The Anterolateral Thigh Flap for Lower Extremity Reconstruction. *Semin. Plast Surg* 2006; 20(2):127–32.
35. Koshima I, Fukuda H, Yamamoto H, Moriguchi T, Soeda S, Ohta S. Free anterolateral thigh flaps for reconstruction of head and neck defects. *Plast Reconstr Surg* 1993; 92(3):421–8.
36. Graboyes EM, Hornig JD. Evolution of the anterolateral thigh free flap. *Curr Opin Otolaryngol Head Neck Surg* 2017; 25(5):416–21.
37. Sinna R, Gianfermi M, Benhaim T, Qassemyar Q, Robbe M. Reconstruction of a full-thickness abdominal wall defect using an anterolateral thigh free flap. *J Visc Surg* 2010; 147(2):e49–53.
38. Wei F, Jain V, Celik N, Chen H, Chuang DCC, Lin C. Have we found an ideal soft-tissue flap? An experience with 672 anterolateral thigh flaps. *Plast Reconstr Surg* 2002; 109(7):2219–22.
39. Ranganath K, Jalisi SM, Naples JG, Gomez ED. Comparing outcomes of radial forearm free flaps and anterolateral thigh free flaps in oral cavity reconstruction: A systematic review and meta-analysis. *Oral Oncol* 2022; 135:106214.
40. Lykoudis EG, Dalianoudis I, Seretis K, Lykoudis GE, Lykissas MG. Single stage functional reconstruction of both peroneal tendons and overlying skin with an anterolateral thigh flap and vascularized fascia lata: A case report. *Microsurgery* 2018; 38(3):318–23.
41. Fulchignoni C, Pietramala S, Lopez I, Mazzella GG, Comisi C, Perisano C, et al. Surgical Outcomes and Complications of Custom-Made Prostheses in Upper Limb Oncological Reconstruction: A Systematic Review. *J Func. Morpho. Kinesiol* 2024; (9):72.
42. Comisi C, Greco T, Inverso M, Mascio A, Polichetti C, Barbaliscia M, et al. Tibiototalcalcaneal arthrodesis in a rare case of tuberculosis of the talus. *Med Glas (Zenica)* 2024; 21(1):222–8.
43. Gronchi A, Casali PG, Mariani L, Miceli R, Fiore M, Lo Vullo S, et al. Status of surgical margins and prognosis in adult soft tissue sarcomas of the extremities: a series of patients treated at a single institution. *J Clin Oncol* 2005; 23(1):96–104.
44. Spyropoulou A, Jeng S-F. Microsurgical Coverage Reconstruction in Upper and Lower Extremities. *Semin Plas. Surg* 2010; 24(1):34–42.
45. Lee YJ, Lee YJ, Oh DY, Jun YJ, Rhie JW, Moon S.-H. Reconstruction of wide soft tissue defects with extended anterolateral thigh perforator flap turbocharged technique with anteromedial thigh perforator. *Microsurgery* 2020; 40(4):440–6.