

The challenge of nonunion and malunion in distal femur surgical revision

Giuseppe Rollo¹, Paolo Pichierri¹, Predrag Grubor², Antonio Marsilio¹, Michele Bisaccia³, Milan Grubor², Valerio Pace³, Riccardo Maria Lanzetti⁴, Marco Giaracuni¹, Marco Filipponi¹, Luigi Meccariello¹

¹Department of Orthopaedics and Traumatology, Vito Fazzi Hospital, Lecce Italy, ²School of Medicine, University of Banja Luka, Bosnia and Herzegovina, ³Department of Orthopaedics and Traumatology, Azienda Ospedaliera "Santa Maria della Misericordia", Perugia, ⁴Orthopaedic Unit and "Kirk Kilgour" Sports Injury Centre, S. Andrea Hospital, University of Rome "La Sapienza", Rome; Italy

ABSTRACT

Aim To demonstrate validity of a bio-metallic solution in bone healing combined with the quadriceps safe approach in the treatment of nonunions of distal femur while malunions were treated by metallic solution.

Methods We treated 57 patients with nonunion or malunion of distal femur at the Orthopaedics and Traumatology Department of a single orthopaedic trauma centre (Italy). A total of 57 patients were divided in two groups: the first (NU) group was composed of 35 patients affected; the second group (MU) was composed of 22 patients affected by malunion of distal femur. Criteria chosen to evaluate the two groups during a clinical and radiological follow-up were: the quality of life measured by the Short Form (12) Health Survey, the knee function and quality of life related to it measured by the Knee Injury and Osteoarthritis Outcome Score KOOS and the Knee Society Score, bone healing measured by modified Radiographic Union Score by X-rays during the follow-up and CT at one year after the surgery, the difference of the limbs length before and after the revision surgery, and postoperative complications. The evaluation endpoint was set at 12 months.

Results There were no statistical differences between the two groups.

Conclusion The role of bio-metallic solution in the treatment of nonunions and malunions is to recreate the knee anatomy and functionality compatible with a satisfactory quality of life.

Key words: femoral fractures, internal fracture fixation, malunited fracture, nonunited fracture, revision surgery

Corresponding author:

Luigi Meccariello
Department of Orthopedics and
Traumatology, Vito Fazzi Hospital,
Piazzetta Filippo Muratore,
Block: A- Floor: V, Lecce, Italy
Phone: +393299419574;
Fax: +390823713864;
E-mail: drlordmec@gmail.com
ORCID ID: <https://orcid.org/0000-0002-3669-189X>

Original submission:

20 February 2019;

Revised submission:

06 May 2019;

Accepted:

13 May 2019.

doi: 10.17392/1016-19

INTRODUCTION

Distal femoral fractures are a common orthopaedic problem in patients of all ages, with an annual incidence of about 37 every 100,000 people (1). The nonunion and malunion of distal femur fractures are relatively rare and difficult to treat (2,3). They can occur after surgical and bloodless treatment with similar frequency (2,3). The main causes of nonunion of the distal femur are: inadequate fracture fixation that does not give stability to the fracture site, avascularization of the fracture site due to excessive separation of soft tissues, excessive fracture bone gap, infection, endogenous causes patient related, experience of the surgeon (2). Malunions are instead related more to the metalwork and experience of the surgeon in the reduction of the most difficult and challenging fractures (4). In the treatment of these injuries the surgeon's ultimate goal is to achieve good fracture reduction and bone union without complications. In addition, it is important for the surgeon to correct malalignment (if present) and avoid infection. There is no common and shared method for the treatment of nonunion and union of distal femur fractures surgically treated (2).

The aim of this study was to demonstrate the validity and efficacy of the surgical treatment of malunion and nonunion complications of distal femur fractures in terms of bone healing for patients treated at a single orthopaedic specialist centre. Patients with malunion were treated with bone allograft strut of the femur and blade plate with screws combined with the quadriceps safe approach (bio-metallic solution), while malunions were treated with blade plate and screws (metallic solution).

PATIENTS AND METHODS

Material and study design

This retrospective study included two heterogeneous populations characterized by the most common causes of metalwork failure in the treatment of fractures of the distal femur. From January 2000 to March 2017, 57 patients were treated with non-union or mal-union of distal femur fractures surgically managed at the Orthopaedics and Traumatology Department of the Vito Fazzi Hospital, Lecce, Italy. The patients were divided into two groups: the first group (non-union, NU)

was composed of 35 patients with non-union of distal femur fractures; the second group (malunion, MU) was composed of 22 patients with malunion of distal femur fractures.

Inclusion criteria were: nonunion or malunion of distal femur fractures, 33.A and 33.B type of injury according to the AO classification system (5), all ages, both genders, pre-trauma conditions and absence of local or systemic disease that could affect the surgical treatment and comorbidity and mortality, fitness to undergo surgery from the aesthetic team, availability for 12 months of postoperative clinical and radiological follow up. Exclusion criteria were: fractures caused by haematological or oncological pathologies; 33.B type of injury according to the AO classification system (5), significant knee osteoarthritis, avascular necrosis of femoral condyle, leg length discrepancy for more than 3 cm before the trauma.

All patients of the two groups were informed in a clear and comprehensive way of the type of treatment and other possible surgical and conservative alternatives. Patients were treated according to the ethical standards of the Helsinki Declaration, and were invited to read, understand, and sign an informed consent form.

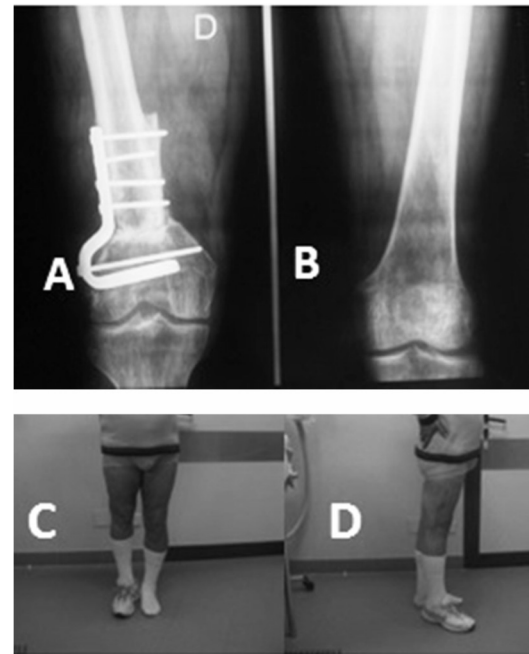
Methods

The chosen criteria to evaluate the two groups during the clinical and radiological follow-up were: quality of life measured by the Short Form (6) Health Survey (SF-12) (6) and related knee function and quality of life measured by the Knee Injury and Osteoarthritis Outcome Score (KOOS) (7) and the Knee Society Score (KSS) (7), bone healing measured by modified Radiographic Union Score (RUS) (8) by X-rays during the follow-up and CT at one year after the surgery, leg length discrepancy before and after revision surgery, postoperative complications. The evaluation endpoint was set at 12 months post-op.

Nonunion surgical technique. In all cases, surgery was performed with patient in supine position using the direct anterior approach to the injured distal femur. This consists in a modification of the traditional surgical access with the aim to preserve the insertion of the patellar tendon on the tibial apophysis, by incising fascia between the vastus lateralis muscle and the rectus femoris muscle and again more medially between the rectus femoris

muscle and the vastus medialis muscle. The medial and lateral incisions have never involved the tendon junction of the three muscles at the level of the quadriceps tendon area. After this approach the surgeon can raise the rectus femoris to favour exposure; this allows good fracture reduction and synthesis with access from both medial and lateral side. Moreover, this technique allows adequate preservation of both the surrounding vessels and nerves from possible trauma or stupor. After appropriate exposure of the nonunion site, the previous implanted metalwork was removed with dedicated surgical kits; the nonunion site was bloodied, allogeneic bone strut was prepared on a separate table after performing tampon dye tests to reduce the risk of infection. The modelling of the femur bone strut should always be measured two and a half times the extent of the nonunion site. The distal portion of the strut was modelled to “flame” to be as congruent as possible to the anatomical shape of a metaphyseal passage to the medial femoral condyle. Margins of the nonunion site were modelled in such a way to create a wide surface for a stable compression osteosynthesis. The hardware for the osteosynthesis used in all cases was a condylar blade steel plate. This was applied to the fracture site together with compression cortical screws to stabilize the strut bone, and placed to reinforce the medial wall of the diaphysis and distal metaphysis. Furthermore, the space gap between the strut and the bone was filled in with morcelized bone and bone paste. Placement of fixation metalwork was checked throughout the procedure and again at the

end of the osteosynthesis by fluoroscopy imaging. Finally fascia, subcutaneous and cutaneous tissues were sutured in layers after adequate lavage and accurate haemostasis (Figure 1, 2).



2. A) X-ray of union of distal femur nonunion; B) the X-ray of the left non- injured knee in the same patient; C, D) the difference in length to the right a rise of 3.2 cm; the patient reported good functional recovery and did not want to undergo subsequent interventions to rebalance the lower limbs in length (Rollo G, 2015)

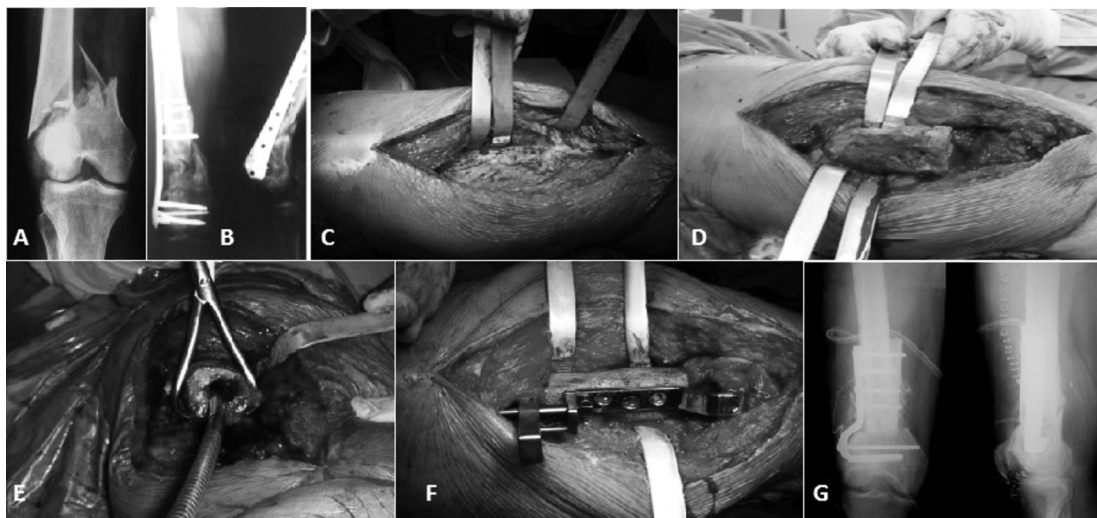


Figure 1. A) X-rays of distal femur's supra condylar fracture (33.A3 according AO/ OTA) in 62 years old male; B) fracture with a plate and screws (LISS) hesitated in non-union after 9 months after surgical treatment; C) exposure of plate and wires for removal per via modified para vastus lateralis approach; D) exposure of the proximal segment of the nonunion; E) reaming of the medullary canal; F) implant of plate blade system; G) X-rays of post-operative (Rollo G, 2014)

Malunion surgical technique. In all cases, surgery was performed with patient in supine position using the direct anterior approach to the injured distal femur. Approach and exposure were identical to the above described surgical procedure for NU cases. After exposing the malunion site, the previous implanted metalwork was removed and corrective osteotomy was performed in accordance with the specific need of deformity correction depending on single patients' pattern of injury; the allogenic bone strut was prepared on a separate table after performing tampons to reduce the risk of infection. The margins of the nonunion site were modelled in such a way to create a wide surface for a stable compression osteosynthesis.

The hardware for the osteosynthesis used in all cases was a condylar blade steel plate. This was applied with dedicated surgical kits to the fracture site together with compression cortical screws to stabilize the bone strut, placed to reinforce the medial wall of diaphysis and distal metaphysis. Furthermore, the gap left between the stick and the bone was compressed with morcelized bone and bone paste. Placement of fixation metalwork was checked throughout the procedure and again at the end of the osteosynthesis by fluoroscopy imaging. Finally, fascia, subcutaneous and cutaneous tissues were sutured in layers after adequate lavage and accurate haemostasis (Figure 3).

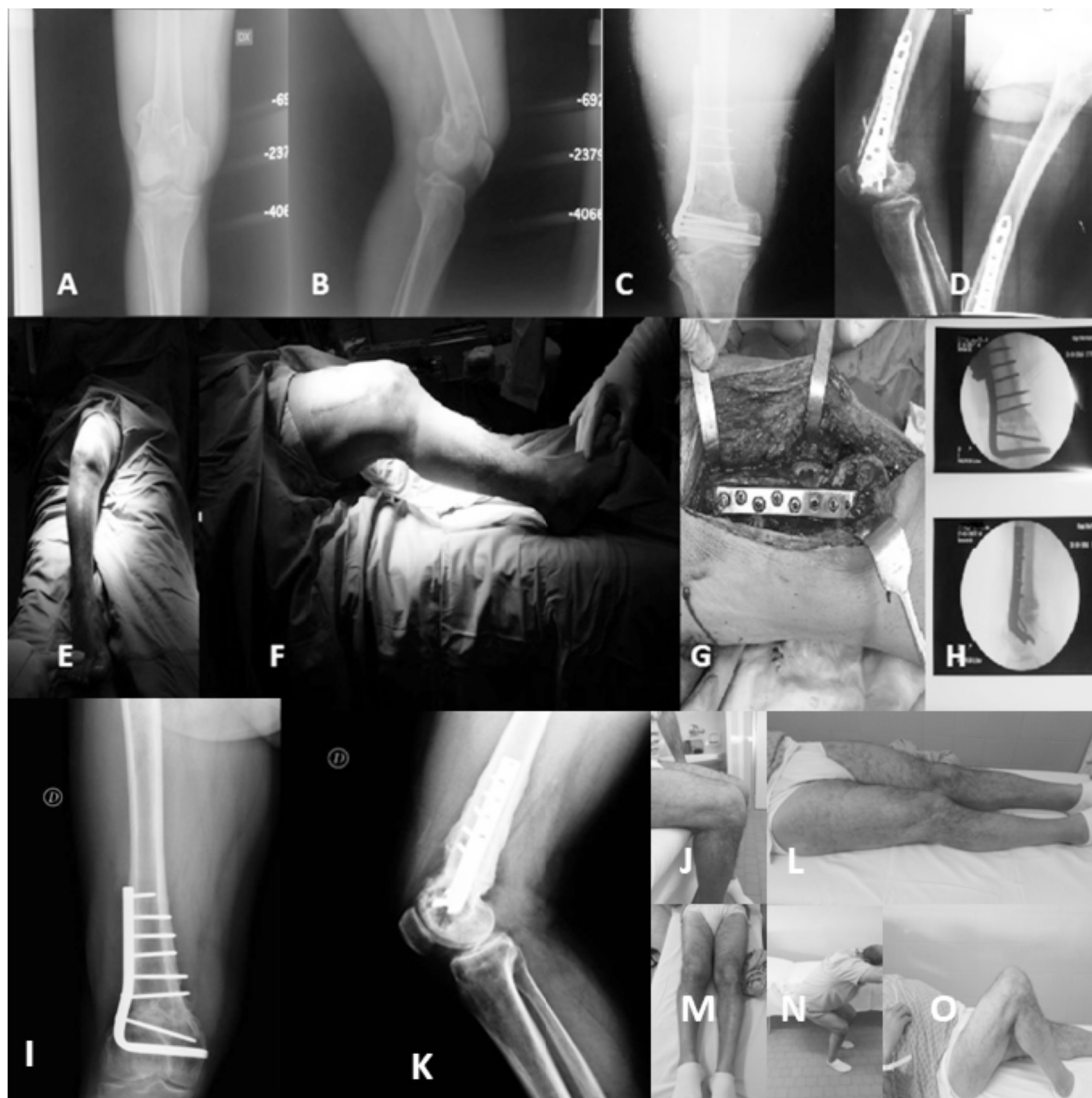


Figure 3. A, B) X-rays of distal femur's supra and intra condylars fracture (33.C1 according AO/OTA) in 47 years old male; C, D) fracture healing in mal union with a plate and screws (LISS) after 12 months after surgical treatment; E, F) the varus and flexion deformity of the injured knee; G) implant of plate blade system; H) X-rays of post-operative; I, K) The X-Rays control after one year from surgery show the perfect alignment and bone healing; J, L, M, N, O) the excellent clinical control after one year from the surgery (Rollo G, 2014)

The NU's average age was 52.5 (range 18-78); the sex ratio was 1.69 in favour of males. All previous fractures were classified according to the AO Classification. The original distal femur fractures were surgically treated and stabilized by plate and screws or plate and cerclage cable or retrograde nail or other various treatments (wires, screws, cerclage, etc.) according to specific surgical indications and surgeon experience.

For 29 (82.86%) patients the first performed surgery was an open reduction and internal fixation (ORIF), while in six (17.14%) patients the first performed surgery was closed reduction and internal fixation (CRIF). The outcomes of fracture reduction and surgical fixation were: 17 (48.57%) bad, 13 (37.14%) sufficient, five (14.29%) good ones (Table 1).

Oligotrophic nonunion was found in 10 (28.57%), while atrophic or avascular nonunion in 25 (71.43%) cases. The Weber-Cech classification was used to classify our nonunion cases (9) (Table 1). The malunion classification of Paley (9) was found not applicable to this group.

We retrospectively used the Non-Union Scoring System (NUSS) (10) to understand and study the type of nonunion. The average point of the Non-Union Scoring System was 63.4 (range 35-72). All the NU's patients had a CT scan of the injured femur performed before the surgery. The average time between the first surgery and breakage of metalwork device was 268.7 days (range 103-363) (Table 1).

The MU average age of the studied population was 48.2 (range 18-80), the sex ratio was 1.75 in favour of males. All previous fractures were classified according to the AO Classification (33.A and 33.C). In 20 (90.90%) patients the first performed surgery was an ORIF while in two (9.10%) patients CRIF was the first surgery. The initially sustained distal femur fractures were stabilized by plate and screws or plate and cerclage cable or retrograde nail or various other procedures (wires, screws, cerclage, etc.). The outcomes of fracture reduction and osteosynthesis were: bad in 13 (59.09%), sufficient in eight (36.36%), good in one (4.55%) case (Table 1).

Type of Non Union according Weber-Cech (9) classification was not found applicable in this group. We divided this group according to the malunion classification of Paley (9) into the following

Table 1. Characteristics of the nonunion (NU) and malunion (MU) populations

Variable	NU	MU
Number of patients	35	22
Average age (years)	52.5	48.2
Range of age (years)	18-78	18-80
Gender (M:F)	22:13	14:8
Male/Female ratio	1.69	1.75
Type of distal femur fracture according AO's Classification (No, %)		
A	16 (45.71)	8 (36.36)
C	19 (54.29)	14 (63.64)
Orthopaedic device used in the surgery for osteosynthesis of the first femoral fracture (No, %)		
Plate and screws	22 (62.86)	16 (72.72)
Plate and cerclage cable	4 (11.43)	1 (4.55)
Retrograde nail	6 (17.14)	2 (9.10)
Various treatment (wires, screws, cerclage, etc)	3 (8.57)	3 (13.63)
Type of reduction and osteosynthesis (No, %)		
Open reduction and internal fixation	29 (82.86)	20 (90.90)
Closed reduction and internal fixation	6 (17.14)	2 (9.10)
Results of reduction and osteosynthesis (No, %)		
Bad	17 (48.57)	13 (59.09)
Sufficient	13 (37.14)	8 (36.36)
Good	5 (14.29)	1 (4.55)
Type of nonunion according Weber-Cech classification (No, %)		
Oligotrophic	10 (28.57)	Not applicable
Atrophic or avascular	25 (71.43)	
Type of mal union according Paley's parameters (No, %)		
Valgus		14 (63.64)
Varus		8 (36.36)
Antecurvation	Not applicable	5 (14.29)
Recurvation		17 (48.57)
Rotational		13 (59.09)
Intraarticular		6 (27.27)
Average point of nonunion scoring system	63.4	38.3
Range of nonunion scoring system	35-72	18-70
Average time after first surgery and breakage of orthopaedic device (days)	268.7	Not applicable
Range time after first surgery and breakage of orthopaedic device (days)	103-363	Not applicable
Average time in days of malunion consolidation after first surgery	Not applicable	236.4
Average time in days of malunion consolidation after first surgery	Not applicable	124-213

subgroups: 14 valgus deformities (63.64%), nine varus deformities (36.36%), five antecurvature deformities (14.29%), 17 recurvate deformities (48.57%), 13 rotational deformities (59.09%), six intra-articular deformities (27.27%).

To understand and study the possibility of union after the malunion's correction surgery we used the NUSS (8) in the retrospective mode. The average point of the Non-Union Scoring System was 38.3 (range 18-70) in MU group. In this group we had no breakage of hardware. All the MU's patients had a CT scan of the affected femur performed before surgery.

Statistical analysis

Descriptive statistics were used to summarize the characteristics of the study group and subgroups, including means and standard deviations of all continuous variables. The t-test was used to compare continuous outcomes. The Chi-square test or Fisher's exact test (in subgroups smaller than 10 patients) were used to compare categorical variables. The statistical significance was defined as $P < 0.05$. We used Pearson correlation coefficient (r) to compare the predictive score of outcomes and quality of life. Mean ages (and their range) of the patients were rounded at the closest year. The predictive score of outcomes and quality of life and their ranges were approximated at the first decimal, while Pearson correlation coefficient (r) was approximated at the second decimal.

RESULTS

Only the value of MU's NUSS was statistically significant ($p < 0.05$) with regards to the comparison between the two populations before the surgery.

The surgery lasted for an average of 141.2 minutes (100-193) in NU group, while an average of 138.3 minutes (range 92-188) in MU group ($p > 0.05$).

The average follow-up was 9.3 years (range 1-17). At X-rays control after surgery there were no any varus collapse noted in the two groups. The NU's X-rays bone healing measured by RUS occurred in our group on average of 260.8 (range 182-283) days after surgery. In MU at X-rays bone healing measured by RUS occurred in 9 on average 242.9 (174-277) days after surgery ($p > 0.05$).

In NU and MU groups, the XR and CT-Scan at one year of follow-up showed the integration of the bone allograft strut and lack of osteolysis areas around hardware. The RUS SCORE was noted to be unchanged throughout the entire follow up. During the follow-up 10 complications in NU and 9 Complications in MU appeared ($p > 0.05$) (Table 2). In MU group one patient died (female, 80 years old, the oldest patient of this group) caused by unresolved deep infection and failure of wound healing after two months from the surgery. Two hardware breakages in NU group were found: 1 proximal screw breakage and 1 distal screw breakage (Table 2). The same complications were found in MU group.

The evaluation of leg length discrepancy was done by clinical and radiological (x-ray) examination at

Table 2. Number and type of complications of the nonunion (NU) and malunion (MU) patients during the follow up

Type of complications	No (%) of the patients in the group		p
	NU (N=35)	MU (N=22)	
Deep infection	0	1 (4.55)	>0.05
Death linked to the surgery	0	1 (4.55)	>0.05
Wound healing after 21 days	2 (5.71)	3 (13.64)	>0.05
Deep vein embolism (DVE)	3 (8.57)	2 (9.09)	>0.05
Hardware breakage	2 (5.71)	2 (9.09)	>0.05
Seroma	1 (2.86)	0	>0.05
Wound hematoma	1 (2.86)	0	>0.05
Superficial skin infection	1 (2.86)	0	>0.05
Total	10 (28.57)	9 (30.30)	>0.05

the following endpoints: before the trauma, after the first surgery, after the revision surgery, at the moment of the union. Only "after the first surgery" group had $p < 0.05$ in favour of the MU group; $p > 0.05$ was noticed in the rest of groups.

In NU group 33 out of 35 patients demonstrated wound healing within 21 days. Two patients exhibited wound dehiscence, which required secondary debridement and suturing under local anaesthesia. In the MU group 20 patients demonstrated wound healing within 21 days. Again in this group one patient exhibited wound dehiscence, which required secondary debridement and suturing under local anaesthesia ($p > 0.05$).

The quality of NU's life before the trauma (measured by SF-12) was 86.4 points (range 66.3-100), while the quality of life before the trauma (measured by SF-12) was 85.9 points (range 64.7-100) in MU group ($p > 0.05$). At the moment of diagnosed nonunion the SF-12 was 22.1 (range 9.3-36.3) in the NU group, while the HHS was 25.3 (range 12.8-42.2) at the moment of malunion in MU group ($p > 0.05$). After 1 month from the revision surgery the SF-12 score was 40.3 (range 22.6-58.7) in NU and 41.9 (range 23.4-58.6) in MU ($p > 0.05$). Thereafter, the SF-12 score was 60.7 in NU (range 44.5-71.3) and 60.4 in MU (range 45.3-72.4) 3 months after the surgery ($p > 0.05$). The same values were recorded at the sixth month of follow-up.

At 6 months from the revision surgery the SF-12 score was 70.3 (range 44.5-92.3) in NU, while it was 70.9 (range 45.3-91.7) in MU group ($p > 0.05$). At twelve months after the surgery SF-12 score in NU was 77.6 (range 44.5-92.3), while in MU group it was 77.4 (range 45.3-91.7) ($p > 0.05$).

A slight increase of the SF-12 score from the 6th to 12th month post revision surgery was recorded. It was found that a better quality of life linked to the

psychological aspects was achievable only in young people, despite shortening of the injured limb.

The NU's functionality of the knee and quality of life before the trauma (measured by KOOS) was 81.6 points (range 63.4-100) in NU group. The same functionality of the knee and quality of life before the trauma (measured by KOOS) was 81.4 points (range 62.8-100) in MU group ($p>0.05$). At the moment of diagnosed nonunion the KOOS was 14.3 points (range 11.3-32.4) in NU, while it was 14.6 (range 11.8-32.9) in MU group ($p>0.05$). There was no statistical significance ($p>0.05$) between the two groups at 1 month follow up after the surgery. The KOOS in NU was 25.4 (range 12.8-42.3) at one month post-op, while it was 25.6 (range 12.8-42.3) in MU group.

At the third month ($p>0.05$ between the two groups) KOOS was 43.6 (range 29.6-66.7) in NU and 44.2 (range 28.3-69.5) in MU group. At 6 months from the revision surgery the KOOS was 68.4 (range 50.2-90.8) in NU, while it was 69.6 (range 50.6-91.2) in MU group ($p>0.05$). At twelve months after the surgery KOOS score was 75.5 (range 50.2-94.3) in NU, while it was 75.4 (range 51.0-95.7) in MU group ($p>0.05$).

The KSS in the two groups reflected the trend of the KOOS. It is interesting to report that at the time of nonunion or malunion, the major functional limitations were represented by stiffness and pain rather than the limping with which the patient could live with providing appropriate supports.

The pre-injury asymmetry of the femurs collected from the patients' medical history showed an average of 0.8 (0-2.5) in the NU group and 0.7 (range 0-2.8) in MU group ($p>0.05$). After the first surgery it was 8.9 cm (4.3-10.7) in NU, and 4.3 cm (2.2-8.5) in MU group with $p<0.05$ in favour of MU. At the time of the fracture site consolidation after the revision surgery it was 3.7 (1.3-6.8) in NU and 3.3 (0.8-6.7) in MU group with $p>0.05$ (Table 3).

Table 3. Average difference between the two limb of the non-union (NU) and malunion (MU) patients before the trauma

Lower limb length: average difference between the two limb (cm)	NU	MU	P
Before the trauma (range)	0.8 (0-2.5)	0.7 (0-2.8)	>0.05
After the first surgery (range)	8.9 (4.3-10.7)	4.3 (2.2-8.5)	<0.05
After the revision surgery (range)	3.7 (1.3-6.8)	3.3 (0.8-6.7)	>0.05
At the moment of the union (range)	3.7 (1.3-6.8)	3.3 (0.8-6.7)	>0.05

DISCUSSION

The results of the surgical treatment of distal femur fractures depend on the restoration of the anatomical axes and the articular surface, which is not always possible, as well as the restoration of normal length with respect to the normal limb and a stable fixation that allows early rehabilitation (11,12). The fixation of these fractures with plates and screws should allow the patient to safely perform active and passive exercises of the knee and without the risk of nonunion or delayed union or incorrect fracture reduction (12,13). Compared to malunion, the nonunion is due to both endogenous and surgical related factors (2,3,14). Post reduction surgery results of these injuries show KOOS indicating predominance of poor results, while average KSS scores indicate good results. The results of the treatment were significantly affected by pain and limited mobility (13). These symptoms are emphasized both in the nonunion and malunion (14). As shown by the NUSS score (10), there is no doubt that the malunion group had a greater capacity for re-consolidation after revision surgery compared to the nonunion group. Before approaching revision surgery patient assessment and an appropriate preoperative planning should always be made (2). The following questions should be asked: why did not the fracture heal or why it did not consolidate? Is there an inadequate synthesis or a biological problem? Is there a recognized infection? Radiographic evaluation should include appropriate plain films capable of assessing deformity and condition of the joints above and below the fracture. If the deformity exists, orthostatic radiographs should also be performed, along with CT scans that are able to assess and predict the lack of bone consolidation. CT scans may also allow assessment of rotational and axial malalignments. The CT scan is able to accurately assess the heterometry of the lower limbs. The surgical approach used in the intervention of revision in nonunion and malunion groups does not aim at re-incising on the previous surgical approach, but to preserve the blood supply (15), the integrity of the vastus lateralis (17) and to perform a modified Judet approach above all (17,18,19) for an early functional recovery and optimization of the recovery time (19-20). In order to respect the biomechanics at the level of

metaphyseal or diaphyseal nonunions or while performing corrective osteotomy (9,22) it was decided to opt for the bio-metallic solution. It has been shown in the international literature (23,24) on the treatment of periprosthetic hip fractures that a bone splint, opposed to a metal plate, increases the mechanical strength of the femur by 2250N (23). Furthermore, the bone splint not only has a positive mechanical effect but it has revealed to be a stimulus for the consolidation of the fracture (22). The choice of the blade plate can be explained by the fact that its construct reaches greater rigidity compared to the average values obtained with the use of Locking Plate with regards to compression and torsion on axial loads (24). Moreover, it has been shown to be superior during bending tests with respect to the dynamic condylar screws (25). The use of morselized bone and allograft to fill the bone defect in nonunion and malunion should be taken into consideration (26).

Paradoxically the point of nonunion can be equivalent to the centre of rotation of angulation (CORA) in nonunion. In some cases the angle and the displacement of the CORA may have an additive effect, while in other cases a slight deformation of the limb (compensated by the bone trabecula dynamically realigning precisely in relation to changes in the direction of the peak load) can be noted. This indicates that Wolff's law is not only accurate, but also very sensitive (9,27). In addition, an incorrect three-dimensional correction of the distal femur can cause a misalignment of the physiological mechanical axis of the tibia (MAD), which normally runs from 0 to 8 mm medial to the centre of the knee (9). Our technique has been implemented in compliance with the algorithm of Dymond concept conceived by Giannoudis (28), but we relied on the capacity of bone healing and mechanical factors (10,27).

Moreover, the experience of our latest work (29,30) on nonunions of subtrochanteric fractures (difficult to resolve) treated with intramedullary nail shows how the combination of the lateral blade plate and the medial bone splint is the winning choice for bone consolidation. This is demonstrated by our bone healing and RUS results.

Our study shows that in elderly patients we had poor functional outcomes and few complications that led to death in one case. In young patients we

had a good functional recovery but we did not achieve full recovery. However, this was due to the impact that previous surgeries and type of disease had on functional outcomes (12,13). Despite the asymmetry of the limbs all patients decided not to undergo additional surgery to equalize the length of the limbs. Orthosis was the preferred solution. The reasons for the refusal given by the patients were related to the length of the necessary recovery time and possible complications caused by further surgery or the refusal to the shortening of the other healthy limb.

Nowadays the extraordinary improvement of prosthetic implants and the modularity of tumoral prosthesis allow better treatment of nonunions and nonunions of knee prosthesis compared to the past (12). However, many authors concluded that the total replacement of the distal femur with modular prosthesis is an important option in the reconstitution from a functional point of view of the lower limbs after complex fractures and post-trauma results with high bone loss. But the same authors brought to light the disastrous complications that these patients could face (12,13). Therefore, distal femur replacement must be considered as an option, but after having considered all other possible options and factors related to the patients.

Distal femur replacement in young patients cannot be considered as a feasible option, while in the elderly it is better to wait for appropriate healing of the malunions and nonunions sites and then implant a simple prosthesis from a revision knee replacement (26).

The limitations of the current study were the limited number of patients, non-probability sample of convenience due to few centric samples, Level 1 Trauma Center. Being a retrospective study could be considered as another limit. Disadvantages of retrospective studies: inferior level of evidence compared with prospective studies; subject to confounding (other risk factors may be present that were not measured); inability to determine causation, only association; some key statistics cannot be measured. Selection of patients may be biased, making generalization of results difficult. It may be unclear whether the confluence of findings is merely a chance occurrence or is truly characteristic of a new disease or syndrome. Another limitation was that the measurements and interventions were made without randomiza-

tion of the researcher to the experimental groups, which have potential for bias. Finally other limiting factors of the study acknowledged by the authors may include the potential for regression to the mean, the presence of temporal confounders and the mention of subjective score.

In conclusion, nonunion and malunion are two different pathologies but united by very bad outcomes that reduce the patient's quality of life. From our data and from what is present in the literature, a functional "*restitutio ad integrum*"

is possible. The role of bio-metallic solution in the treatment of nonunions and malunions is to recreate a knee anatomy and functionality compatible with a satisfactory quality of life.

FUNDING

No specific funding was received for this study.

TRANSPARENCY DECLARATION

Conflicts of interest: None to declare.

REFERENCES

1. Zlowodzki M, Bhandari M, Marek DJ, Cole PA, Kregor PJ. Operative treatment of acute distal femur fractures: systematic review of 2 comparative studies and 45 case series (1989 to 2005). *J Orthop Trauma* 2006; 20:366-71.
 2. Chan DB, Jeffcoat DM, Lorch DG, Helfet DL. Nonunions around the knee joint. *Int Orthop* 2010; 34:271-81.
 3. Gangavalli AK, Nwachuku CO. Management of distal femur fractures in adults: an overview of options. *Orthop Clin North Am*: 2016; 47:85-96.
 4. Agrawal A, Kiyawat V. Complex AO type C3 distal femur fractures: results after fixation with a lateral locked plate using modified swashbuckler approach. *Indian J Orthop* 2017; 51:18-27.
 5. Wu CC. A novel approach for evaluating acceptable intra-operative correction of lower limb alignment in femoral and tibial malunion using the deviation angle of the normal contralateral knee. *Knee*: 2014; 21:573-81.
 6. Fracture and dislocation compendium. Orthopaedic Trauma Association Committee for Coding and Classification. *J Orthop Trauma* 1996; 10(Suppl 1):1-154.
 7. Lizaur-Utrilla A, Miralles-Muñoz FA, Sanz-Reig J. Functional outcome of total knee arthroplasty after periprosthetic distal femoral fracture. *J Arthroplasty* 2013;28(9):1585-8.
 8. Kessler S, Lang S, Puhl W, Stöve J. The Knee Injury and Osteoarthritis Outcome Score--a multifunctional questionnaire to measure outcome in knee arthroplasty. *Z Orthop Ihre Grenzgeb* 2003; 141:277-82.
 9. Litrenta J, Tornetta P 3rd, Mehta S, Jones C, O'Toole RV, Bhandari M, Kottmeier S, Ostrum R, Egol K, Ricci W, Schemitsch E, Horwitz D. Determination of radiographic healing: an assessment of consistency using RUST and modified RUST in metadiaphyseal fractures. *J Orthop Trauma* 2015; 29:516-20.
 10. Paley D. Normal lower limb alignment and joint orientation. In: Paley D, Herzenberg JE, editors. *Principles of Deformity Correction*. 2nd ed. New York: Springer, 2003; 1-18.
 11. Calori GM, Colombo M, Mazza EL, Mazzola S, Malagoli E, Marelli N, Corradi A. Validation of the Non-Union Scoring System in 300 long bone nonunions. *Injury* 2014; 45 (Suppl 6):S93-7.
 12. Fakler JK, Hepp P, Marquäß B, von Dercks N, Josten C. Is distal femoral replacement an adequate therapeutic option after complex fractures of the distal femur?. *Z Orthop Unfall* 2013; 151:173-9.
 13. Pakula G, Kwiatkowski K, Kuczmera P, Fudalej P. Assessment of outcomes of treatment of fractures of distal femur with a locking plate taking into account factors influencing the result. *Ortop Traumatol Rehabil* 2015; 17:501-11.
 14. Ehlinger M, Ducrot G, Adam P, Bonnet F. Distal femur fractures. Surgical techniques and a review of the literature. *Orthop Traumatol Surg Res* 2013; 99:353-60.
 15. Bertrand ML, Andrés-Cano P, Pascual-López FJ. Periarticular fractures of the knee in polytrauma patients. *Open Orthop J* 2015; 9:332-46.
 16. Link BC, Babst R. Current concepts in fractures of the distal femur. *Acta Chir Orthop Traumatol Cech* 2012; 79:11-20.
 17. Holschen M, Lobenhoffer P. Treatment of extension contracture of the knee by quadriceps plasty (Judet procedure). *Oper Orthop Traumatol* 2014; 26:353-60.
 18. Mahran M, El Batrawy Y, Sala F, Al Kersh M. Quadricepsplasty: a sustained functional achievement in front of a deteriorated flexion gain. *Injury* 2014; 45:1643-7.
 19. Liu SH, Cui ZG, Han XZ, Liu KM, Wang AQ. The therapeutic effect analysis of three kinds of methods for the management of post traumatic knee stiffness. *Zhonghua Wai Ke Za Zhi* 2012; 50:84-7.
 20. Oliveira VG, D'Elia LF, Tirico LE, Gobbi RG, Pecora JR, Camanho GL, Angelini FJ, Demange MK. Judet quadricepsplasty in the treatment of posttraumatic knee rigidity: long-term outcomes of 45 cases. *J Trauma Acute Care Surg* 2012; 72:E77-80.
 21. Ebrahimzadeh MH, Birjandi-Nejad A, Ghorbani S, Khorasani MR. A modified Thompson quadricepsplasty for extension contracture resulting from femoral and periarticular knee fractures. *J Trauma* 2010; 68:1471-5.
 22. van der Woude JA, Spruijt S, van Ginneken BT, van Heerwaarden RJ. Distal femoral valgus osteotomy: bone healing time in single plane and biplanar technique. *Strategies Trauma Limb Reconstr* 2016; 11:177-86.
-

23. Carta S, Fortina M, Riva A, Meccariello L, Manzi M, Di Giovanni A, Ferrata P. The biological metallic versus metallic solution in treating periprosthetic femoral fractures: outcome assessment. *Adv Med* 2016; 2016:2918735.
 24. Peters CL, Bachus KN, Davitt JS. Fixation of periprosthetic femur fractures: a biomechanical analysis comparing cortical strut allograft plates and conventional metal plates. *Orthopedics* 2003; 26:695-9.
 25. Batista BB, Volpon JB, Shimano AC, Kfuri M Jr. Varization open-wedge osteotomy of the distal femur: comparison between locking plate and angle blade plate constructs. *Knee Surg Sports Traumatol Arthrosc* 2015; 23:2202-7.
 26. Percope Andrade MA, Rodrigues AS, Mendonça CJ, Santos Portela LG. Fixation of supracondylar femoral fractures: a biomechanical analysis comparing 95° blade plates and dynamic condylar screws (dcs). *Rev Bras Ortop* 2015; 45:84-8.
 27. Buck B, Murtha YM. The management of bone defects in periarticular knee injuries: a review article. *J Knee Surg* 2017; 30:194-9.
 28. Barak MM, Lieberman DE, Hublin JJ. A Wolff in sheep's clothing: trabecular bone adaptation in response to changes in joint loading orientation. *Bone* 2011; 49:1141-51.
 29. Calori GM, Giannoudis PV. Enhancement of fracture healing with the diamond concept: the role of the biological chamber. *Injury* 2011; 42:1191-3.
 30. Rollo G, Tartaglia N, Falzarano G, Pichierri P, Stasi A, Medici A, Meccariello L. The challenge of nonunion in subtrochanteric fractures with breakage of intramedullary nail: evaluation of outcomes in surgery revision with angled blade plate and allograft bone strut. *Eur J Trauma Emerg Surg* 2017; 43:853-61.
 31. Schep NW, van Lieshout EM, Patka P, Vogels LM. Long-term functional and quality of life assessment following post-traumatic distraction osteogenesis of the lower limb. *Strategies Trauma Limb Reconstr* 2009; 4:107-12.
-