

# Comparison of dexmedetomidine alone or with other sedatives for paediatric sedation during magnetic resonance imaging: a systematic review

Rudy Vitraludyono<sup>1</sup>, Arie Utariani<sup>2</sup>, Elizeus Hanindito<sup>2</sup>

<sup>1</sup>Department of Anaesthesiology and Reanimation, <sup>2</sup>Consultant of Paediatric Anaesthesia, Department of Anaesthesiology and Reanimation; Faculty of Medicine, Airlangga University/ Dr. Soetomo General Hospital, Surabaya, Indonesia

## ABSTRACT

**Aim** To compare the outcome of sole dexmedetomidine or with other sedative drugs in paediatric patients during magnetic resonance imaging (MRI).

**Methods** Literature was obtained from PubMed and Science-Direct from 2010-2020 using key words: sedation, paediatric, dexmedetomidine, ambulatory, MRI, ketamine, propofol, midazolam. The literature selection was based on Participant, Intervention, Comparators, Outcomes (PICO) analysis. All English full-text and peer-reviewed articles were included. The primary outcome was hemodynamic stability, respiratory compromise, and recovery time. The risk of bias analysis was assessed using Cochrane collaboration Risk of Bias (RoB 2.0).

**Result** Of 106 studies, 17 studies were included with a total 3.430 paediatric patients undergoing MRI. Dexmedetomidine alone provides a more stable hemodynamic but longer recovery time than ketamine, propofol or midazolam. The combination of dexmedetomidine and ketamine provides more stable hemodynamics, especially in the incidence of hypotension and bradycardia, and does not significantly reduce airway configuration more than sole dexmedetomidine or ketamine. Intranasal dexmedetomidine is more recommended than its combination with midazolam. Combining dexmedetomidine with ketamine, propofol or midazolam provides a shorter recovery time.

**Conclusion** A combination of dexmedetomidine with other sedatives such as ketamine, propofol and midazolam is better than sole dexmedetomidine for paediatric sedation during magnetic resonance imaging.

**Key words:** anaesthesia, ketamine, midazolam, propofol

## Corresponding author:

Rudy Vitraludyono

Department of Anaesthesiology and Reanimation, Faculty of Medicine, Airlangga University/Dr. Soetomo General Hospital

Jl. Jaksa Agung Suprpto no.2 Malang, Surabaya, East Java, Indonesia

Phone: +62 85 2313 97 700;

E-mail: dinoanestesi@ub.ac.id

ORCID ID: <https://orcid.org/0000-0002-3783-7029>

## Original submission:

26 August 2022;

## Revised submission:

19 September 2022;

## Accepted:

20 October 2022

doi: 10.17392/1532-22

## INTRODUCTION

In paediatrics discomfort is mainly felt during invasive and non-invasive medical procedures. Pain becomes the main complaint in an emergency condition. Because of that, sedation has become essential in paediatric management. Sedation is also commonly used in imaging, such as magnetic resonance imaging (MRI), computed tomography or echocardiography to ensure patients remain calm and still (1-3).

MRI is a diagnostic tool often used to visualize precise tissue differentiation using a magnetic field (4). The patients movement must be under control to provide a good quality image. In paediatrics this procedure is challenging because sometimes paediatric patients cannot cooperate (3).

The American College of Emergency Physicians (ACEP) has defined Procedural Sedation and Analgesia (PSA) as a technique in administering sedative or dissociative agents with or without analgesic to induce a state that allows the patient to tolerate unpleasant procedures while maintaining cardiorespiratory function (5). The aim of this procedure is different in adults because, in paediatrics this procedure controls the behaviour and keeps the patient cooperative during the procedure. Sedation also aims to provide patient safety, minimize discomfort, anxiety and physiological trauma (6). However, in cooperative paediatric patients, non-pharmacological modality might help reduce the need for sedatives (5). Before sedation, it needs to be considered whether the procedure will provoke pain or not. If the pain is not adequately managed, the physiological and behavioural response will affect long-term nociceptive developments in paediatric patients (7).

There are several sedation modalities for MRI. The most common sedation includes inhalation and intravenous sedation. Some intravenous sedatives are often used such as propofol, ketamine, chloral hydrate and dexmedetomidine. Sevoflurane is commonly used in inhalation sedation (8). In 2005 studies related to dexmedetomidine as premedication in paediatrics during MRI emerged. Dexmedetomidine is less frequently used causing respiratory depression. However, dexmedetomidine potentially causes cardiovascular depression and must be put into consid-

eration. Dexmedetomidine dose-dependent potentially lowers blood pressure through adrenergic alpha-2 receptor agonists in the sympathetic ganglion. Besides, dexmedetomidine also needs more prolonged onset (9).

The aim of this study was to compare the outcome of sole dexmedetomidine and a combination of dexmedetomidine with other sedative drugs in paediatrics during magnetic resonance imaging (MRI).

## MATERIALS AND METHODS

### Materials and study design

This systematic review was done in the Department of Anaesthesiology and Reanimation, Faculty of Medicine, Airlangga University /Dr. Soetomo Hospital Surabaya, Indonesia, in the period December 2021-January 2022. The Preferred Reporting Items for Systematic Reviews and Meta-analyses (PRISMA) method was used to analyse current evidence from studies comparing the sedative effect of dexmedetomidine versus the combination of dexmedetomidine with ketamine, propofol, midazolam in paediatric patients undergoing magnetic resonance imaging (MRI). Article searches were conducted on PubMed and ScienceDirect, using key words sedation, pediatric, dexmedetomidine, ambulatory, MRI, ketamine, propofol and midazolam.

### Methods

The selection criteria used the Participant, Intervention, Comparators, Outcomes (PICO) framework. Participants: research subjects were paediatric patients aged 1 day – 18 years who underwent a magnetic resonance imaging (MRI) procedure with sedation. Intervention: subjects received sedation between dexmedetomidine and dexmedetomidine combined with ketamine, propofol and midazolam. Comparator: paediatric patients undergoing MRI using sedative sole dexmedetomidine compared with subjects sedated with a combination of dexmedetomidine with ketamine, propofol, midazolam. Outcome: paediatric hemodynamics (blood pressure and pulse rate), the occurrence of respiratory depression, recovery time. All full-text peer-reviewed studies comparing sedation outcomes using dexmedetomidine and other sedatives in paediatric patients

age 1 day – 18-year were included. The articles were only in English. Abstracts and conference proceedings were excluded. Research articles that met the inclusion criteria for evaluation were determined based on the evidence-based level on categories from the National Health and Medical Research Council (NHMRC). For RCT research, quality and risk of bias were assessed using the Cochrane Collaboration Risk of Bias (RoB 2.0) (10). The final assessment was scored as follows: low risk of bias, moderate risk of bias/multiple considerations and high risk of bias, as described in the Cochrane manual (10). For case studies with a control group, quality and risk assessments were done using guidelines from The National Institutes of Health (NIH) quality assessment tool for case-series studies (Interventional) (11), while case studies without comparisons for control groups used guidelines from The National Institutes of Health (NIH) quality assessment tool for before-after (pre-post) study with no control group (11). The final assessment was scored as good, moderate and poor. For case reports, there are no guidelines for assessing quality reports.

Articles were managed using the Mendeley reference processor (version 1083). The articles were identified based on the evaluation of titles and abstracts. After screening for duplicate articles, the full text of the articles was finalized for eligibility for inclusion in the study. After screening, feasibility, quality assessment and risk of bias, data extraction from all selected articles was carried out, and important findings from the article were written based on the data extraction process. Data extraction includes: general characteristics of the study design and level of evidence according to NHMRC, study group, type of surgery, number of samples and baseline characteristics of the study samples; quality and risk of bias from research articles; assessment of the outcomes - hemodynamics (blood pressure and pulse rate of paediatric patients), the occurrence of respiratory depression, recovery time.

## RESULTS

From the flow chart of systematic review, 106 potential studies were obtained. After the screening of duplicate articles, titles and abstracts, 66 studies were excluded due to duplication and did not meet the inclusion criteria. From the rest of

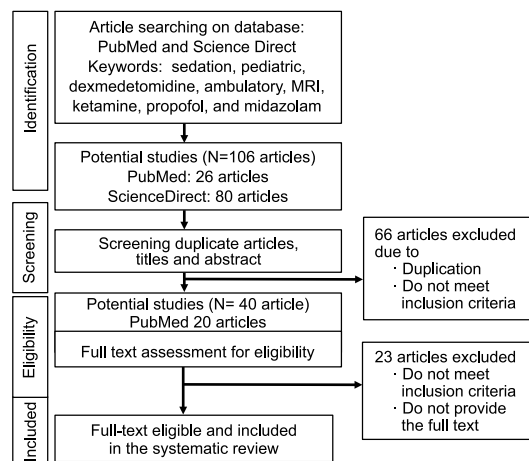


Figure 1. PRISMA diagram of systematic review

potential studies (N=40), full text screening found that 23 studies did not meet the inclusion criteria and did not provide full text. Therefore, 17 studies met the criteria and were further investigated with the total number of research subjects, 3,430 paediatric patients (Figure 1). The studies consisted of retrospective studies, retrospective reviews, systematic reviews, prospective studies, randomized controlled studies, and non-randomized controlled studies.

Olgun et al. (12), showed that the success rate of sedation using intranasal dexmedetomidine was 96.2%. The median effective dose (ED50) of intranasal dexmedetomidine increases with age for the first three years of life. Intranasal dexmedetomidine and intravenous ketamine may be the best choices as sedative agents in children with risk factors for alpha-mannosidosis (12). There have been several comparative studies between dexmedetomidine and its combination with other sedatives. Intranasal dexmedetomidine is better at reducing anxiety and produces a higher level of sedation at the time of induction than intranasal midazolam (13). However, a retrospective review of 244 paediatric patients showed that intranasal dexmedetomidine combined with midazolam was an effective regimen for sedation (14). Buccal dexmedetomidine with or without midazolam provides adequate sedation with minimal side effects but has a failure rate of almost 20% (15). Low-dose dexmedetomidine bolus (0.5 mcg/kg) can be used as an adjuvant to reduce the need for propofol in sedation (16). Combination of dexmedetomidine and ketamine superior to ketamine and dexmedetomidine alone (17).

Several studies discussed the hemodynamic changes in using different sedatives in paediatric patients who underwent MRI. In general, dexmedetomidine is better in maintaining hemodynamics than other sedatives. Abulebda et al. (18) stated that dexmedetomidine has more stable hemodynamics than propofol. However, dexmedetomidine has a longer recovery time (19). Research by Eldeek et

al. (20) and Tammam et al. (17) stated that dexmedetomidine provides adequate sedation in most children without hemodynamic disturbances compared to ketamine. Meanwhile, the combination of ketamine and dexmedetomidine did not cause significant hemodynamic changes (21) (Table 1).

The use of dexmedetomidine alone or in combination with other sedatives did not cause significant

**Table 1. The sedative effect of dexmedetomidine compared to the combination of dexmedetomidine with ketamine, propofol and midazolam on blood pressure and pulse rate**

References	Research design, sample size, variables, statistical analysis	Outcome			
		Dose	Airway configuration	Hemodynamic	Recovery time
Abulebda et al. (18)	Design: Retrospective review Sample: 105 paediatric patients (Group D 56 subjects, Group P 49 subjects) Variables: demographics, hemodynamic changes, sedation time Statistical analysis: T-test, Wilcoxon test, ANOVA	IV Propofol 1 mg/kg (maximum of 50 mg), followed by continuous infusion of 83 mcg/kg/min IV Dexmedetomidine 2 mcg/kg 10 minutes followed by maintenance infusion of 1 mcg/kg/h	NA	Dexmedetomidine is better in maintaining stable hemodynamics than propofol	NA
Mylavarapu et al.(21)	Design: a prospective study Sample: 25 paediatric patients Variables: demographic characteristics, hemodynamics, outcomes Statistical analysis: paired t-test, Wilcoxon signed-rank test, descriptive statistics, linear mixed-effect models	IV Dexmedetomidine 2 mcg for 10 min followed by dexmedetomidine infusion 2 mcg/kg/h IV Ketamine 2 mg/kg	Ketamine after dexmedetomidine did not significantly decrease upper airway configuration compared to dexmedetomidine alone.	No hemodynamic changes	NA
Ahmed et al.(19)	Design: a retrospective review Sample: 966 patients (Group D 544 patients received dexmedetomidine) group P 452 patients received propofol) Variables: heart rate, respiration rate, blood pressure, oxygen saturation Statistical analysis: Student t-test, Mann-Whitney rank-sum test, Fisher exact test	IV Dexmedetomidine 2 mcg/kg over 10 minutes followed by infusion of 1 mcg/kg/h IV Propofol 2 mg/kg over 2 minutes followed by infusion of 83 mcg/kg/minutes	NA	Dexmedetomidine provides stable hemodynamics	Dexmedetomidine has longer recovery time Propofol has a faster onset and recovery time.
Gupta et al.(26)	Design: a double-randomized prospective study Sample: 60 paediatric patients (Group D 30 subjects, Group M 30 subjects) Variables: demographics, parental separation, hemodynamics, sedation level, median sedation Statistical analysis: unpaired t-test, paired t-test, $\chi^2$	IN Dexmedetomidine 1 mcg/kg IN Midazolam 0.2 mg/kg	NA	Intranasal dexmedetomidine maintains better hemodynamics	NA
Eldeek et al. (20)	Design: Randomized prospective trial Sample: 110 paediatric patients (group D 55 subjects, group K 55 subjects) Variables: sedative, hemodynamic, respiratory effects, and complications. Statistical analysis: one-tailed test, ANOVA, t-test $\chi^2$ test	IV Dexmedetomidine 1 mcg/kg followed by continuous infusion of 0.5-0.75 mcg/kg/h IV Ketamine 1mg/kg followed by continuous infusion 10-15 mcg/kg/min	Dexmedetomidine provide no respiratory compromise	Dexmedetomidine provide no hemodynamics change	NA
Tammam et al. (17)	Design: a blinded randomized comparison study Sample: 162 children (group D 54 subjects, group K 54, group DK 54 subjects) Variables: section onset, sedation failure rate, hemodynamic stability Statistical analysis: One-way ANOVA, Pearson, and $\chi^2$ tests	IM Dexmedetomidine 3 mcg/kg IM Ketamine 4 mg/kg Dexmedetomidine 1.5 mcg/kg + ketamine 2 mg/kg	NA	Dexmedetomidine and ketamine combination has more stable hemodynamics than ketamine or dexmedetomidine alone	NA

NA, not applicable; IV, intravenous; IM, intramuscular; IN, intranasal

**Table 1. (continued) The sedative effect of dexmedetomidine compared to the combination of dexmedetomidine with ketamine, propofol and midazolam on blood pressure and pulse rate**

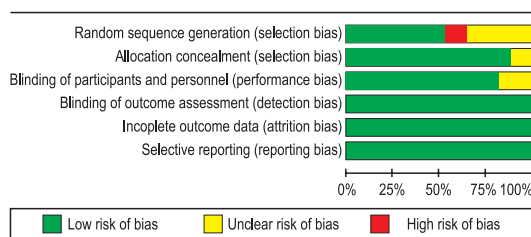
References	Research design, sample size, variables, statistical analysis	Outcome			
		Dose	Airway configuration	Hemodynamic	Recovery time
Mahmoud et al. (22)	Design: a prospective, single-blind, controlled comparative study Sample: 60 patients (Dex group 30, Propofol group 30) Variable: Airway morphology Analysis: Wilcoxon sum-rank test, two-sample t-test, Wilcoxon test, ANOVA	IV Dexmedetomidine Low 1 mcg/kg/h; High 3 mcg/kg/h  IV Propofol Low 100 mcg/kg/min. High 200 mcg/kg/min	Both Dexmedetomidine and Propofol have no significant change in airway dimensions	NA	NA
Watt et al. (23)	Design: Randomized controlled blind study Sample: 40 children Variables: demographics, procedure time, cine measurements, anaesthetic level, spoiled chart airway volume measurements diet (SPGR) Analysis: Paired and unpaired t-test, Wilcoxon test, Mann Whitney test, ANOVA test	IV Dexmedetomidine 1 mcg/kg 10 minutes followed by infusion of 0.1 mg/kg midazolam (IV), then dexmedetomidine infusion 1 mcg/kg/h continued  IV Propofol 300 mcg/kg/min for 10 minutes, reduced to 250 mcg/kg/min	There was no difference in airway collapse between sedation with dexmedetomidine and propofol after sevoflurane induction.	NA	NA
Tang et al. (24)	Design: a systematic review Sample: 6 randomized controlled trials (415 paediatric patients) Variables: recovery time, patient discharge time, failure of sedation, desaturation, Pediatric Anesthesia Emergence Delirium scale (PAED) Statistical analysis: PRISMA	Propofol 300 mcg/kg/min – 3 mg/kg IV Dexmedetomidine 0.3 – 2 mcg/kg	NA	NA	Propofol has a shorter recovery time and faster induction of sedation than dexmedetomidine
Zhou et al. (25)	Design: a systematic review Sample: 6 studies with 368 subjects Variables: sedation onset, recovery time, sedation time, MRI time, MRI quality, PAED Statistical analysis: PRISMA and meta-analysis	IV Propofol 3 mg/kg initial dose followed by 100 mcg/kg/min continuous infusion of mean dose 97.9 mcg/kg/h 2 mg/kg and followed by continuous infusion of 200 mcg/kg/min a single dose of 1 mg/kg infusion at 300 ug/kg/min for 10 mins and reduced to 250 mcg/kg/min 1 mg/kg bolus followed by continuous infusion of 100 ug/kg/min IV Dexmedetomidine. 1 mcg/kg initial dose followed by continuous infusion of 0.5 ug/kg/h continuous infusion of mean dose 1.8 ug/kg/h 2 mcg/kg followed by continuous infusion of 2 mcg/kg/h single dose of 0.3 mcg/kg 1 mcg/kg followed by 1 mcg/kg/h infusion 2 mcg/kg for 10min followed by continuous infusion of 1 mcg/kg/h	NA	NA	Propofol has faster onset and recovery time than dexmedetomidine
Balasubramanian et al. (13)	Design: Non-randomized controlled study Sample: 88 patients received initiation, 35 patients received dexmedetomidine, 38 patients received propofol, 15 did not receive the drug Variables: Demographics, the success rate of MRI, quality of MRI, continuity of MRI, side effects, recovery time, and duration of treatment Statistical analysis: $\chi^2$ test, ANOVA, unpaired t-test, Kruskal-Wallis, and Mann Whitney	IV Dexmedetomidine 1 mcg/kg for 10 minutes IV ketamine 1 mg/kg IV propofol 1 mg/kg	NA	NA	Propofol has faster recovery time than dexmedetomidine and ketamine

NA, not applicable; IV, intravenous; IM, intramuscular; IN, intranasal

changes in airway configuration. Mylavarapu et al. (21) found that adding ketamine after dexmedetomidine did not significantly decrease the airway configuration compared to dexmedetomidine alone. Mahmoud et al. study (22) also stated that the use of dexmedetomidine or propofol did not cause changes in airway configuration in patients with history of obstructive sleep apnoea (OSA). The study of Watt et al. (23) stated no difference in airway between sedation using dexmedetomidine and propofol after sevoflurane induction (Table 1, 2).

Propofol has a shorter recovery time than dexmedetomidine or ketamine. Ahmed et al. (19) found that propofol has a faster onset and recovery time than dexmedetomidine. Tang et al. (24) and Balasubramanian et al. (13) found that trial sequential analysis (TSA) recommended propofol over dexmedetomidine because of shorter recovery time and faster onset. Propofol is recommended for paediatric patients undergoing MRI because it has a better sedative effect, faster onset and recovery time, also lower side effects of delirium than dexmedetomidine (25) (Table 1).

An analysis of potential bias found that no articles had potential bias on selective reporting points, incomplete outcome data and blinding of outcome assessment. More than 75% of the studies did not have the potential for bias on the points of allocation concealment and blinding of participants and personnel. As many as 50% of the studies had no potential for random sequence generation bias, and 12.5% had a high potential for bias (Figure 2). The limitation of this study is that there was no meta-analysis of the outcome. Further meta-analyses might be done as the continuity of this study.



**Figure 2. Risk of bias: review of authors' judgements about each bias risk item presented as percentages across all included studies**

## DISCUSSION

Procedural sedation and analgesia (PSA) as premedication in paediatrics before undergoing MRI examination has several side effects and risks.

Monitoring is needed, especially in hemodynamic stability, respiratory depression and recovery time. Several sedatives prescribed for PSA include propofol, ketamine, chloralhydrate, and dexmedetomidine in paediatrics (16).

In this systematic review, dexmedetomidine was able to maintain hemodynamic stability in paediatric patients. Studies conducted by Abulebda et al. (18) and Ahmed et al. (19) stated that dexmedetomidine could maintain hemodynamic stability better than propofol. A retrospective review by Ahmed et al. (19) found that hypotension and bradycardia were more common in the propofol group.

There was no significant difference in hemodynamics between dexmedetomidine and midazolam (24). The level of sedation of intranasal dexmedetomidine is higher than midazolam, thus giving the patient more peace when separated from their parents; 80% of patients in the dexmedetomidine group achieved satisfactory sedation (OAA/S score > 4) (26).

The use of ketamine provokes some adverse events, including nausea, vomiting and dysphoria (18). However, the combination of dexmedetomidine (1.5 mg/kg) and ketamine (2 mg/kg) intramuscularly gives better results in terms of hemodynamic stability (16). Based on the result, dexmedetomidine is the best choice over propofol, midazolam and ketamine in terms of hemodynamic stability (16-18, 24).

Intravenous dexmedetomidine administration has a high incidence of hemodynamic instability and a high rate of sedation failures, also requires additional supplemental sedation (IV midazolam titration 0.05mg/kg every 4 minutes) (16). The intramuscular administration has been shown to provide better hemodynamic stability even though the onset of sedation is lower than the intravascular administration (16). Intranasal administration can be used as an alternative to MRI premedication because it does not significantly affect hemodynamics. In addition, intranasal sedation is non-invasive and easy to perform (26) and can be used as an option for sedation in paediatrics with alpha-mannosidosis (27). The median effective dose (ED50) of intranasal dexmedetomidine includes: 0.4 mg/kg in children 1-6 months of age, 0.5 mg/kg at 7-12 months of age, 0.9 mg/kg at 13-24 months of age, and 1.0 mg/kg in children aged 24-

36 months (28). Meanwhile, according to Sulton et al. (14) a dose of 3 mg/kg intranasal dexmedetomidine is recommended for paediatric patients aged 14 months, and the study of Olgun and Ali (12) stated that at a dose of 4 mg/kg dexmedetomidine is effective in paediatric patients under one year of age. In school-aged children, the buccal route is preferred over the intranasal route. Dexmedetomidine given by the buccal route with or without the addition of oral midazolam does not cause serious adverse events, but the percentage of failure reaches 20% (15).

There is no significant respiratory depression in paediatric patients who receive propofol or dexmedetomidine who were previously given inhaled sevoflurane (20). In obstructive sleep apnoea patients undergoing sedation using dexmedetomidine or propofol, upper airway morphology did not experience significant changes. However, Mahmoud et al. (22) showed that 23% of paediatric patients in the propofol group required additional airway support. The administration of dexmedetomidine alone or the combination of dexmedetomidine and ketamine in paediatric patients undergoing general anaesthesia did not cause a significant difference in the upper airway diameter (19).

The comparison of dexmedetomidine and propofol shows that propofol has a faster onset than dexmedetomidine (22). Ahmed et al. (19) also showed that dexmedetomidine onset was longer ( $13.6 \pm 4.58$  minutes) than propofol ( $2.0 \pm 0.00$  minutes). Dexmedetomidine needs a longer induction duration due to the slow infusion rate (more than 10 minutes) to avoid unwanted hemodynamic impairment. Dexmedetomidine has a longer discharge time (92 minutes) than the propofol group (37 minutes).

## REFERENCES

1. Tervonen M, Pokka T, Kallio M, Peltoniemi O. Systematic review and meta-analysis found that intranasal dexmedetomidine was a safe and effective sedative drug during paediatric procedural sedation. *Acta Paediatr Int J Paediatr* 2020; 109:2008–16.
2. Ramalho CE, Bretas PMC, Schwartsman C, Reis AG. Sedation and analgesia for procedures in the pediatric. *J Pediatr (Rio J)* 2017; 93:2–18.
3. Jung SM. Drug selection for sedation and general anesthesia in children undergoing ambulatory magnetic resonance imaging. *Yeungnam Univ J Med* 2020; 37:159–68.
4. Blüml S, Panigrahy A. *MR Spectroscopy of Pediatric Brain Disorders*. New York: Springer, 2012.
5. Godwin SA, Caro DA, Wolf SJ, Jagoda AS, Charles R, Marett BE, Moore J, American College of Emergency Physicians. Clinical policy: procedural sedation and analgesia in the emergency department. *Ann Emerg Med* 2005; 45:177–96.
6. Coté CJ, Wilson S, Casamassimo P, Crumrine P, Gorman RL, Hegenbarth M, & American Academy of Pediatric Dentistry. Guidelines for monitoring and management of pediatric patients during and after sedation for diagnostic and therapeutic procedures: An update. *Pediatrics* 2006; 118:2587–602.

A study of Gupta et al. (26) stated that the onset of midazolam (5-15 minutes) was better than dexmedetomidine (10-20 minutes). However, the sedation level of dexmedetomidine was better than midazolam. A study conducted by Sulton et al. (14) showed that intranasal dexmedetomidine combined with midazolam was an effective pre-medication regimen prior to MRI examination.

Overall, studies in this systematic review have a low risk of bias. However, there are two studies by Balasubramanian et al. (13) and Boriosi et al. (15), which have a high risk of bias in random sequence generation (n=12.5%). Balasubramanian et al. (13) study was a non-randomized control study. The recruited subjects had their history reviewed. Boriosi et al. (15) did not mention the study's recruitment method. In addition, the design used was a retrospective review by reviewing the patient's medical record so that the sample selection may not have been done randomly.

Limitations of this study is in terms of heterogeneity analysis which was not carried out to assess heterogeneity between the analysed studies.

In conclusion, a combination of dexmedetomidine and ketamine provides better hemodynamic stabilization, it does not provoke airway depression and provides a shorter recovery time. Dexmedetomidine alone requires a longer recovery time than other sedatives. The combination of dexmedetomidine with ketamine, propofol or midazolam shortens recovery time compared to sole dexmedetomidine.

## FUNDING

No specific funding was received for this study.

## TRANSPARENCY DECLARATION

Competing interests: None to declare.

7. Mahajan C, Dash HH. Procedural sedation and analgesia in pediatric patients. *J Pediatr Neurosci* 2014; 9:1–6.
8. Miller AL, Theodore D, Widrich J. *Inhalational Anesthetic*. Treasure Island: StatPearls Publishing, 2021.
9. Weerink MAS, Struys MMRF, Hannivoort LN, Barends CRM, Absalom AR, Colin P. Clinical pharmacokinetics and pharmacodynamics of dexmedetomidine. *Clin Pharmacokinet* 2017; 56:893–913.
10. Cochrane Denmark & Centre for Evidence-Based Medicine Odense. *Cochrane Methods Bias*. <https://methods.cochrane.org/bias/> (10 October 2022)
11. Ma LL, Wang YY, Yang ZH, Huang D, Weng H, Zeng XT. Methodological quality (risk of bias) assessment tools for primary and secondary medical studies: what are they and which is better? *Military Med Res* 2020; 7:1–11.
12. Olgun G, Ali MH. Use of intranasal dexmedetomidine as a solo sedative for MRI of infants. *Hosp Pediatr* 2018; 8:68–71.
13. Balasubramanian, B, Kulkarni SB. A non-randomized controlled study of total intravenous anesthesia regimens for magnetic resonance imaging studies in children. *J Anaesthesiol Clin Pharmacol* 2019; 35:379–85.
14. Sulton C, Kamat P, Mallory M, Reynolds J. The Use of intranasal dexmedetomidine and midazolam for sedated magnetic resonance imaging in children: a report from the Pediatric Sedation Research Consortium. *Pediatr Emerg Care* 2020; 36:138–42.
15. Boriosi JP, Eickhoff JC, Hollman GA. Safety and efficacy of buccal dexmedetomidine for MRI sedation in school-aged children. *Hosp Pediatr* 2019; 9:348–54.
16. Nagoshi M, Reddy S, Bell M, Cresencia A, Margolis R, Wetzel R, Ross P. Low-dose dexmedetomidine as an adjuvant to propofol infusion for children in MRI: a double-cohort study. *Paediatr Anaesth*. 2018; 28:639–46.
17. Tammam TF. Comparison of the efficacy of dexmedetomidine, ketamine, and a mixture of both for pediatric MRI sedation. *Egypt J Anaesth* 2013; 29:241–6.
18. Abulebda K, Louer R, Lutfi R, Ahmed SS. A Comparison of safety and efficacy of dexmedetomidine and propofol in children with autism and autism spectrum disorders undergoing magnetic resonance imaging. *J Autism Dev Disord* 2018; 48:3127–32.
19. Ahmed S, Unland T, Slaven J, Nitu M. Dexmedetomidine versus propofol: is one better than the other for MRI sedation in children? *J Pediatr Intensive Care* 2016; 6:117–22.
20. Eldeek AM, Elfawal SM, Allam MG. Sedation in children undergoing magnetic resonance imaging comparative study between dexmedetomidine and ketamine. *Egypt J Anaesth* 2016; 32:263–8.
21. Mylavarapu G, Fleck RJ, Ok MS, Ding L, Kandil A, Amin RS, Das B, Mahmoud M. Effects on the upper airway morphology with intravenous addition of ketamine after dexmedetomidine administration in normal children. *J Clin Med* 2020; 9:1–14.
22. Mahmoud M, Jung D, Salisbury S, McAuliffe J, Gunter J, Patio M, Donnelly LF, Fleck R. Effect of increasing depth of dexmedetomidine and propofol anesthesia on upper airway morphology in children and adolescents with obstructive sleep apnea. *J Clin Anesth* 2013; 25:529–41.
23. Watt S, Sabouri S, Hegazy R, Gupta P, Heard C. Does dexmedetomidine cause less airway collapse than propofol when used for deep sedation. *J Clin Anesth* 2016; 35:259–67.
24. Tang Y, Meng J, Zhang X, Li J, Zhou Q. Comparison of dexmedetomidine with propofol as sedatives for pediatric patients undergoing magnetic resonance imaging: a meta-analysis of randomized controlled trials with trial sequential analysis. *Exp Ther Med* 2019; 1775–85.
25. Zhou Q, Shen L, Zhang X, Li J, Tang Y. Dexmedetomidine versus propofol on the sedation of pediatric patients during magnetic resonance imaging (MRI) scanning: a meta-analysis of current studies. *Oncotarget* 2017; 8:102468–73.
26. Gupta A, Dalvi NP, Tendolkar BA. Comparison between intranasal dexmedetomidine and intranasal midazolam as premedication for brain magnetic resonance imaging in pediatric patients: a prospective randomized double blind trial. *J Anaesthesiol Clin Pharmacol* 2017; 33:236–40.
27. Trevisan M, Romano S, Barbi E, Bruno I, Murru FM, Cozzi G. Intranasal dexmedetomidine and intravenous ketamine for procedural sedation in a child with alpha-mannosidosis: a magic bullet? *Ital J Pediatr* 2019; 45:1–6.
28. Zhang W, Fan Y, Zhao T, Chen J, Zhang G, Song X. Median effective dose of intranasal dexmedetomidine for rescue sedation in pediatric patients undergoing magnetic resonance imaging. *Anesthesiology* 2016; 125:1130–5.