

# Surgical treatment and outcome of spinal arteriovenous malformations

Andhika Yudistira<sup>1\*</sup>, Syaifullah Asmiragani<sup>1</sup>, Ery Satriawan<sup>1</sup>, H.B Muammar<sup>1</sup>

<sup>1</sup>Orthopaedics and Traumatology Department, Faculty of Medicine Universitas Brawijaya – Saiful Anwar General Hospital, Malang, East Java, Indonesia

## ABSTRACT

**Aim** A rare and diverse set of abnormalities formed by spinal blood arteries known as spinal arteriovenous malformations (AVMs) has a higher risk of haemorrhage and morbidity, causing the shunting of blood from veins with an aberrant capillary bed to arteries. Knowledge of the vascular anatomy of spinal AVMs and the spinal cord's vascular supply is crucial to its therapy. The aim of this study was to report a case of SAVM healing after surgical excision, highlighting the importance of surgical excision in treating these rare lesions.

**Methods** A 56-year-old male with progressive bilateral lower extremity weakness and numbness was diagnosed with spinal cord arteriovenous malformation (SAVM). A thoracolumbar spine MRI was performed, and a vascular lesion was found. The feeding artery was coagulated and incised, and the surrounding hematoma was removed. Spinal cord arteriovenous malformation was diagnosed postoperatively. The Oswestry Disability Index (ODI) and the SF-36 questionnaires assessed functional outcomes and physical functioning in individuals with acute or chronic low back pain.

**Results** In the reported case, the aneurysm showed spontaneous regression at follow-up after surgical removal of the AVM. Post-surgery rehabilitation improved his motor function. After seven months, he showed 90% physical functioning, 75% emotional well-being, 75% social functioning, 87.5% pain, and 55% general health. He could walk with a walking aid and perform daily activities.

**Conclusion** Treatment strategies for AVM-related spinal aneurysms should be carefully considered. Surgical treatment in several conditions has advantages and is reported to have good outcomes.

**Keywords:** arteriovenous malformations, patient outcome assessment, surgical procedures, operative

## INTRODUCTION

A rare and diverse set of abnormally formed spinal blood arteries known as spinal arteriovenous malformations (AVMs) has a higher risk of haemorrhage and morbidity. In particular, these abnormalities cause the shunting of blood from veins with an aberrant capillary bed to arteries (1). Intradural AVMs are congenital lesions

that affect men and women equally. Patients typically present by their third decade of life (2,3). Spinal arteriovenous malformations (SAVMs) account for 3-4% of all intradural spinal cord mass lesions. SAVMs commonly affect the upper thoracic and cervical spine and are usually diagnosed late after neurological symptoms emerge (4,5).

Arteriovenous malformations (AVMs) are direct or abnormal connections between arteries and veins without an interposed capillary bed. In the SAVMs, intradural SAVMs are supplied by radiculomedullary arteries and drained by spinal cord veins (6). SAVMs may result in injury to the spinal cord if not treated by the mechanism of haemorrhage, circulatory disorders, and, rarely, space-occupying lesions that compress the spinal cord (7).

\* **Corresponding author:** Andhika Yudistira  
Orthopaedic and Traumatology Department, Spine Division Saiful Anwar General Hospital Jaks Agung Suprpto St. No. 2, Klojen, Malang, East Java 65112, Indonesia  
Phone: +62341 343858  
E-mail: andhika.yudhistira@ub.ac.id  
ORCID: <https://orcid.org/0000-0001-5157-8740>

Although the mechanism of spinal AVM development is not fully understood, most appear during birth rather than later in life (8). Over 70% of arterial pressure is delivered to the venous system due to the shunting of arteriole blood without capillary access and resistance. Venous hypertension can lead to numerous neurological impairments brought on by the mass effect, interruption of normal spinal blood flow, and an increased risk of haemorrhage (9,10).

The vascular anatomy of spinal AVMs and the spinal cord's vascular supply are crucial to its therapy. Segmental arteries split off spinal arteries when they enter the neural foramen to create radicular or medullary arteries, which nourish the nerve roots or cord, respectively (11). There is some variety in the spinal cord's vascular anatomy. On average, seven to eight medullary arteries supply the anterior spinal artery. The anatomy of the posterior spinal arteries varies greatly. They are derived from the posterior medullary arteries (12). Depending on where the major feeding vessel is located, blood can flow in either a rostral or caudal direction through the anterior and posterior spinal arteries. The most fragile blood supply is in the midthoracic area, which spans from T4 to T8. Only one medullary artery frequently supplies the area (more commonly from the left and in the T5 to T7 region) (13). The artery of Adamkiewicz enters between T5 and L2 in 85% of cases and from the left in 80% of cases, supplying the thoracolumbar and sacral regions below T9 (10,14,15).

We report a case of a SAVM that healed after the surgical excision of a spinal AVM, highlighting the significance of the outcome after surgical excision and addressing the optimal treatment of these uncommon lesions in light of the evidence reported.

## PATIENTS AND METHODS

### Patients and study design

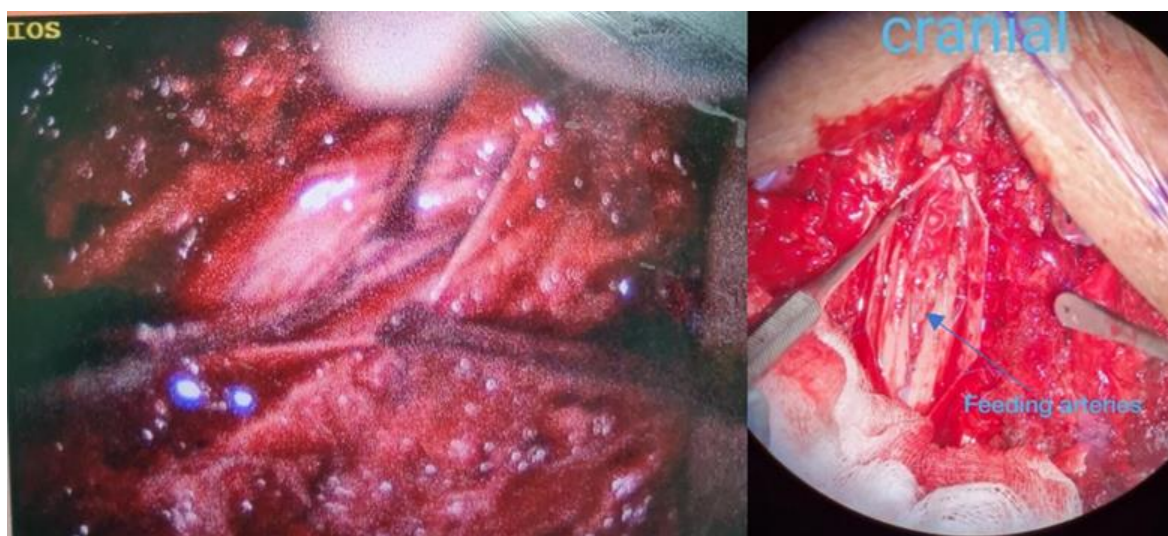We report a case of an SAVM. After collecting the patient's consent, data regarding clinical and radiological presentation, surgical treatment, and postoperative outcome at follow-up were retrospectively collected.

A 56-year-old male presented with a chief complaint of progressive bilateral lower extremity weakness and numbness. At first, the patient felt numbness on both feet 3 months before; the numbness was thought in the below knee area with progressive weakness in both lower extremities, primarily the left leg and complete weakness was felt for one month. On physical examination, the patient presented with weakness in the lower extremities.

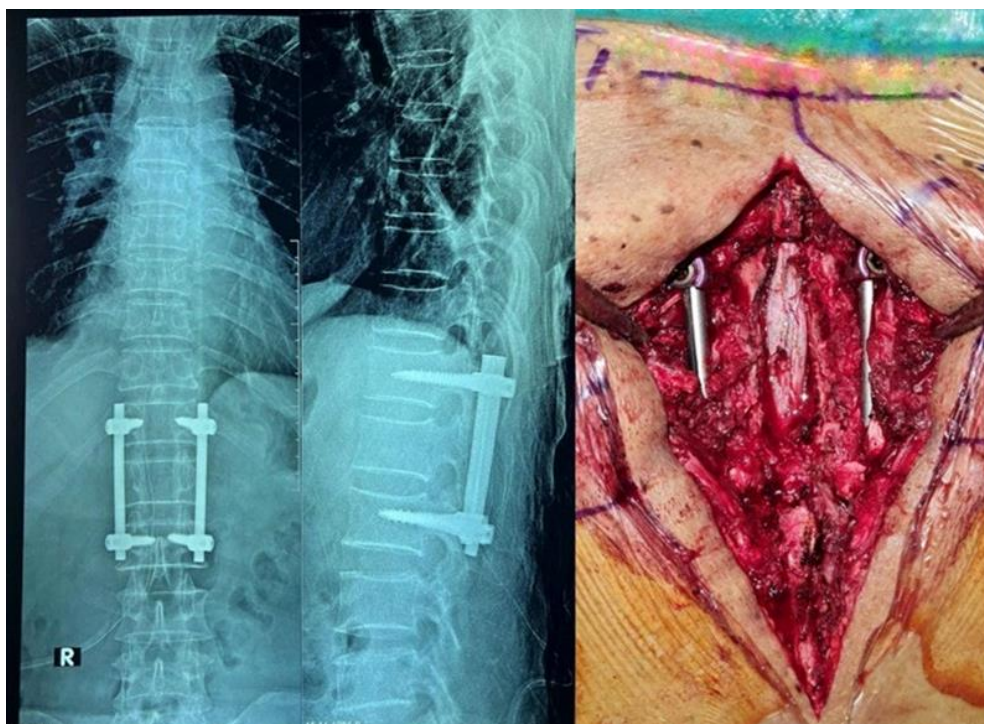
### Methods

A thoracolumbar spine MRI was performed. Decompression and posterior pedicle screw instrumentation were performed from T12-L1 vertebrae. After the dura was opened, a vascular lesion with a prominent radicular artery feeding was found (Figure 1). The feeding artery was coagulated and incised. The vascular lesion was excised, and the surrounding hematoma was removed. Spinal cord arteriovenous malformation was diagnosed postoperatively (Figure 2).

In the assessment of functional outcomes and physical functioning in individuals with acute or chronic low back pain, the Oswestry Disability Index (ODI) questionnaire was used. This survey produces a subjective percentage score that assesses the degree of physical function or disability. The cumulative score indicates the patient's level of functioning, ranging from mild disability to being bedridden (16).



**Figure 1.** Intraoperative photo shows the feeding artery was coagulated (left), and the feeding arteries were incised (right) (Dr Saiful Anwar General Hospital, 2022)



**Figure 2. Postoperative lumbosacral radiology examination anteroposterior and lateral view (left:); post duroplasty (right)** (Dr Saiful Anwar General Hospital, 2022)

The SF-36, a 36-item questionnaire, was used to assess the Health-Related Quality of Life. The SF-36 assesses eight dimensions: physical functioning (PF), role physical (RP), bodily pain (BP), general health (GH), vitality (VT), social functioning (SF), role emotional (RE), and mental health (MH). The components' analysis revealed that the SF-36 assesses two separate constructs: a physical dimension, denoted by the Physical Component Summary (PCS), and a mental dimension, denoted by the Mental Component Summary (MCS). Each scale contributes to scoring PCS and MCS measurements in varying quantities (17).

## RESULTS

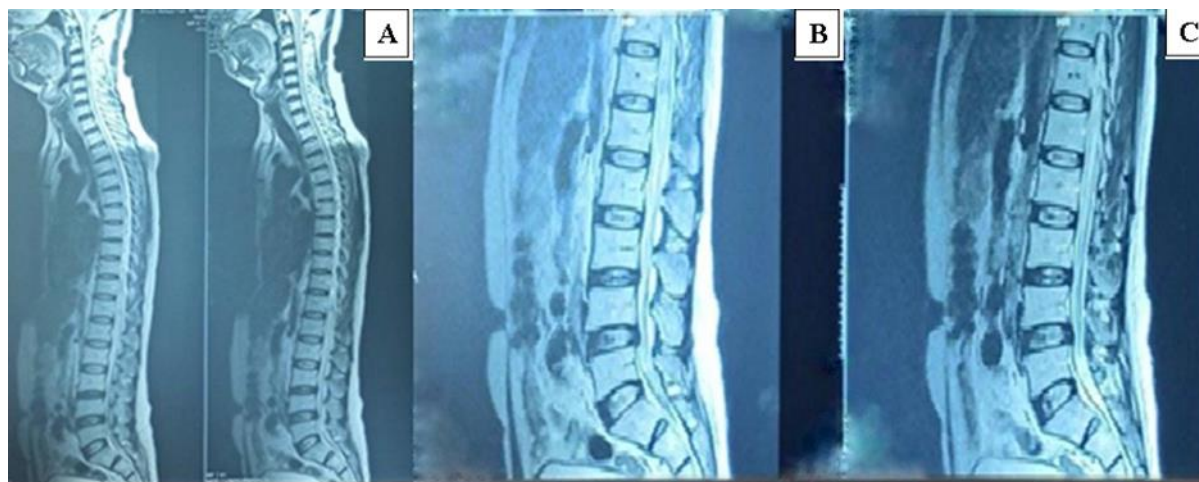
According to Frankel's classification assessment (18), the patient was Frankel C with a T12 sensory level. A thoracolumbar spine MRI found diffuse oedema of the spinal cord, which raised suspicion for spinal AVM at T12-L1, as seen on T2-weighted imaging (Figure 3, Figure 4).

Postoperatively, rehabilitation was followed by the patient to improve the patient's functional outcome. Seven months after the surgery, the patient's motor function improved on the follow-up. The ODI score evaluation result was 16, and the SF-36 result was physical functioning 90%, role limitations due to physical health 75%, role limitations due to emotional problems 100%, energy/fatigue 55%, emotional well-being 72%, social functioning 75%, pain 87.5%, general health 55%, health change 100%. The patient can walk with a walking aid and perform basic daily activities.

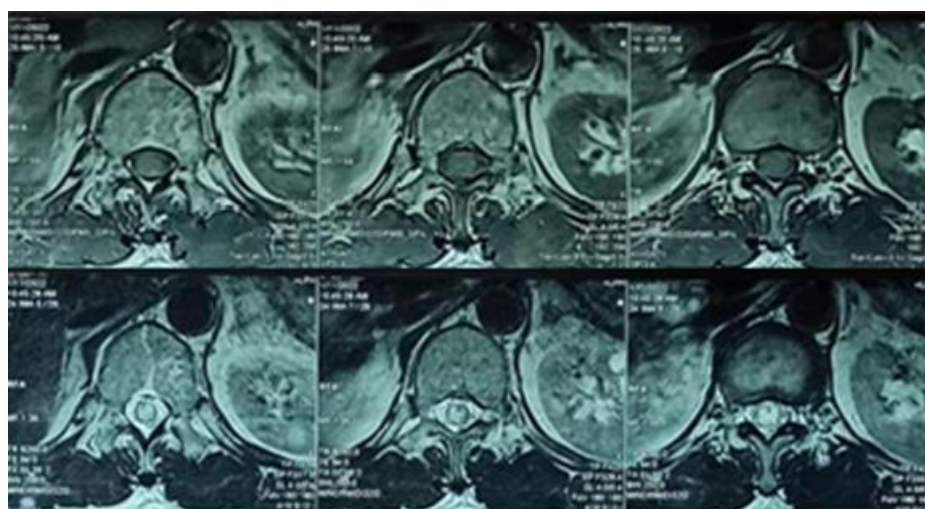
## DISCUSSION

Despite being uncommon, our patient's AVM had the typical age range and appearance. It is also noteworthy that decompression and posterior pedicle screw instrumentation with the feeding artery coagulated and incised was chosen in this instance, even though these AVMs are generally embolized for symptom relief (14). The patient accepted the surgery well, and his back pain subsided. On the follow-up, he reported that he could walk with a walking aid and perform basic daily activities.

Patients with unruptured AVM-associated spinal aneurysms mostly complained about paresis on their extremities (19). Spinal arteriovenous malformations (AVMs) encompass various vascular abnormalities in the spinal cord. How they manifest clinically varies based on which part of the spine is affected and the extent of the malformation (20). A past research case documented an instance where a person experienced saddle anaesthesia, as well as increasing numbness and weakness in both legs due to spinal involvement (21). In prior cases, three patients had unruptured AVM-associated spinal aneurysms; these patients experienced myelo-radiculopathy symptoms, which were caused by the presence of the malformation (21). This malformation either exerted pressure as a mass effect or led to vascular steal (19). In the other three cases, patients reported symptoms of subarachnoid haemorrhage alongside the symptoms arising from AVM-related compression or spinal cord ischemia (21,22). In the remaining cases, most patients complained of paraesthesia symptoms (21).



**Figure 3.** T2 weighted images of lumbar magnetic resonance imaging (MRI): A) diffuse oedema of the spinal cord in sagittal view; B) hyperintense imaging; C) hypointense imaging (Dr Saiful Anwar General Hospital, 2022)



**Figure 4.** T1 and T2 weighted images of lumbar magnetic resonance imaging (MRI) axial view. T1 weighted images (above); T2 weighted images showed a hyperintense in liquor cerebrospinal (LCS) (below) (Dr Saiful Anwar General Hospital, 2022)

This distinction in clinical manifestations highlights the importance of considering the precise location of the AVM within the spinal cord when assessing and diagnosing patients (23). Our patient was diagnosed with Frankel C with a T12 sensory level. Grade C patients have some degree of motor and sensory function below the level of injury, but their retained/recovered motor function is useless.

Understanding of the presence of an aneurysm and its location within the spinal cord is paramount. Aneurysms can significantly impact the treatment approach, necessitating a tailored strategy that considers both the AVM and any coexisting aneurysm. By meticulously analysing these aspects, healthcare professionals can develop a comprehensive and personalized treatment plan that maximizes the likelihood of successful intervention and optimal patient outcomes (21). While our patient already had a complete motor loss in his bilateral lower extremities, he did have the potential too; thus, preservation of this

artery was of most importance. The location of this artery in our patient's AVM contributed to the necessity for open surgery rather than embolization.

This finding aligns with the research spearheaded by Baldassarre et al. (22). In her specific case, the study underscored that open surgery emerged as the superior therapeutic approach to endovascular therapy in patients exhibiting symptoms akin to those in the present case. The procedure involved a microsurgical resection of the arteriovenous malformation (AVM), utilizing a posterior approach for optimal precision and efficacy (22). The patient showed significant progress after surgery, ambulating independently, with no neurological deficits, and improved sphincter control over two weeks (22). This promising development not only reaffirmed the effectiveness of the chosen surgical approach but also shed light on the potential for continued positive outcomes and enhanced quality of life for the patient. The holistic success of the treatment underscored the significance of tailored surgical

interventions in managing spinal AVMs, hinting at a positive trajectory for similar cases in the future (24).

The management of spinal vascular malformations varies based on the type and location of the lesion, as well as the surgical expertise available at neurosurgical centres (25). Initially, conservative approaches were common, but now there is a shift towards advanced techniques such as endovascular embolization or surgical resection. This transformation results from better understanding of these malformations and advancements in treatment techniques (24). A uniform conservative approach may not be the most effective (24). Instead, tailoring treatments to each case's specific characteristics, like the type and location of the malformation, is proving to be more beneficial (24). The utilization of endovascular embolization and surgery underscores the importance of a multidisciplinary approach involving neurosurgeons and interventional radiologists. By considering and utilizing a range of treatment options based on individual cases, the aim is to enhance patient care and prognosis for those with spinal vascular malformations (26).

In this study, we reported good clinical outcomes after spinal arteriovenous malformation based on improved ODI scores. This result was in line with the outcome of the other reports, which found that surgery was superior to embolization (27). According to research by Rangel Castilla, undergoing an intervention carries a risk of experiencing temporary neurological issues after the operation (27). However, the overall clinical results seem to surpass what would occur naturally, likely due to patients' ability to recover during the postoperative monitoring period. This suggests the surgical approach demonstrates superior outcomes and reduced patient recurrence rates (28). This observation aligns with our patient, who showed improved motor function during the follow-up examination seven months after the surgical procedure.

Early detection, investigation, diagnosis, and management of this case could lead to an excellent neurological prognosis, but delayed treatment could have resulted in death and progressive deficits (29). Recurrence in adult AVM is low, especially in patients under 18, with rates ranging from 5.5% to 17.5%. The Adamkiewicz artery, which can cause severe spinal cord ischemia and neurological abnormalities, is crucial for reversing AVM. Open surgery was necessary due to the artery's position, as it allowed the patient to regain control despite losing motor function (14,27).

Treatment strategies for AVM-related spinal aneurysms should be carefully considered. Surgical treatment in several conditions has advantages and is reported to have good outcomes.

## ACKNOWLEDGEMENTS

This research paper is made possible by the support from parents, family, and friends.

## FUNDING

No specific funding was received for this study

## TRANSPARENCY DECLARATION

Conflict of interests: None to declare.

## REFERENCES

- 1 Schimmel K, Ali MK, Tan SY, Teng J, Do HM, Steinberg GK, et al. Arteriovenous Malformations-Current Understanding of the Pathogenesis with Implications for Treatment. *Int J Mol Sci* 2021; 22;(16):9037. doi: 10.3390/ijms22169037.
- 2 Scoville WB. Intramedullary arteriovenous aneurysm of the spinal cord; case report with operative removal from the conus medullaris. *J Neurosurg* 1948;5;(3):307–12. doi:10.3171/jns.1948.5.3.0307.
- 3 Piotin M, Ross IB, Weill A, Kothimbakam R, Moret J. Intracranial arterial aneurysms associated with arteriovenous malformations: endovascular treatment. *Radiology* 2001;220;(2):506–13. doi: 10.1148/radiology.220.2.r01au09506.
- 4 Ropper AE, Gross BA, Du R. Surgical treatment of Type I spinal dural arteriovenous fistulas. *Neurosurg Focus* 2012;32;(5):E3. doi: 10.3171/2012.1.FOCUS11344.
- 5 Ushikoshi S, Hida K, Kikuchi Y, Iwasaki Y, Miyasaka K, Abe H. Treatment of intramedullary arteriovenous malformations of the spinal cord. *Interv Neuroradiol J Peritherapeutic Neuroradiol Surg Proced Relat Neurosci* 2000;6 Suppl 1;(Suppl 1):203–7. doi: 10.1177/15910199000060S133.
- 6 Whitehead KJ, Smith MCP, Li DY. Arteriovenous malformations and other vascular malformation syndromes. *Cold Spring Harb Perspect Med* 2013;3;(2):a006635. doi: 10.1101/cshperspect.a006635.
- 7 Jung SC, Song Y, Cho SH, Kim J, Noh SY, Lee SH, et al. Endovascular management of aneurysms associated with spinal arteriovenous malformations. *J Neurointerventional Surg* 2018;10;(2):198–203. doi: 10.1136/neurintsurg-2017-013150.
- 8 Hoque ST, Islam MS, Rashid MM, Khan SI, Biswas MS. Spinal arteriovenous fistula: case report and review of the literature. *Int J Nov Res Devel* 2023;8:242–9.
- 9 Geibprasert S, Krings T, Apitzsch J, Reinges MHT, Nolte KW, Hans FJ. Subarachnoid hemorrhage following posterior spinal artery aneurysm. A case report and review of the literature. *Interv Neuroradiol J Peritherapeutic Neuroradiol Surg Proced Relat Neurosci* 2010;16;(2):183–90. doi: 10.1177/159101991001600211.

- 10 Vercelli GG, Minardi M, Bergui M, Zenga F, Garbossa D, Cofano F. Spinal dural and epidural arteriovenous fistula: Recurrence rate after surgical and endovascular treatment. *Front Surg* 2023;10:1148968. doi: 10.3389/fsurg.2023.1148968.
- 11 Miyasaka K, Asano T, Ushikoshi S, Hida K, Koyanagi I. Vascular anatomy of the spinal cord and classification of spinal arteriovenous malformations. *Interv Neuroradiol J Peritherapeutic Neuroradiol Surg Proced Relat Neurosci* 2000;6 Suppl 1;(Suppl 1):195–8. doi: 10.1177/15910199000060S131.
- 12 Gao L, Wang L, Su B, Wang P, Ye J, Shen H. The vascular supply to the spinal cord and its relationship to anterior spine surgical approaches. *Spine J Off J North Am Spine Soc* 2013;13(8):966–73. doi:10.1016/j.spinee.2013.03.017.
- 13 Hasan S, Arain A. *Neuroanatomy, Spinal Cord Arteries*. StatPearls, Treasure Island (FL): StatPearls Publishing; 2024.
- 14 Ferch RD, Morgan MK, Sears WR. Spinal arteriovenous malformations: a review with case illustrations. *J Clin Neurosci Off J Neurosurg Soc Australas* 2001;8(4):299–304. doi: 10.1054/jocn.2000.0914.
- 15 Singh B, Behari S, Jaiswal AK, Sahu RN, Mehrotra A, Mohan BM, et al. Spinal arteriovenous malformations: Is surgery indicated? *Asian J Neurosurg* 2016;11(2):134–42. doi: 10.4103/1793-5482.177663.
- 16 D’Souza RS, Gupta M, Abd-Elsayed A. Measuring outcomes. *Spinal Fusion Tech.*, Elsevier; 2024, p. 71–5. doi: 10.1016/b978-0-323-88223-1.00017-6.
- 17 Saris-Baglana RN, Dewey CJ, Chisholm GB, Plumb E, King J, Kosinski M, et al. *QualityMetric™ health outcome scoring software: 4.0 installation guide 2010*.
- 18 Frankel HL, Hancock DO, Hyslop G, Melzak J, Michaelis LS, Ungar GH, et al. The value of postural reduction in the initial management of closed injuries of the spine with paraplegia and tetraplegia. I. *Paraplegia* 1969;7(3):179–92. doi: 10.1038/sc.1969.30.
- 19 Cox TM, Chavez Andia DM, Aisenberg G. Arteriovenous Malformation of the Cervical Spine Presenting as Subarachnoid Hemorrhage. *Cureus* 2020;12(3):e7200. doi: 10.7759/cureus.7200.
- 20 Udelhoven A, Kettner M, Reith W. [Spinal arteriovenous malformations]. *Radiol Heidelberg Ger* 2022;62(8):666–70. doi: 10.1007/s00117-022-01024-4.
- 21 Patchana T, Savla P, Taka TM, Ghanchi H, Wiginton J, Schiraldi M, et al. Spinal Arteriovenous Malformation: Case Report and Review of the Literature. *Cureus* 2020;12(11):e11614. doi: 10.7759/cureus.11614.
- 22 Baldassarre B, Balestrino A, D’Andrea A, Anania P, Ceraudo M, Truffelli M, et al. Management of spinal aneurysms associated with arteriovenous malformations: systematic literature review and illustrative case. *Eur Spine J Off Publ Eur Spine Soc Eur Spinal Deform Soc Eur Sect Cerv Spine Res Soc* 2021;30(10):2767–74. doi: 10.1007/s00586-021-06881-6.
- 23 Ren Y, He M, You C, Li J. Successful Surgical Resection of Spinal Artery Aneurysms: Report of 3 Cases. *World Neurosurg* 2018;109:171–8. doi: 10.1016/j.wneu.2017.09.174.
- 24 Gennaro P, Cioni S, Bracco S, Cascino F, Latini L, Abbagnato M, et al. A Single-Center Retrospective Analysis of 14 Head and Neck AVMs Cases Treated with a Single-Day Combined Endovascular and Surgical Approach. *J Pers Med* 2023;13(5):757. doi: 10.3390/jpm13050757.
- 25 Tabrizi P, Spetzler RF. Surgical treatment of spinal cord vascular malformations. *Interv Neuroradiol J Peritherapeutic Neuroradiol Surg Proced Relat Neurosci* 2003;9;(Suppl 2):103–5. doi: 10.1177/15910199030090S219.
- 26 Yamazaki D, Hanaoka Y, Koyama J-I, Suzuki Y, Agata M, Abe D, et al. Intraspinous canal platform system for coil embolization of anterior spinal artery aneurysm associated with spinal cord arteriovenous malformation: a case report and literature review. *Br J Neurosurg* 2023;37(6):1786–91. doi: 10.1080/02688697.2021.1910201.
- 27 Rangel-Castilla L, Russin JJ, Zaidi HA, Martinez-Del-Campo E, Park MS, Albuquerque FC, et al. Contemporary management of spinal AVFs and AVMs: lessons learned from 110 cases. *Neurosurg Focus* 2014;37(3):E14. doi: 10.3171/2014.7.FOCUS14236.
- 28 Lenck S, Nicholson P, Tymianski R, Hilditch C, Nouet A, Patel K, et al. Spinal and Paraspinal Arteriovenous Lesions. *Stroke* 2019;50(8):2259–69. doi: 10.1161/STROKEAHA.118.012783.
- 29 Lee Y-J, Terbrugge KG, Saliou G, Krings T. Clinical features and outcomes of spinal cord arteriovenous malformations: comparison between nidus and fistulous types. *Stroke* 2014;45(9):2606–12. doi: 10.1161/STROKEAHA.114.006087.