

Neurocysticercosis with symptomatic epilepsy manifestation

Nataliya Nekrasova¹, Olena Tovazhnyanska¹, Daryna Sushetska¹, Olena Markovska¹, Anton Shapkin², Rhea Singh¹, Yevhenija Soloviova¹, Dmytro Butov³

¹Department of Neurology No2, ²Department of Pathomorphology, ³Department of Phthysiology and Pulmonology; Kharkiv National Medical University, Kharkiv, Ukraine

ABSTRACT

Aim To present a unique case of a 22-year-old male patient with symptomatic epilepsy manifestation on a background of neurocysticercosis (NCC).

Methods An Indian student in Kharkiv, who lived in rural parts in India, presented with sudden episodes of seizure followed by severe headaches. Laboratory analyses and neurological status (MRI) were performed.

Results Neurological status of the patient revealed nystagmus and difficulty in performing co-ordination tests. General analysis of blood showed raised eosinophil count to 8%. The MRI showed a few small conglomerating peripherally enhancing thick-walled infective granulomas in left frontal lobe with extensive surrounding oedema in the left fronto-parietal lobe. The patient was treated with albendazol, levipil, methylprednisolone and pantoprazole. Clinical symptoms and subsequent MRI showed improvement.

Conclusion Neurocysticercosis is often misdiagnosed in the early stages, which leads to adverse outcomes. Although seizures are the most common clinical manifestation, it is a symptom that is not found in majority of the patients. The NCC of adult onset accompanying epileptic seizures is not well studied and a link between the helminthic invasion, epilepsy and psychiatric conditions needs to be established. This disease is potentially eradicable with well-planned eradication programs targeting all stages of *Taenia solium* life cycle.

Key words: granuloma, frontal lobe, seizures, *Taenia solium*

Corresponding author:

Nataliya Nekrasova
Department of Neurology No2,
Kharkiv National Medical University
Kharkiv Nauky Avenue 4, 61022,
Kharkiv, Ukraine
Phone: +380 50 615 45 80;
E-mail: limka.nno@gmail.com
ORCID ID: <https://orcid.org/0000-0002-0900-4441>

Original submission:

03 March 2021;

Revised submission:

22 April 2021;

Accepted:

18 May 2021

doi: 10.17392/1368-21

Med Glas (Zenica) 2021; 18(2):444-449

INTRODUCTION

Originally recognized as a swine disease in ancient Greece, neurocysticercosis (NCC) is now considered the most common helminthic disease of the central nervous system in humans (1). Conditions like a warm climate, severe poverty, illiteracy and unhygienic living conditions, all favour the transmission of this disease in most of the developing world, which makes it endemic to these regions (2). Furthermore, according to various population-based studies, the main reason for the higher prevalence of people with epilepsy in rural villages of endemic countries is NCC in comparison to the prevalence of epilepsy in developed countries due to other reasons (1). It has been called a "hidden epidemic" (3) and "arguably the most common parasitic disease of the human nervous system" (4). Cysticercosis in the United States, commonly presenting in the form of neurocysticercosis, has been classified as a "neglected tropical disease" (5,6), commonly affecting the poor and homeless, particularly those without access to a clean environment or those with ill-habit of inadequate hand-washing and eating with such unclean hands. The NCC is a preventable parasitic infection caused by larval cysts of the pork tapeworm (*Taenia solium*). The most important risk factor for acquiring cysticercosis is being in close proximity to a tapeworm carrier. Larval cysts of the tapeworm can find their way to the brain and lead to epilepsy (7). The NCC is acquired through consumption of food or water contaminated with faeces of a carrier of *T. solium* tapeworm (faecal–oral route of transmission). Common symptoms of NCC include seizures, headaches, blindness, meningitis and dementia (8). Infected humans pass out eggs or gravid proglottids through their faeces, which can be ingested by pig living in an area of poor hygiene. The eggs further develop and complete the complex life cycle of the tapeworm (9). This disease often goes un- or misdiagnosed. Even when diagnosed, there is a huge gap in a treatment. Generally, patients with NCC present with either tonic-clonic seizures or partial-onset seizures. Usually, most of the patients have an active cyst—either vesicular or colloidal, at the time of the first seizure. New-onset seizures are commonly associated with active cysts. Chronic epilepsy is usually associated with calcified granulomas (10). The most epileptogenic cysts

are considered to be active cysts undergoing degeneration (colloidal cysts). Cysts degeneration usually happens fast within 6 to 12 months after initial presentation. As a result, the rates of seizure-recurrence increase during this period (because of the conversion from vesicular cysts to colloidal cysts). Epileptogenesis in patients with NCC can be attributed to several factors: inflammation, gliosis, genetics, and predilection for the cysts to travel to the frontal and temporal lobes (1). Furthermore, the response of the host to degenerating cysts cannot be disregarded in the process of epileptogenesis.

A magnetic resonance imaging (MRI) scan is often needed for increased diagnostic sensitivity and accuracy (11). Diagnosis may be confirmed by detection of antibodies against cysticerci in cerebrospinal fluid (CSF) or serum through ELISA or immunoblotting techniques (2,12). Albendazole (13,14) and praziquantel are the principal anti-parasitic drugs used to treat NCC, as they reduce the number of cysts and frequency of seizures.

Here we present a case of neurocysticercosis in a young adult with manifestation of symptomatic epilepsy and behavioural changes.

PATIENT AND METHODS

Patient and study design

A 22-year-old male patient from India was hospitalized in the neurological department of Kharkiv city Students Hospital in November 2019 with complaints of convulsion attacks with impaired consciousness occurring at his hostel in Kharkiv and at the University.

The first episode of seizure occurred one day prior to hospitalization. According to the roommates, the patient fell suddenly in the evening while walking with his head turned to the right and convulsions in both his hands and feet, which lasted for approximately 1 minute. The seizure was not preceded by an aura. The patient remained unconscious for 5–7 minutes after the seizure. After that, the patient complained of a severe headache, but he had no confusion. A similar attack was repeated the next day during school hours, which was when the patient was examined by a physician and was sent to the neurological department Kharkiv Regional Hospital with a preliminary diagnosis: Idiopathic epilepsy.

From the anamnesis, the patient reported no nausea or vomiting. However, he reported having experienced episodes of mild-moderate headache of a waxing and waning character for the past year. He also complained of occasional tingling feeling in his right lower limb, which had been progressively increasing in duration (usually lasting for 5-15 minutes) for the last 6 months. The patient also reported having difficulty in socializing and increasing anger management issues for the past two years and that this was different from his personality as a child. However, the patient had never been diagnosed with any psychiatric disorder (as he did not find them concerning).

The patient lived with his family in India in a small town before arriving in Kharkiv in 2018 for studies. His living conditions were "normal". The family claimed to be vegetarians and did not consume meat of any kind. He had one younger brother, who never had any medical conditions. Both his parents suffered from hypertension. In addition, the mother suffered from migraine. The patient did not smoke or drink alcohol.

Methods

Biochemical laboratory analyses, neurological status with MRI was performed.

RESULTS

On examination the patient had no fever (temperature was 37°C), heart rate of 85/minute, respiratory rate of 19/minute, oxygen saturation of 97%, and blood pressure of 130/89 mm of Hg. His skin was moist with good elasticity. He had no significant cardiac, respiratory, gastrointestinal or urinary symptoms.

In the neurological status: consciousness was clear, orientation of space and time was present. Pupils and palpebral fissures were identical on both sides, left and right. Convergence was saved. Horizontal nystagmus to the left was present. The face was symmetrical with the tongue in the midline. Deep tendon reflexes were quickened but symmetrical, left and right. The sensitivity of the face and limbs was saved. Pathological reflexes and meningeal signs were not determined. In the Romberg position, the patient was stable. However, the patient had trouble in performing coordination tests.

The diagnosis on admission: Focal motor seizures, idiopathic epilepsy.

General analysis of blood showed: red blood cells (RBC) $4.8 \times 10^{12}/L$, haemoglobin 152g/L, mean corpuscular haemoglobin (MCH) 0.9, white blood cells (WBC) $7.5 \times 10^9/L$, eosinophils 8.0%, stab neutrophils 4%, segmental neutrophils 57%, lymphocytes 24%, monocytes 5% and erythrocyte sedimentation rate (ESR) 20 mm/h.

An electroencephalograph (EEG) showed high voltage activity of delta waves. Such abnormalities were detected because of the presence of 2.5-3-Hz-wave formations in left fronto-parietal distribution.

The MRI (Figure 1) was conducted on 26 November 2019, which showed a cortical-subcortical inhomogeneous structure in the lateral parts of the left frontal lobe with volume formation, irregular shape, without clear outlines of size 24x26x25mm with a pronounced perifocal oedema and mass effect with compression of the left lateral ventricle and shift of midline structures to the right by 3mm. The maxillary sinuses were swollen with a thickening of the mucosa by 4-5 mm, along with the presence of cysts on the right of size 25x17mm.

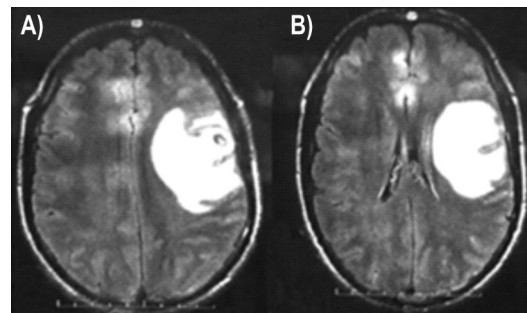


Figure 1. Magnetic resonance imaging (MRI) of the brain at admission at Kharkiv city Students Hospital on 26 November 2019. A, B) On both slides in frontal section at different degrees of depth the lateral part of the left frontal lobe is depicted with the presence of cortical-subcortical inhomogeneous structure with volume formation, irregular shape, without clear outlines of 24x26x25 mm size with a pronounced perifocal oedema and mass effect with compression of the left lateral ventricle and shift of midline structures to the right by 3mm

Based on the epidemiological anamnesis, clinical and MRI research, the patient was diagnosed with neurocysticercosis with a primary lesion of the left frontal lobe: symptomatic epilepsy, cephalic and asthenic syndrome.

The patient was prescribed (orally) carbamazepin 200 mg 2 times a day for 6 months and albendazole 400 mg 2 times a day for 3 weeks according to the local guidelines of Ukraine.

On 28 November 2019, the patient self-discharged due to the desire to continue the treatment at home.

On 2 December 2019, the patient referred to Fortis Hospital Limited in Mumbai, India, where anti-cysticercus antibody test was done, which came out to be positive and another brain MRI with contrast (Figure 2) was performed showing a few small conglomerating peripherally enhancing thick-walled infective granuloma in left frontal lobe with extensive surrounding oedema in the left fronto-parietal lobe. These showed central T2 hyper intense signal intensity with peripheral T2 hypointensity. The conglomerate lesion measured approximately 20x12 mm along axial the dimension. Minimal shift of falx to the right is noted. Findings likely - neurocysticercosis.

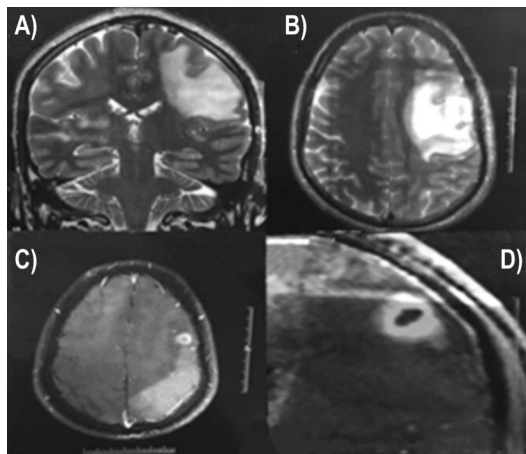


Figure 2. The MRI of brain with contrast in Fortis Hospital Limited in Mumbai, India on 02 December 2019. A) In frontal section persistent small well-defined heterogeneously enhancing conglomerate lesion involving left frontal lobe with surrounding mild perilesional oedema with minimal blooming in gradient is revealed. B) C) D) In cranio-caudal dimension at different degrees of depth the conglomerate lesion measured 9x10 mm in axial dimensions and 15.5mm in cranio-caudal dimension is depicted

On 4 December 2019, the patient was examined by a neurosurgeon at Fortis Hospital Limited in Mumbai, India and received recommendation for a treatment (orally) according to the Indian Guidelines: levipil 500 mg 2 times a day for 2-3 years, albendazole 400 mg 2 times a day for 3 weeks, methylprednisolone 4 mg three times a day, with a gradual reduction of the dose for 15 days, panta-prazol 40 mg 2 times a day for 15 days, and carbamazepin 200 mg 2 times a day for 2 years.

On 6 January 2020, the patient referred again to the Fortis Hospital Limited, where brain MRI with contrast (Figure 3) revealed persistent small well-defined heterogeneously enhancing conglomerate lesion involving left frontal lobe with surrounding

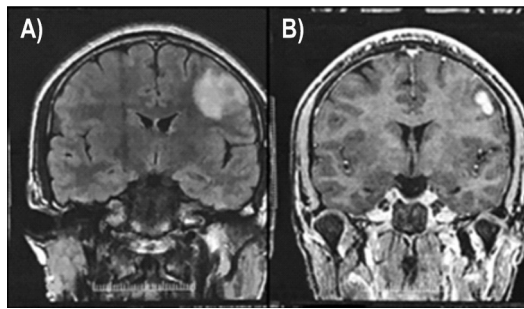


Figure 3. The MRI of brain with contrast done in Fortis Hospital Limited in Mumbai, India on 06 January 2020. A, B) On both slides in frontal section at different degrees of depth left frontal lobe with persistent small well-defined heterogeneously enhancing conglomerate lesion (measured 9x10 mm in axial and 15.5 mm in cranio-caudal dimension) with surrounding mild perilesional oedema with minimal blooming in gradient is depicted

mild perilesional oedema, which appeared hyperintense in T2-weighted images and isointense in T1W images. Minimal blooming was noted in gradient recalled echo (GRE) images. No areas of restricted diffusion in diffusion-weighted imaging (DWI) were seen. The conglomerate lesion measured approximately 9x10 mm in axial dimensions (previously measuring 20x12mm) and 15.5 mm in cranio-caudal dimension.

On 31 January 2020, with consultation at neurology department №2, Kharkiv, some conclusions about the patient's health were made: the patient's condition had improved, the dynamics of complaints (the absence of seizures, reducing the intensity and frequency of headaches) and MRI picture were positive and the neurologic status was without any remarkable features. The patient was recommended to be continually monitored by neurologist, infectious diseases doctor and repeat MRI in 6 months. Oral treatment was prescribed: levipil 500 mg 2 times daily for 2-3 years, carbamazepin 200 mg 2 times a day for 2 years.

The patient was also advised to consider psychotherapy regarding the changes in his personality.

The patient reported decrease in the frequency of headaches and the duration of tingling in the extremities after 4 months of treatment. Although the patient did not get an MRI done, clinically, he looked better.

DISCUSSION

We present a case of NCC with epileptic syndrome and psycho-behavioural changes. Although according to WHO data, infection of the central nervous system with *Taenia solium* is one of the leading

causes of epilepsy, in our country such diseases as neurocysticercosis are rare and in the differential diagnosis of the causes of epileptic syndrome are not in the first place. It should be borne in mind that today the population migration is very active and the endemicity of the spread of diseases is losing its relevance. Describing this clinical case, we want to pay the attention of doctors to this problem, so that in the future they treat such patients with greater caution. Another aspect of this matter is its treatment: various randomized studies evaluating the clinical benefits of the treatment have yielded conflicting data whereby some studies indicate a benefit of the treatment and others suggest that the treatment shows no difference in patients' condition (12). Our patient however, responded well to the treatment.

Cysticerci may be located in brain parenchyma, subarachnoid space, ventricular system, or spinal cord, causing pathological changes that are responsible for the pleomorphism of neurocysticercosis (1). In our patient, the disease was located in the left frontal lobe, which could explain the behavioural changes. Seizures are the most common clinical manifestation, but many patients present with focal deficits, intracranial hypertension, or cognitive decline (15). According to a study conducted in India only 8% of the patients with anti-cysticercus antibodies had a history of seizures (16). Interpretation of clinical data, neuroimaging studies and immunological test help in accurate diagnosis of neurocysticercosis.

Another aspect of this matter is its treatment: various randomized studies evaluating the clinical benefits of the treatment have yielded conflicting data whereby some studies indicate a benefit of the treatment, and others suggest that the treatment shows no difference in patients' condition (12). Our patient, however, responded well to the treatment. The introduction of cysticidal drugs have changed the prognosis of most patients with neurocysticercosis. These drugs have shown to reduce the burden of infection in the brain and to improve the clinical course of the disease in most patients. The therapy for NCC, formerly restricted to palliative measures, has advanced with the advent of two drugs considered to be effective: praziquantel (PZQ) and albendazole (ALB) (17). Even though there are treatment options, the treatment gap in India is more than 90% (13).

Patients with mental retardation were found to carry an increased risk of cysticercosis as compared with patients with other psychiatric disorders (6). Although, our patient had no mental retardation, he had a history of poor social skills and anger management issues. It has been estimated that a large proportion of psychiatric inpatients with positive cysticercosis serology, despite carrying no adult *Taenia* spp. in their stool and no CNS imaging, have high prevalence of NCC (6).

We presented a novel case of the young student who, despite living in "normal" conditions and being vegetarian, developed neurocysticercosis with symptomatic epilepsy and behavioural changes. We can only assume that the patient consumed contaminated vegetables or fruits growing in unhygienic conditions and got infected with tapeworm, which was dormant in his body for quite some time. Therefore, further efforts should be made to eradicate the disease via control program implementation against all interrelated steps in the life cycle of *T. solium*, including human carriers of the adult tapeworm, infected pigs and eggs in the environment. Since these targets represent interrelated steps in the life cycle of *T. solium*, inadequate coverage of even one of them may result in a rebound prevalence of taeniosis or cysticercosis after the program has been thought to be completed.

Despite a lot of literature information about this syndrome and its many symptoms including seizure-recurrence, it is often misdiagnosed, attention to which needs to be paid. The NCC of an adult onset, accompanying with symptomatic epilepsy and behavioural changes is not well studied. Further research in this field needs to be carried out.

ACKNOWLEDGMENTS

We acknowledge the wholehearted support of all clinicians, nurses, and lab staff who contributed to this research and made this study possible. Our sincere gratitude is expressed to the experts in the tuberculosis field who kindly shared their opinions and suggestions with us.

FUNDING

No specific funding was received for this study.

TRANSPARENCY DECLARATION

Competing interests: None to declare.

REFERENCES

1. Del Brutto OH. Neurocysticercosis: a review. *Sci World J* 2012; 159821.
2. Murray P, Rosenthal K, Pfäller M. *Medical Microbiology*. 7th ed. Philadelphia, PA, USA: Elsevier Saunders, 2013: p. 809.
3. Ahmad FU, Sharma BS. Treatment of intramedullary spinal cysticercosis: report of 2 cases and review of literature. *Surg Neurol* 2007; 67:74–7.
4. White AC. Neurocysticercosis: A major cause of neurological disease worldwide. *Clin. Infect. Dis* 1997; 24:101–31.
5. Hotez PJ. Neglected parasitic infections and poverty in the United States. *PLoS Negl Trop Dis* 2014; 8: e3012.
6. Meza NW, Rossi NE, Galeazzi TN. Cysticercosis in chronic psychiatric inpatients from a Venezuelan community. *Am J Trop Med Hyg* 2005; 73:504–9.
7. Del Brutto, Neurocysticercosis. *Semin Neurol* 2005; 25:243–51.
8. World Health Organisation. 10 facts about neurocysticercosis. <https://www.who.int/features/factfiles/neurocysticercosis/en/> (10 January 2021)
9. DeGiorgio CM, Medina MT, Durón R, Zee C, Escueta SP. Neurocysticercosis. *Epilepsy Curr* 2004; 4:107–11.
10. Burneo JG, Plener I, Garcia HH. Neurocysticercosis in a patient in Canada. *CMAJ* 2009; 180:639–42.
11. Fleury A, Hernández M, Avila M. Detection of HP10 antigen in serum for diagnosis and follow-up of subarachnoidal and intraventricular human neurocysticercosis. *J Neurol Neurosurg Psychiatry* 2007; 78:970–4.
12. Ahmad R, Khan T, Ahmad, B, Misra A, Balapure A. Neurocysticercosis: a review on status in India, management, and current therapeutic interventions. *Parasitol Res* 2017; 116:21–33.
13. Kaur S, Singhi P, and Khandelwal N. Combination therapy with albendazole and praziquantel versus albendazole alone in children with seizures and single lesion neurocysticercosis: a randomized placebo-controlled double-blind trial. *Pediatr Infect Dis* 2009; 28:403–6.
14. Nash TE, Pretell EJ, Lescano AG. Perilesional brain oedema and seizure activity in patients with calcified neurocysticercosis: a prospective cohort and nested case-control study. *Lancet Neurol* 2008; 7:1099–105.
15. Khurana S, Aggarwal A, Malla N. Prevalence of anti-cysticercus antibodies in slum, rural and urban populations in and around Union territory, Chandigarh. *Indian J Pathol Microbiol* 2006; 49:51–3.
16. Carpio A, Kelvin EA, Bagiella E. Effects of albendazole treatment on neurocysticercosis: a randomised controlled trial. *J. Neurol Neurosurg Psychiatry* 2008; 79:1050–5.
17. Keilbach NM, De Aluja AS, Sarti-Gutierrez E. A programme to control taeniasis-cysticercosis (*T. solium*): experiences in a Mexican village. *Acta Leiden* 1989; 57:181–9.