

# Paley cross union protocol for congenital pseudoarthrosis of the tibia

Panji Sananta<sup>1\*</sup>, Hasri Nopianto<sup>1</sup>

<sup>1</sup>Orthopaedics and Traumatology Department, Faculty of Medicine Universitas Brawijaya – Saiful Anwar General Hospital, Malang, East Java, Indonesia

## ABSTRACT

**Aim:** Congenital pseudoarthrosis of the tibia (CPT) is a rare, dysplastic condition causing significant disability in the lower limbs. A treatment aims to achieve long-lasting union, prevent limb length discrepancies, and prevent soft tissue lesions. Traditional surgery often yields satisfactory results, but amputation may be proposed in failed cases. This report presents a congenital pseudoarthrosis of the tibia and fibula, treated with the Paley cross-union protocol.

**Methods** A 15-month-old girl presented with a crooked right lower leg at the age of two months, history of a right lower leg fracture at the age of eight months, and pain when moving her leg. She had undergone an initial surgical procedure to maintain tibia alignment with K-Wire insertion and was cast at a private hospital.

**Results** The patient's physical examination showed a cast causing limited range of motion, but no tenderness or distal neurovascular issues. The Paley cross-union protocol was performed, involving anterior approach, curettage, and insertion of a titanium intramedullary elastic nail into the tibia. The fracture site area was covered with a meshed periosteum layer and filled with synthetic bone grafts. A long leg cast was performed after the procedure. An imaging examination post-cross-union protocol showed a good result.

**Conclusion** Cross-union for CPT represents a paradigm shift in the treatment of this horrible child disease. Given the promising result, the cross-union approach has to be regarded as a fresh criterion for treating CPT.

**Keywords:** congenital pseudoarthrosis, Paley cross union, paediatrics

## INTRODUCTION

Congenital pseudoarthrosis of the tibia (CPT) is an uncommon dysplastic disorder affecting the lower extremities, which results in substantial impairment. A tibial diaphyseal fracture that fails to heal and forms a non-union might occur without any apparent cause or may be triggered by a minor injury in a section of the bone that was already abnormal (1). The cause of CPT is still a subject of debate, and it mostly relates to the reduced ability of the pseudoarthrosis tissue to form new bone.

Approximately thirty-eight to ninety percent of these instances are associated with neurological disorders (1,2).

The occurrence of CPT ranges from 1 in 140,000 to 1 in 250,000 births, and bilateral variants are exceptionally uncommon (2,3). The illness manifests throughout infancy. Nevertheless, there is a less common form called delayed-onset variety that is initially ordinary at delivery and grows into front bending at around the ages of four and twelve years (3).

The treatment for CPT continues to be difficult. Every management seeks to achieve a durable union of the tibia and fibula to avoid discrepancies in extremity length and prevent lesions of the soft tissues, mechanical axis deviation, inflexibility of the adjacent joints, and pathological fractures (4). The typical surgery for the treatment of CPT involves the invasive procedure of the removal of pseudoarthrosis tissue, which involves damaged periosteum, with secure interior or exterior stabilization, using

\* **Corresponding author:** Panji Sananta  
Orthopaedic and Traumatology Department, Spine Division Saiful Anwar General Hospital Jaksa Agung Suprpto St. No. 2, Klojen, Malang, East Java 65112, Indonesia  
Phone: +62341 343858  
E-mail: panjisananta@ub.ac.id  
ORCID: <https://orcid.org/0000-0003-1778-6524>

either a graft that has its blood supply or a graft without a blood supply (3). In CPT situations, achieving the union is the exclusive goal of the operation. It involves treating limb length discrepancies and re-establishing the proper positioning while preserving regular articular performance (1). There is also a description of a non-invasive technique to improve union that uses electrical stimulation rather than surgery (5). Additionally, prophylactic bracing can help prevent or delay the deformity linked to this issue in a youngster who has just begun walking (1). But neither invasive nor non-invasive methods have demonstrated their advantage (6). Traditional surgery frequently yields satisfactory results; in such circumstances, an amputation might be suggested (3). This report presents a congenital pseudarthrosis of the tibia and fibula, treated with the Paley cross-union protocol.

## PATIENTS AND METHODS

### Patients and study design

A 15-month-old girl came to Dr Saiful Anwar General Hospital, on 6 July 2023 complaining about history of a crooked right lower leg, which was realized at the age of two months. On the patient's leg, there was a surgical scar on the anterior side after cast removal (Figure 1). The patient had a history of a right lower leg fracture at the age of eight months. According to her parents, the patient appeared to be in pain when moving her right lower leg. The patient had previously undergone an examination at a private hospital and had completed the initial surgical procedure to maintain the alignment of the tibia with the K-Wire insertion and cast on 5 January 2023. At the same private hospital, the implant removal was carried out on 19 June 2023.

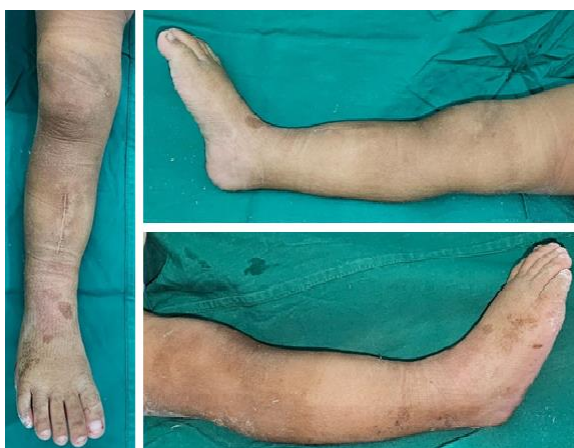

Figure 1. Clinical presentation of the affected lower leg (Dr Saiful Anwar General Hospital, 2023)

### Methods

The Paley cross-union protocol was performed. The operating procedure was done with a supine position in general anaesthesia. An anterior approach was performed from the superficial layer to the deep layer with identify tibialis anterior artery and retracted. The fibrous

hamartoma was removed from the fracture site, curettage was performed at the fracture site (Figure 2). A titanium intramedullary elastic nail with a 3mm diameter was inserted into the tibia. The fracture site area of the tibia and fibula was covered with a meshed periosteum layer from the iliac bone, and then the fracture site area was filled with a combination of synthetic bone grafts that contained rhBMP-2 and iliac bone graft. After the procedure until wound closure, a long leg cast was performed.

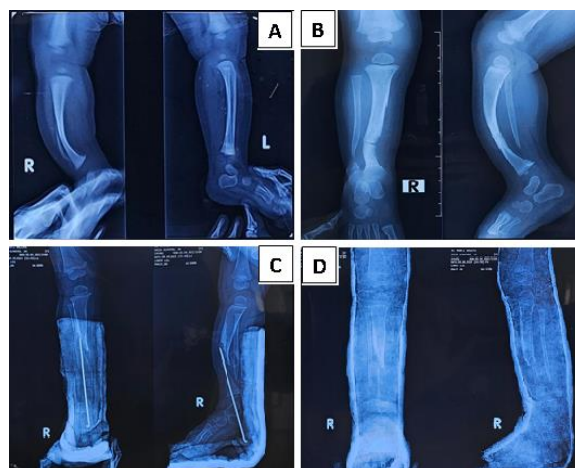


Figure 2. Right and left lower legs x-ray A) showed a bowing from the middle to the distal shaft of the tibia and fibula; B) right lower leg with the tibia fracture; C) three months after k-wire insertion; and D) post-implant removal (Dr Saiful Anwar General Hospital, 2023)

## RESULTS

The physical examination before surgery showed a cast in the lower right tibia causing limitation in the range of motion (ROM) due to the cast. There was no tenderness and distal neurovascular within normal limits. The AP/lateral lower legs X-ray examination was performed on 6 July 2023, and showed bowing from the middle to the distal shaft of the tibia and fibula, with a narrowing medullary canal at the 1/3 distal tibia, and there was a fracture line at the fibula. A fracture line at 1/3 distal tibia and angulation, atrophy, and tapering at the fracture site of the fibula and the alignment of the tibia and fibula was restored after wire replacement with atrophy, and tapering at the fracture site of the tibia and fibula (Figure 3).

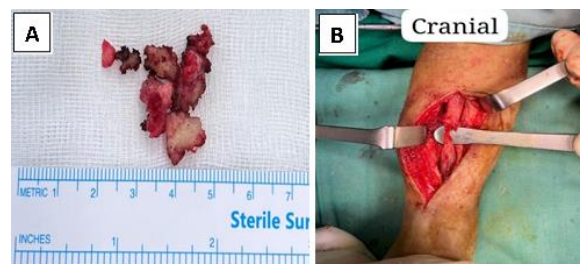
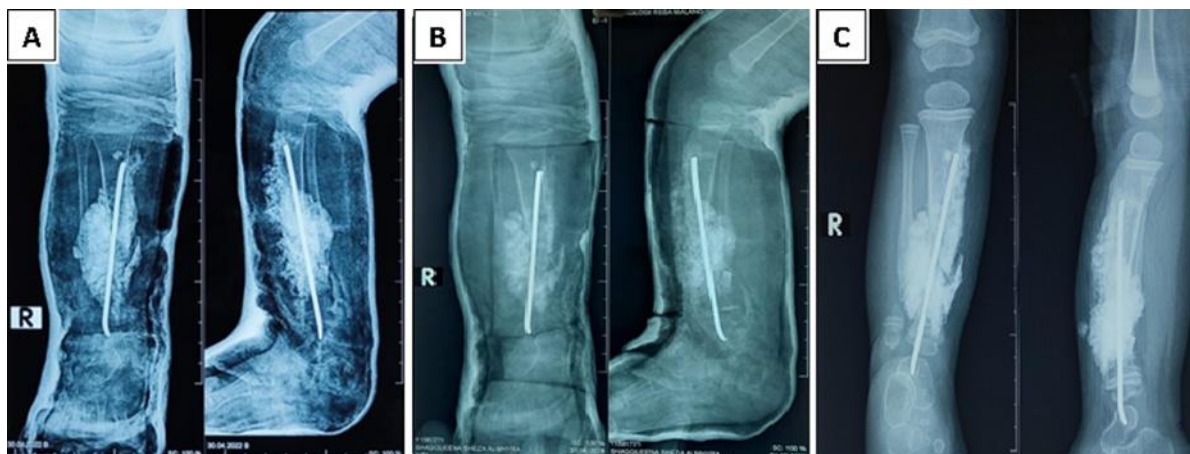


Figure 3. A) Fibrous hamartoma from the fracture site; B) pseudoarthrosis tibia. Post removal of fibrous hamartoma, fracture site seen (Dr. Saiful Anwar General Hospital, 2023)



**Figure 4.** A) Post Paley cross-union protocol with intramedullary elastic nail fixation in tibia with bone graft augmentation and cast; B) one month after Paley cross-union protocol; C) two months after Paley cross-union protocol (Dr Saiful Anwar General Hospital, 2023)

An imaging examination post Paley cross-union protocol with intramedullary elastic nail fixation in the tibia with bone graft augmentation and cast showed a good result (Figure 4).

## DISCUSSION

This report presents a congenital pseudarthrosis of the tibia and fibula treated with the Paley cross-union protocol. A long leg cast was performed. Post-surgery, an imaging examination showed a good result.

Thirteen years of follow-up utilizing the Paley cross-union protocol, adding purposeful cross-union of the tibia to the fibula boosted the triumph percentage to 100% (36/36) (7,8). Comparably, Choi et al. reported utilizing the 4-in-1 osteosynthesis approach to achieve a cross union in CPT with a triumph percentage of 100% (8/8) with a seven-point four-year follow-up (9). Similar outcomes have been reported in two more recent investigations of the cross-union management for CPT utilizing variations of techniques by 100% at 4-year follow-up (10,11).

The actual cause of CPT is unknown. However, several theories have been put up, including the notions of genetic flaws, foetal compression and amniotic band injury, nutritional shortage, hormonal disturbance, and neurovascular abnormality at the early stages of the development (2) The pathogenesis of this condition is characterized by heightened osteoclastic activity caused by signal anomalies or reduced skeleton formation due to deficiencies in the local blood supply to the skeleton (12). The disorder might be hereditary, as seen in the case of NF-1 association, or it can be caused by fibrous hamartoma and sick periosteum. The NF-1 gene is mutated in cases of CPT associated with neurofibromatosis, which results in forfeit of neurofibromin activity, upkeep of Ras-GTP, the active form of Ras, and defects in the

Ras-MAPK route that impair osteoblast differentiation (13). Additionally, osteoclastic activity rises due to the Ras pathway's overexpression, which causes bone resorption (1).

CPT is diagnosed during the initial moments of existence or at birth. It manifests as an anomaly extremity marked by the tibia's frontside bending or as a break among two skeletons that comprise the tibial part (14). Simple tibial bowing, severe bone abnormalities, including bowing in one or both leg bones, pathological fractures, and pseudoarthrosis are only a few of the disease's symptoms. The tibia bending and reduced tibial development are other causes of leg shortening (15). In NF-1-related illnesses, a thorough neurological and dermatological evaluation is also performed (1).

A routine roentgenogram is recommended as the initial diagnostic procedure. Conventional imaging displays diverse abnormalities (16). Non-union develops as a result of the gradual deterioration of the malformation. Traditional imaging may reveal a tibial skeleton that is either slim and diminished or broad and hypertrophic, generally with a concave proximal piece and a pointed distal fragment (17). This spurious articulation frequently occurs in the lower part of the shaft. However, it might appear everywhere. The fibula is commonly impacted (18). Magnetic Resonance Imaging (MRI) of CPT offers significant insights into the scope of the disease (19). An accurate definition of resection borders makes the preparation before surgery more beneficial. MRI is a suitable supplementary imaging tool that ought to be utilized alongside traditional radiography for the detection and follow-up of CPT (19). A computed tomography scan (CT) typically validates radiography observations by revealing osteolytic ulcers involving dense tissue (1). Congenital pseudoarthrosis of the tibia (CPT) treatment success is translated as union without another breakage.



Most methods, including rodding, Ilizarov, rodding plus Ilizarov, and free vascularized fibula, have a success rate of about 50%. The Paley cross-union procedure, a recent innovation, has increased this triumph to almost perfection in certain studies. The tibia and fibula are crossed together using this technique. Preoperative zoledronic acid infusion is the first step in the Paley cross-union technique. This protects the tibia, fibula, and autogenous bone graft from resorption by the hypersteoclastic cells in CPT (9). In conclusion, cross-union for CPT represents a paradigm shift in the treatment of this horrible child disease. Given the promising results, the cross-union approach has to be regarded as a fresh criterion for treating CPT, given the significant difference in success rate from 50% to 100%.

## FUNDING

No specific funding was received for this study.

## TRANSPARENCY DECLARATION

Conflict of interests: None to declare.

## REFERENCES

- 1 Agrawal U, Tiwari V. Congenital Tibial Pseudarthrosis. StatPearls, Treasure Island (FL): StatPearls Publishing; 2024.
- 2 Hefli F, Bollini G, Dungal P, Fixsen J, Grill F, Ippolito E, et al. Congenital pseudarthrosis of the tibia: history, etiology, classification, and epidemiologic data. *J Pediatr Orthop Part B* 2000;9;(1):11–5. doi: 10.1097/01202412-200001000-00003.
- 3 Shah H, Rousset M, Canavese F. Congenital pseudarthrosis of the tibia: Management and complications. *Indian J Orthop* 2012;46;(6):616–26. doi: 10.4103/0019-5413.104184.
- 4 Pierre SN, Beltran MJ. Acute shortening and angulation for complex open fractures: an updated perspective. *OTA Int Open Access J Orthop Trauma* 2023;6;(4 Suppl):e245. doi: 10.1097/OI9.0000000000000245.
- 5 Kuzyk PR, Schemitsch EH. The science of electrical stimulation therapy for fracture healing. *Indian J Orthop* 2009;43;(2):127–31. doi: 10.4103/0019-5413.50846.
- 6 Raboel PH, Bartek J, Andresen M, Bellander BM, Romner B. Intracranial Pressure Monitoring: Invasive versus Non-Invasive Methods-A Review. *Crit Care Res Pract* 2012;2012:950393. doi: 10.1155/2012/950393.
- 7 Paley D. Congenital pseudarthrosis of the tibia: biological and biomechanical considerations to achieve union and prevent refracture. *J Child Orthop* 2019;13;(2):120–33. doi:10.1302/1863-2548.13.180147.
- 8 Paley D, Robbins CA. Case 36: Congenital Pseudarthrosis of Tibia. In: Rozbruch SR, Hamdy RC, editors. *Limb Lengthening Reconstr. Surg. Case Atlas*, Cham: Springer International Publishing; 2015, p. 241–7. doi: 10.1007/978-3-319-18023-6\_35.
- 9 Paley D. Paley Cross-Union Protocol for Treatment of Congenital Pseudarthrosis of the Tibia. *Oper Tech Orthop* 2021;31;(2):100881. doi: 10.1016/j.oto.2021.100881.
- 10 Vaidya SV, Aroojis A, Mehta R, Agashe MV, Dhawale A, Bansal AV, et al. Short Term Results of a New Comprehensive Protocol for the Management of Congenital Pseudarthrosis of the Tibia. *Indian J Orthop* 2019; 53;(6):736–44. doi: 10.4103/ortho.IJOrtho\_155\_19.
- 11 Liu Y, Yang G, Liu K, Wu J, Zhu G, Tang J, et al. Combined surgery with 3-in-1 osteosynthesis in congenital pseudarthrosis of the tibia with intact fibula. *Orphanet J Rare Dis* 2020;15;(1):62. doi: 10.1186/s13023-020-1330-z.
- 12 Feng X, McDonald JM. Disorders of bone remodeling. *Annu Rev Pathol* 2011;6:121–45. doi: 10.1146/annurev-pathol-011110-130203.
- 13 Wang W, Wei C-J, Cui X-W, Li Y-H, Gu Y-H, Gu B, et al. Impacts of NF1 Gene Mutations and Genetic Modifiers in Neurofibromatosis Type 1. *Front Neurol* 2021; 12:704639. doi: 10.3389/fneur.2021.704639.
- 14 Cariello V, Smaldone MC, Durante A, Pizzicato P, Rossi A, Minelli R, et al. Congenital tibial pseudarthrosis: A challenge in pediatric radiology. *Radiol Case Rep* 2024;19;(6):2502–7. doi: 10.1016/j.radcr.2024.03.045.
- 15 Khan T, Joseph B. Controversies in the management of congenital pseudarthrosis of the tibia and fibula. *Bone Jt J* 2013;95-B;(8):1027–34. doi: 10.1302/0301-620X.95B8.31434.
- 16 Pineda C, Espinosa R, Pena A. Radiographic imaging in osteomyelitis: the role of plain radiography, computed tomography, ultrasonography, magnetic resonance imaging, and scintigraphy. *Semin Plast Surg* 2009;23;(2):80–9. doi: 10.1055/s-0029-1214160.
- 17 Sharun K, Pawde AM, Banu S A, Manjusha KM, Kalaiselvan E, Kumar R, et al. Development of a novel atrophic non-union model in rabbits: A preliminary study. *Ann Med Surg* 2021;68:102558. doi: 10.1016/j.amsu.2021.102558.
- 18 Walters B, Constant D, Anand P. Fibula fractures. *Treasure Island (FL): StatPearls Publishing*; 2023.
- 19 van Beek EJR, Kuhl C, Anzai Y, Desmond P, Ehman RL, Gong Q, et al. Value of MRI in medicine: More than just another test? *J Magn Reson Imaging JMRI* 2019; 49;(7):e14–25. doi: 10.1002/jmri.26211.

**Publisher's Note** Publisher remains neutral with regard to jurisdictional claims in published maps and institutional affiliations