

A new plate design to treat displaced 3-4 parts proximal humeral fractures in comparison to the most tested and used plate: clinical and radiographic study

Giuseppe Rollo¹, Giuseppe Porcellini², Roberto Rotini³, Michele Bisaccia⁴, Paolo Pichierri¹, Paolo Paladini⁵, Enrico Guerra³, Enio De Cruto¹, Raffaele Franzese⁶, Predrag Grubor⁷, Valerio Pace⁴, Luigi Meccariello¹

¹Department of Orthopaedics and Traumatology, Vito Fazzi Hospital, Lecce, ²Department of Orthopaedics and Traumatology, University of Modena and Reggio Emilia, Modena, ³Shoulder and Elbow Unit, "Rizzoli" Orthopaedic Institute, Bologna, ⁴Division of Orthopaedics and Trauma Surgery, University of Perugia, "S. Maria della Misericordia" Hospital, Perugia, ⁵Shoulder and Elbow Unit, "D. Cervesi" Hospital, Cattolica-AUSL della Romagna, Ambito Rimini, ⁶Multidisciplinary Department of Medical-Surgical and Dental Specialties, University of Campania "Luigi Vanvitelli", Naples; Italy, ⁷School of Medicine, University of Banja Luka, Bosnia and Herzegovina

ABSTRACT

Aim Proximal humeral fractures are common and most complex patterns currently represent a challenge for surgeons. Difficulties in obtaining good anatomical reduction (particularly of great tuberosity) often lead to unsatisfactory results; choices often fall onto prosthesis implantation against fixation options. The aim of this study was to compare a new design of proximal humeral plate with the most used plates in the treatment of these injuries by analysing outcomes and complications.

Methods Two hundred patients with proximal 3 or 4 parts humeral fracture were enrolled (Neer 3-4). First group treated with PGR Plate composed of 98 patients. Second group treated with Philos Plate composed of 102 patients. Evaluation criteria were Non-Union Scoring System, duration of surgery, complications, objective quality of life and elbow function (Constant Shoulder Score), subjective quality of life and elbow function (Oxford Shoulder Score), post-op radiographs, centrum collum diaphyseal angle. Evaluation endpoint was 12 months.

Results There was no statistically significant difference between the groups with regard to the selected evaluation parameters. Achievement of good shoulder range of motion and ability to perform normal daily living activities was obtained in both groups. The PGR had a positive impact on treatment results of varus-pattern of proximal humeral fractures.

Conclusions The PGR allowed good clinical and radiographic results in the treatment of proximal humeral fractures, comparable to those obtained with Philos. Also, PGR had the advantage to aid and keep the anatomical reduction of patterns of fracture involving the greater tuberosity.

Key words: device design, internal fracture fixation, metal plating, proximal humeral fractures

Corresponding author:

Luigi Meccariello

Department of Orthopaedics and Traumatology, Vito Fazzi Hospital

Piazzetta Filippo Muratore,

Block: A- Floor: V, Lecce, Italy

Phone: +39 329 941 9574;

Fax: +39 082 371 3864;

E-mail: drlordmec@gmail.com

ORCID ID: <https://orcid.org/0000-0002-3669-189X>

Original submission:

29 April 2019;

Revised submission:

07 May 2019;

Accepted:

30 May 2019.

doi: 10.17392/1033-19

Med Glas (Zenica) 2019; 16(2): 284-291

INTRODUCTION

Humeral fractures are common in the general population. They comprise approximately 7–8% of all adult fractures in the Western world and their incidence has been reported to increase with age (1). The overall incidence of humeral fractures was 104.7 per 100,000 inhabitants per year, with a segment-specific incidence of 83.0 for proximal fractures, 13.4 for shaft fractures and 8.3 per 100,000 person-years for distal fractures (1). There was a distinct increase in the age-specific incidence from the fifth decade and onwards, regardless of fracture site. Most fractures occurred in older patients (83% >50 years) as a result of a simple or an unspecified fall (79% >50 years). Only 1.2% of all fractures were open injuries and 1.3% were pathological (1-3).

The complex fractures (Neer type 3 or 4) today represent a challenge for orthopaedic surgeons. The difficulty in obtaining a good anatomical reduction (particularly the difficult reduction of the great tuberosity) often leads to rather poor postoperative results, and discourages the option of a synthesis for the benefit of a prosthetic choice (4-5). The Golden standard for osteosynthesis in 3 or 4 part fragment fractures according to Neer's Classification in proximal humeral fracture is the use of a plating surgical procedure (6).

The aim of our study was to compare a new design and profile proximal humeral plate (PGR plate) with the most used plate in the treatment of these injuries (Philos Plate) with regard to postoperative clinical and radiographic outcomes and complications, particularly focusing on Neer type 3 and 4 fractures which have a higher percentage of postoperative failure and are the most challenging pattern of fracture to treat.

PATIENTS AND METHODS

Patients and study design

From January 2014 to December 2016, a total of 684 proximal humeral fractures were admitted and surgically treated in 7 Trauma Level I Centres (Italy). From these 684 proximal humeral fractures, 200 patients were finally enrolled and included.

Exclusion criteria were: previous upper limb trauma, bilateral humeral injuries, nerve injuries, vessels injuries, fractures of one or two fragments according to Neer's Classification, under

16 years of age, haematological or oncological pathologies, bone metabolism diseases, shoulder osteoarthritis, rheumatoid metabolism disease, contraindications to surgical management. These 200 patients were surgically treated with open reduction and internal fixation of the fracture through a deltopectoral approach, and were divided into two groups: Group 1 if they were treated with PGR Plate (Intrauma s.p.a.) and Group 2 if treated with Philos Plate (Intrauma s.p.a.). The choice of the attribution of the patients to the two groups was based on the experience of the surgeon. The total cost of PGR Plate for the hospital was 1047.00 Euro, while the total cost of Philos Plate for the hospital was 1049.00 Euro.

All 200 fractures were classified according to Neer's classification for proximal humerus fractures (7).

The first group (PGR) was composed of 98 patients with average age of 74 ± 12 (range 16-92) and gender ratio (males:females, M:F) was 0.48 (32:66). The mechanisms of injury were accidental fall for 68 (69.39%), traffic accident for 12 (12.24%), work accident for 18 (18.37%) patients. The types of fractures according to Neer's classification (7) were III fragments, 55 (56.12%) and IV fragments, 43 (43.88%). The most affected side was the left, in 64 (65.31%) patients. The most affected dominant side was the left side, in 18 (18.37%) patients.

The second group (Philos) was composed of 102 patients whose average age was 74 ± 12 years (range 16-92) and gender ratio (M:F) was 0.5 (34:68). The mechanisms of injury were accidental fall for 69 (67.65%), traffic accident for 14 (13.72%), work accident for 19 (18.63%) patients. The types of fracture according to Neer's classification (7) were III fragments, 56 (54.90%), and IV fragments, 46 (45.10%). The most affected side was the left, in 68 (66.67%) patients. The most affected dominant side was the left side, in 19 (18.63%) patients.

To understand and study the capacity of bone healing in patients, we used the Non-Union Scoring System (NUSS) in retrospective mode (8) and the Radiographic Bone Healing measured by RUS (Radiographic Union Score).

All patients of the two groups have undergone the same postoperative rehabilitation protocol, divided in 3 phases. During Phase 1 (first 4 weeks) immobilization support was allowed, pendulum

exercises, gently assisted passive motion and avoidance of external rotations (up to 6 weeks). During Phase 2 (approximately weeks 5-9), in presence of evidence of healing, with fragments moving as a unit and with no displacement visible on radiographs, active-assisted forward flexion and abduction, gentle functional use (no abduction against resistance), gradual reduction of assistance during motion were allowed. During Phase 3 (after week 9) isotonic, concentric and eccentric strengthening exercises were allowed. In the presence of significant joint stiffness with contemporary presence of bone healing, passive assisted stretching exercises were added.

All patients of the two groups were informed in a clear and comprehensive way of the type of treatment and other possible surgical and conservative alternatives. Patients were treated according to the ethical standards of the Helsinki Declaration, and were invited to read, understand, and sign the informed consent form.

The chosen criteria to evaluate the two groups during the clinical and radiological follow-up were: the proximal humeral complication after the two types of surgery, the duration of surgery, objective quality of life and elbow function measured by Constant Shoulder Score (CSS) (9), while the subjective quality of life and the elbow function were measured by Oxford Shoulder Score (OSS) (10). The bone healing was measured by radiograph control as the alignment was measured by the centrum collum diaphyseal angle (CCD) (11) using the same radiograph control.

The evaluation endpoint was set at 12 months. Full clinical examination and check plain radiograph were performed during all follow-up appointments.

Methods

PGR's Surgical Techniques. A deltopectoral approach was used in all cases as it was considered to be the best approach that was able to allow appropriate fracture reduction and fixation of proximal III or IV parts humeral fractures. After soft tissue dissection and good fracture site exposure, adequate reduction of the fracture was achieved. Non-absorbable suture wires were placed through the insertions of each rotator cuff tendon in order to increase stability. The placement of the suture is recommended (together with plate

and screws) particularly in case of more comminuted and/or osteoporotic fractures. In the presence of osteoporotic bone, the tendon insertion is often stronger than the bone itself, so such sutures should be placed through the insertional fibres of the tendon and may hold better than screws or sutures placed through bone. A PGR plate of appropriate size is then positioned at fracture site. Suture wires are then slipped into the 1.5 mm holes of the PGR plate, positioned anatomically under fluoroscopy control (always laterally to the groove), wires are tensioned appropriately. Screws are then positioned to stabilize the plate. The first screw should be positioned at the level of the greater tuberosity, the second screw into the elongated hole that allows us to adjust the length and the position of the fracture diaphysis fragment and plate. Then synthesis was completed with proximal screws followed by distal screws. Calcar screws or kickstand screw could be useful to support the medial wall and prevent a fixation in varus. Finally the non-absorbable wires should be sutured with the plate. Fluoroscopy images should be used throughout and at the end of the fixation to check metalwork position. When good fixation is achieved, the procedure was completed with abundant lavage, accurate final haemostasis and closure in layers (Figure 1).

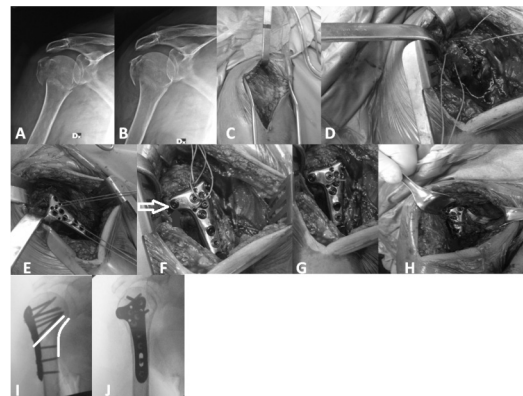


Figure 1. A, B) Three parts fracture of right proximal humerus, 36-year-old male, fallen from height, C) deltopectoral approach, D) non-absorbable suture wires through greater tuberosity, E) placement of wires and plate, F) placement of plate and screws, F) screw that directly stabilizes the large tuberosity (white arrow), G) nodding closure and non-absorbable wires, H) view of the synthesis before closure, I, J) post-op radiographs show good reduction of the medial wall (I, curved white line) green and the importance of the kickstand screw (I, straight white line) (Rollo G,2016).

Philos's surgical techniques. The same approach and surgical exposure and preparation performed for PGR technique was also used for

Philos technique. After positioning of the sutures wires through the insertion of rotator cuff tendons, suture wires are then slipped into the 1.4 mm holes of the Philos plate, positioned anatomically (laterally to the groove) under fluoroscopy control, and good tension of the wires is then sought. If the first screw is inserted only loosely in the centre of the elongated hole, fine-tuning of the plate position is still possible. When the plate achieved a satisfactory position, screws were securely tightened. Five screws were placed into the humeral head and then in distal holes. At last calcar screws or kickstand screw should be placed to support the medial wall and prevent a fixation in varus. Finally the non-absorbable wires should be sutured with the plate. Fluoroscopy images should be used throughout and at the end of the fixation to check metalwork position. When good fixation is achieved, the procedure was completed with abundant lavage, accurate final haemostasis and closure in layers (Figure 2).

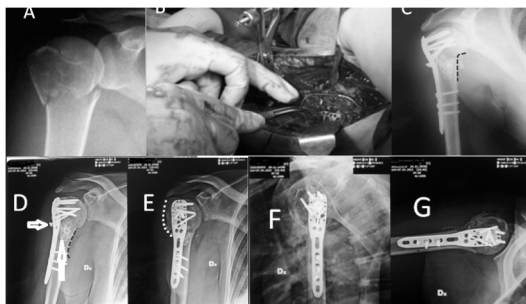


Figure 2. A) Three parts fracture of right proximal humerus, 53-year-old female fallen from a step, B) placement of wires and plate, C) post-surgery radiograph showed good reduction of medial inch (dotted red line) with Philos and augmentation, D) radiographs after 12 months from surgery showed the pull out of the kickstand screw (white arrow) and loss of medial inch (dotted black line), incomplete bone healing (upwards white line), E) unsatisfactory reduction of greater tuberosity (white dotted line), F, G) posterior rotation of the humeral head (Rollo G, 2014).

Rehabilitation protocol. The purpose of our protocol was to provide the clinician with an orientation of the postoperative course of rehabilitation, and rationalize and have the entire patient population conform to a single physio-kinesiotherapy program in order to reduce bias. All patients were provided with the same rehabilitation algorithm as described above.

Statistical analysis

Descriptive statistics were used to summarize the characteristics of the study group and subgroup-

ps, including means and standard deviations of all continuous variables. The t-test was used to compare continuous outcomes. The χ^2 -test or Fisher's exact test (in subgroups smaller than 10 patients) were used to compare categorical variables. The statistical significance was defined as $p < 0.05$. Pearson correlation coefficient (r) was used to compare the predictive score of outcomes and quality of life. Mean age (and the range) of the patients was rounded at the closest year. The predictive score of outcomes and quality of life and their ranges were approximated at the first decimal while at the second decimal Pearson correlation coefficient (r) was approximated. The reliability and validity of the correlation between functional outcome results CCD were determined by the Cohen's kappa (k).

RESULTS

There was no statistically significant difference between the two groups with regard to the selected evaluation parameters. At the endpoint the complication in PGR were: varus healing in 16 (16.33%) cases, humeral head necrosis in five (5%), non-union in five (5%), screw cut out in four (4%) cases. Complications in Philos at the endpoint were: varus healing in 22 (10%), humeral head necrosis in five (5%), non-union six (6%), screw cut out in five (5%) cases. There was no statistically significant difference ($p = 0.09$) in varus healing in favour of the PGR group. The average duration of surgical time in the PGR group was 45 ± 24 (range 62 -123) minutes; in the Philos group it was 47 ± 24 (range 59 -126) minutes. The PGR's radiographic bone healing measured by RUS was on average of 92 ± 11 (range 62 -123) days after surgery, while Philos's radiographic bone healing was on average 92 ± 11 (range 62 -123) days after surgery.

At the twelfth month from the surgery, arc of flexion-extension averaged $106^\circ \pm 23^\circ$ in the PGR group and $112^\circ \pm 19^\circ$ in the Philos group.

At the twelfth month from the surgery, arc of flexion was averaged 138° (range 67° – 180°) in the PGR group and 136° (range 66° – 180°) in the Philos group. The arc of extension was the of same average of 42° (range: 30° – 54°) for PGR and Philos group. The arch of abduction was of the same average of 147° (range 69° – 180°) for both the PGR and Philos group. The arc of in-

trarotation was of an average of 55° (range 25°–65°) in PGR while 53° (range 25°–65°) in Philos group. The arc of extrarotation was of an average of 79° (range 25°–90°) in PGR and 78° (range 25°–90°) in Philos group (Table 1).

Table 1. Description of results

Variable	PGR®	Philos®
Average surgical time in minutes	45 (±24; range 62-123)	47 (±24; range 59-126)
Average time in days of X-rays Bone healing	92 (±11; range 62-123)	92 (±11; range 62-123)
Type of complications	Varus Healing: 16 (16%)	Varus Healing: 22*(10%)
	Head necrosis: 5 (5%)	Head necrosis: 5(5%)
Type of complications	Non-union: 5 (5%)	Non-union: 6 (6%)
	Screw cut out: 4 (4%)	Screw cut out: 5 (5%)
Arc of flexion	138° (range 67°–180°)	136° (range 66°–180°)
Arc of extension	42° (range:30°–54°)	41° (range:30°–54°)
Arc of abduction	147° (range 69°–180°)	147° (range 70°–180°)
Arc of intrarotation	55° (range 25°–65°)	53° (range 25°–65°)
Arc of extrarotation	79° (range 25°–90°)	78° (range 25°–90°)
Average centrum collum diaphyseal angle(CDD) in normally healed fracture	132°(range 130-135°)	131°(range 130-135°)
Average centrum collum diaphyseal angle(CDD) in nonunion or deformities healed fracture	106°(range 74-126°)	105°(range 72-127°)
Correlation between clinical-radiographic results and patients' outcomes (SD)	k=0.71±0.19	k=0.71±0.18

The CCD of the normally healed fracture was 132° (range 130-135) in PGR while it was 131° (range 130-135) in Philos group. The CCD of the non-union or deformities fracture was 106° (range 74-126°) in PGR while it was 131°(range 72-127°) in the Philos group (Table 1).

The objective quality and shoulder function of PGR's life before the trauma measured by CSS, was about 84.4 points (range 56-100), while the quality of life before the trauma, measured by CSS was about 84.2 points (range 58-100) in Philos group (Figure 3). At the time of trauma in the PGR group CSS was 16.3 (range 5-25), while CSS was 16.2 (range 5-25) in Philos. After 1 month from the surgery the CSS score was 33.7 (range 22-60) PGR and 33.8 (range 20-60) in Philos. Also three months after the surgery (p>0.05), difference at three CSS scores was 58.7 in PGR

(range 35-80) and 58.3 in Philos (range 25-80), as well as on the sixth month of follow-up.

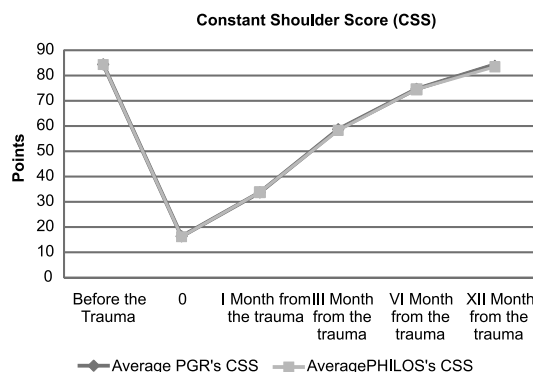


Figure 3. Trend of Constant Shoulder Score (CSS) pre-trauma and at 1 year post-trauma. No statistical difference between PGR and Philos group 12 months after surgery

At 6 months from the revision surgery, CSS was 74.7 (range 45-95) in PGR, while in Philos it was 74.5 (range 45-95) (Figure 3).

At twelve months after the surgery we had a CSS score of 84.3 (range 55-100) in PGR, while in Philos it was 83.4 (range 55-100) (Figure 3).

The subjective quality and shoulder function of PGR's life before the trauma, measured by OSS, was about 88.4 points (range 68-100), while the quality of life before the trauma, measured by OSS, was about 87.3 points (range 60-100) in Philos (p=0.50 (Figure 4). At the time of trauma, in PGR group the OSS was 12.1 (range 8-24), while it was 13.5 (range 8-26) in Philos (p=0.50). After 1 month from the surgery the OSS score was 34.7 in PGR (range 18-64) and 35.2 (range 22-62) in Philos (p=0.50). Also three months after the surgery, difference at three OSS score was 65.7 in PGR (range 32-82) and 64.9 in Philos (range 32-84), as well as on the sixth month of follow-up (p=0.50).

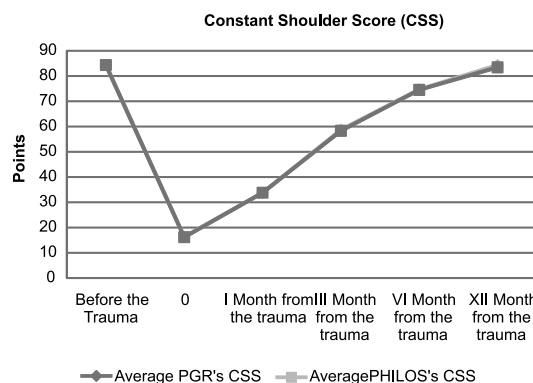


Figure 4. Trend of Subjective Oxford Elbow Score (OES) pre-trauma and 12 months after trauma. No statistical difference between PGR and Philos group 12 months after surgery

At 6 months from the revision surgery, in PGR the OSS was 76.4 (range 48-90), while in Philos it was 76.3 (range 50-90) ($p=0.50$) (Figure 4).

At twelve months after the surgery OSS score of 82.3 in PGR (range 62-100) and 81.8 in Philos (range 60-98) was noticed ($p=0.50$) (Figure 4).

Functional and clinical results were satisfactory both if taken singularly or in correlation.

The average point of the NUSS in PGR was 45 ± 15.74 (range 15-65); similarly the average point of NUSS in Philos was 45 ± 15.79 (range 15-50).

A correlation of clinical results showed $k=0.71\pm 0.19$ in PGR and $k=0.71\pm 0.18$ in Philos (Table 1).

DISCUSSION

The incidence of isolated greater tuberosity fractures has been estimated to be 20% of all proximal humeral fractures. It is generally accepted that displaced (>5 mm) fractures should be treated surgically but the optimal surgical fixation of greater tuberosity fractures remains unclear (12). Fractures with 3 or 4 fragments get always complicated by a displacement and poly-fragmentation of the great tuberosity (1-7). Failed fixation and displacement of the greater tuberosity in the early postoperative period may result in malunion, diminished range of motion, impingement and loss of shoulder strength and function (13). Methods to stabilize the greater tuberosity and counteract the deforming forces of the rotator cuff have been previously described (13). For only great tuberosity, the calculations were performed in a way so that the total applied force resulted in a maximum stress of 816 N/mm². The findings indicated that the most critical points of the Kaisidis system are screws that are connected to the bone (12). The maximal force generated by the supraspinatus tendon was 784 N, which is higher than the minimal acceptable force (12) and the results of the FEM analysis showed that the maximal supraspinatus force was 11.6% higher than the minimal acceptable force. As such, the load would exceed twice the amount of maximal force required to tear the supraspinatus tendon, before the screw or the plate would show first signs of plastic deformation. Instead three-four part proximal humeral fracture have an amount of strength pluri-directional displacement forces that they can break the plate fixation (14). From

a review of the literature and laboratory studies Jabran et al. concluded that overall, Philos was the most tested plate in the literature and locking plates in general demonstrated better mechanical performance than non-locking ones. Conflicting results have been published for their comparison with non-locking blade plates and polyaxial locking screws. Augmentation with cement, calcium phosphate or poly(methyl methacrylate) (14), or allografts (fibular and femoral head) was found to improve bone-plate constructs' mechanical performance (15-16). Controversy still lies over the use of rigid and semi-rigid implants and the insertion of inferomedial screws for calcar region support. There is paucity of work with regards to the use of PGR plate for the treatment of proximal humeral fractures (14). In the biomechanical paper of Palumbo et al. (13) it was shown that suture-augmentation of the greater tuberosity to the rotator cuff could provide greater stability than locked plating alone. This study provides a biomechanical basis of evidence in favour of reinforcing locked plate constructs with sutures. The added stability afforded by suture-augmentation may mitigate rotator cuff forces in the clinical setting, avoiding fracture displacement in the early postoperative rehabilitation period (14). Why did we find a difference in fragment displacement, complications, hardware failure, malunion and other functional and clinical results between PRG and Philos? The answer lies in the ability of the blocked colour-stopping screws which synthesize the large tuberosity. In fact, if we look at biomechanics studies on the exclusive plates used to stabilize the greater tuberosity, we find that an important aspect for this type of fixation is the risk of screw loosening with a screw blocked in the plate (12,17). Thus we conclude that particular attention should be given to reinforcing the plate with sutures in order to obtain the best possible fixation stability.

The results we obtained in our study do not differ from what modern scientific literature reports. Similarly, the complication rate and the type of complications are in accordance with what is shown in the literature (1-7, 18-34). Nevertheless, our results differ significantly among the two studied groups. The only statistically positive difference between the two groups was found in the sub-group of postoperative varus healing in favour of the PGR group, which seems to provi-

de a more satisfactory stability and appropriate bone healing. This is probably due to PGR ability to counteract the disruptive forces that act on the large fractured greater tuberosity (12,13,17).

High level biomechanical and/or clinical studies on results of the use of PGR are not available yet. Our results show that PGR is a reliable and feasible option to treat proximal humeral fractures classified as Neer 3-4. A significant role is played by the capacity of this plate to anatomically reduce the fracture at the level of greater tuberosity and provide a stable fixation. This seems to be the main difference compared to results obtained with the Philos plate, while the rest of clinical, functional and radiographic results seem to be overlapping. However, further studies are necessary to confirm our hypothesis.

The limitations of the current study were the limited number of patients, non-probability sample of convenience due to few centric samples, Level 1 Trauma Centre. Being a retrospective study could be considered another limit. Disadvantages of retrospective studies: inferior level of evidence compared with prospective studies; subject to confounding other risk factors may be present that were not measured; inability to determine causation, only association; some key statistics cannot be measured. Selection of patients may be bias, making generalization of results difficult. It may be unclear whether the confluence of findings is merely a chance occurrence or is truly characteristic of a new disease or syndrome.

REFERENCES

1. Bergdahl C, Ekholm C, Wennergren D, Nilsson F, Möller M. Epidemiology and patho-anatomical pattern of 2,011 humeral fractures: data from the Swedish Fracture Register. *BMC Musculoskeletal Disord* 2016; 17:159.
2. Singh A, Adams AL, Burchette R, Dell RM, Funahashi TT, Navarro RA. The effect of osteoporosis management on proximal humeral fracture. *J Shoulder Elbow Surg* 2015; 24:191-8.
3. Bahrs C, Stojicevic T, Blumenstock G, Brorson S, Badke A, Stockle U, Rolauffs B, Freude T. Trends in epidemiology and patho-anatomical pattern of proximal humeral fractures. *Int Orthop* 2014; 38:1697-704.
4. Sproul RC, Iyengar JJ, Devcic Z, Feeley BT. A systematic review of locking plate fixation of proximal humerus fractures. *Injury* 2011; 42:408-13.
5. Dai J, Chai Y, Wang C, Wen G. Meta-analysis comparing locking plate fixation with hemiarthroplasty for complex proximal humeral fractures. *Eur J Orthop Surg Traumatol* 2014; 24:305-13.
6. Handoll HH, Brorson S. Interventions for treating proximal humeral fractures in adults. *Cochrane Database Syst Rev* 2015:CD000434.
7. Carofino BC, Leopold SS. Classifications in brief: the Neer classification for proximal humerus fractures. *Clin Orthop Relat Res* 2013; 471:39-43.
8. Calori GM, Colombo M, Mazza EL, Mazzola S, Malagoli E, Marelli N, Corradi A. Validation of the Non-Union Scoring System in 300 long bone non-unions. *Injury* 2014; 45(Suppl 6):S93-7.
9. Ban I, Troelsen A, Christiansen DH, Svendsen SW, Kristensen MT. Standardised test protocol (Constant Score) for evaluation of functionality in patients with shoulder disorders. *Dan Med J* 2013; 60:A4608.

Another limitation was that the measurements and interventions were made without randomization of the researcher to the experimental groups, which have potential for bias. Finally other limiting factors of the study acknowledged by the authors can be: a potential for regression to the mean, presence of temporal confounders and mention of subjective score.

In conclusion, the PGR allows good clinical and radiographic results in the treatment of proximal humeral fractures comparable to those obtained with Philos. The PGR also have the advantage to aid and keep the anatomical reduction of patterns of fracture involving greater tuberosity. No significant difference in terms of costs is present among PGR and Philos, therefore, surgeons should decide among the two on the basis of their experience, but efforts should be made to increase the use of PGR given the above mentioned advantages, especially with the fracture involving greater tuberosity. Patients undergoing the studied procedure are able to achieve satisfactory functional levels, with good range of motion and quality of life. A higher level of evidence from biomechanical and clinical studies is needed in order to validate or reject our results.

FUNDING

No specific funding was received for this study.

TRANSPARENCY DECLARATION

Conflict of interest: None to declare.

10. Dawson J, Rogers K, Fitzpatrick R, Carr A. The Oxford shoulder score revisited. *Arch Orthop Trauma Surg* 2009; 129:119-23.
11. Hertel R, Knothe U, Ballmer FT. Geometry of the proximal humerus and implications for prosthetic design. *J Shoulder Elbow Surg* 2002; 11:331-8.
12. Kaisidis A, Pantos PG, Bochlos D, Lindner H. Biomechanical analysis of the fixation strength of a novel plate for greater tuberosity fractures. *Open Orthop J* 2018; 12:218-28.
13. Palumbo B, Gutierrez S, Santoni B, Mighell, M. Biomechanical investigation of locked plate fixation with suture augmentation in a comminuted three-part proximal humerus fracture model. *Open Journal of Orthopedics* 2017; 7:180-91.
14. Jabran A, Peach C, Ren L. Biomechanical analysis of plate systems for proximal humerus fractures: a systematic literature review. *Biomed Eng Online* 2018; 17:47.
15. Matassi F, Angeloni R, Carulli C, Civinini R, Di Bella L, Redl B, Innocenti M. Locking plate and fibular allograft augmentation in unstable fractures of proximal humerus. *Injury* 2012; 43:1939-42.
16. Rollo G, Rotini R, Pichierri P, Giaracuni M, Stasi A, Macchiarola L, Bisaccia M, Meccariello L. Grafting and fixation of proximal humeral aseptic non union: a prospective case series. *Clin Cases Miner Bone Metab* 2017; 14:298-304.
17. Longxiang S, Wei Z, Qiuke W, Yunfeng C. Establishment of a three-dimensional finite element model and biomechanical analysis of three different internal fixation methods for humeral greater tuberosity fracture. *Int J Clin Exp Med* 2018; 11:3245-54.
18. Schumaier A, Grawe B. Proximal Humerus Fractures: Evaluation and Management in the Elderly Patient. *Geriatr Orthop Surg Rehabil* 2018; 9:2151458517750516.
19. McMillan TE, Johnstone AJ. Primary screw perforation or subsequent screw cut-out following proximal humerus fracture fixation using locking plates: a review of causative factors and proposed solutions. *Int Orthop* 2018; 42:1935-42.
20. Arroyo-Sánchez C, Abril-Gaona C, Rincón-Cardozo D. Osteosynthesis with locking plate and minimally invasive technique for proximal humeral fractures. *Acta Ortop Mex* 2017; 31:18-23.
21. Bogdan Y, Gausden EB, Zbeda R, Helfet DL, Lorch DG, Wellman DS. An alternative technique for greater tuberosity fractures: use of the mesh plate. *Arch Orthop Trauma Surg* 2017; 137:1067-70.
22. Goch AM, Christiano A, Konda SR, Leucht P, Egol KA. Operative repair of proximal humerus fractures in septuagenarians and octogenarians: Does chronological age matter? *J Clin Orthop Trauma* 2017; 8:50-3.
23. McPhillamy A, Gurnea TP, Moody AE, Kurnik CG, Lu M. The clinical and economic impact of generic locking plate utilization at a Level II Trauma Center. *J Orthop Trauma* 2016; 30(Suppl 5):S32-6.
24. Steinhaus ME, Dare DM, Gulotta LV. Displaced proximal humerus fractures: is a sling as good as a plate? *HSS J* 2016; 12:287-90.
25. Jawa A, Burnikel D. Treatment of proximal humeral fractures: a critical analysis review. *JBJS Rev* 2016; 4. pii: 01874474-201601000-00002.
26. Kathrein S, Joeris A, Kralinger F, Blauth M, Goldhahn J. Significant differences between local reporting and central assessment of radiographic complications in a prospective, multicenter study about locking plate fixation of proximal humerus fractures. *J Orthop Trauma* 2016; 30:e336-9.
27. Panagopoulos A, Tatani I, Ntourantonis D, Seferlis I, Kouzelis A, Tyllianakis M. Least possible fixation techniques of 4-part valgus impacted fractures of the proximal humerus: a systematic review. *Orthop Rev (Pavia)* 2016; 8:6211.
28. Dilisio MF, Nowinski RJ, Hatzidakis AM, Fehringer EV. Intramedullary nailing of the proximal humerus: evolution, technique, and results. *J Shoulder Elbow Surg* 2016; 25:e130-8.
29. Capriccioso CE, Zuckerman JD, Egol KA. Initial varus displacement of proximal humerus fractures results in similar function but higher complication rates. *Injury* 2016; 47:909-13.
30. Kathrein S, Joeris A, Kralinger F, Blauth M, Goldhahn J. Significant differences between local reporting and central assessment of radiological complications in a prospective, multicenter study about locking plate fixation of proximal humerus fractures. *J Orthop Trauma* 2015.
31. Song JQ, Deng XF, Wang YM, Wang XB, Li X, Yu B. Operative vs. nonoperative treatment for comminuted proximal humeral fractures in elderly patients: a current meta-analysis. *Acta Orthop Traumatol Turc* 2015; 49:345-53.
32. Mao F, Zhang DH, Peng XC, Liao Y. Comparison of surgical versus non-surgical treatment of displaced 3- and 4-part fractures of the proximal humerus: a meta-analysis. *J Invest Surg* 2015; 28:215-24.
33. Cruickshank D, Lefaivre KA, Johal H, MacIntyre NJ, Sprague SA, Scott T, Guy P, Cripton PA, McKee M, Bhandari M, Slobogean GP. A scoping review of biomechanical testing for proximal humerus fracture implants. *BMC Musculoskelet Disord* 2015; 16:175.
34. Meller R, Hawi N, Schmidem U, Millett PJ, Petri M, Krettek C. Posttraumatic nonunions and malunions of the proximal humerus. Possibilities and limitations of corrective osteotomy. *Unfallchirurg* 2015; 118:577-85.