

Peritoneal and upper genital tract tuberculosis

Alexandra Wagner¹, Ruža Arsenić², Matthias David¹, Jalid Sehoul¹, Domagoj Vidosavljević³, Irena Rohr¹

¹Gynecological Tumour Centre and European Competence Centre for Ovarian Cancer, ²Institute of Pathology; Charité Universitätsmedizin Berlin, Germany, ³County General and Croatian War Veterans Hospital, Vukovar, Croatia

ABSTRACT

Aim To present diagnostic and therapeutic possibilities for genital and peritoneal tuberculosis, mimicking to other pathological conditions, mainly, ovarian cancer.

Methods Transabdominal and transvaginal ultrasound, computerized tomography, Ca125 and HE 4, ROMA- index (Risk of Ovarian Malignancy Algorithm index) and diagnostic laparoscopy were performed in order to diagnose genital tuberculosis in a female patient.

Results: A 23-year-old woman from Morocco presented with intermittent abdominal pain, unintentional weight loss and primary infertility. There was no positive family history for breast or ovarian cancer and no history of previous tuberculosis (TB). Elevated CA-125 level, HE 4 normal, ROMA-Index of 13.2 % suggested high risk for epithelial ovarian cancer (EOC). Ultrasound revealed free fluid, dilated fallopian tubes and a cystic mass near the right ovary. Suspecting fallopian tube or ovarian cancer, we performed exploratory laparoscopy, revealing adhesions, multiple miliary nodes and dilated fallopian tubes. Histological investigation revealed granulomatous abscessing salpingitis with suspicion of genital TB, so antituberculous therapy was administered with success.

Conclusion Female genital tuberculosis is very rare but important in differential diagnosis and should be kept in mind regarding suspected fallopian tube or ovarian carcinoma to prevent women from extensive surgery. An algorithm for possible differentiation between peritoneal/female genital TB and EOC may be helpful in clinical setting.

Key words: ovaries, peritoneum, tuberculosis

Corresponding author:

Domagoj Vidosavljević
Department of Gynaecology and
Obstetrics, County General and Croatian
War Veterans Hospital
Županijska 35, 32000 Vukovar, Croatia
Phone: +385 32 452 126;
fax: +385 32 452 111;
E-mail: domagoj.vidosavljevic@gmail.com
Alexandra Wagner ORCID ID: 0000-0001-
7342-462X

Original submission:

20 March 2019;

Revised submission:

28 June 2019;

Accepted:

08 October 2019

doi: 10.17392/1023-20

Med Glas (Zenica) 2020; 17(1):86-91

INTRODUCTION

Tuberculosis (TB) is an infectious disease caused by *Mycobacterium tuberculosis* and represents the leading cause of death by a single infectious agent (approximately 10 million new infections and 2 million deaths in 2016). Seven countries accounting for 64% of the new infections in 2016 are India, followed by Indonesia, China, the Philippines, Pakistan, Nigeria and South Africa (1). In Morocco, the global incidence of tuberculosis is very high, with 103 new cases per 100,000 inhabitants yearly, representing about 36,000 new cases in 2016 (2). Due to globalization and flight movements there has been an increased TB incidence in western countries. About one quarter of the world's population has "latent tuberculosis", which means they came in contact with mycobacterium tuberculosis, but do not suffer from tuberculosis and cannot transmit it (2). The lifetime risk when infected with TB bacteria of falling ill with tuberculosis is at 5-15% for people with a competent immune system (3). Patients suffering from HIV-Infection or any other form of acquired or innate immunodeficiency, have a higher risk of developing TB (4). Further predisposing factors are low income, bad access to health care and malnutrition (5).

Tuberculosis most commonly affects the lungs, causing cough, weight loss and bloody sputum, but can also affect other organs ("extrapulmonary tuberculosis"). In women, the most common extrapulmonary manifestation of tuberculosis usually affects the reproductive organs ("genital tuberculosis") (6). Genital tuberculosis clinically presents with various symptoms, like chronic pelvic pain, menstrual abnormalities or infertility (7-9), but can also stay asymptomatic and only appear as an incidental finding on imaging or mimicking malignant processes of the reproductive organs (10). Infection of the reproductive organs mostly occurs secondary to pulmonary infection by hematogenous spreading, but there are also reported cases of sexual transmission through genital tuberculosis of the partner or infection by direct spreading from surrounding organs (11). In female genital tuberculosis, the most commonly affected organs are the fallopian tubes, usually presenting with hydro-/pyosalpinx or tubo-ovarian masses (12). Endometrial involvement usually leads to adhesions, while infected ovaries mainly present with tubo-ovarian masses in imaging (4). Cervical infection can mi-

mic cervical cancer in colposcopy and is diagnosed by biopsy, showing granulomatous infection. Involvement of the vagina and vulva is rare, but we should be aware of it as a differential diagnosis (9).

PATIENTS AND METHODS

Patient and study design

A 23-year-old woman presented in September 2014, in Charité Universitätsmedizin Berlin, Gynaecological Tumour Centre and European Competence Centre for Ovarian Cancer, with a one-year history of intermittent episodes of abdominal pain. She also reported an unintentional weight loss of four kilograms in the past four months, absence of appetite and lamented dyspareunia as well as primary infertility, with a normal menstruation. She denied night sweat and cough. The patient had emigrated from Morocco the previous year, where she had studied law, and was now attending a German language school. She was married to a man from Guinea for eight months, who had been living in Germany for 17 years.

The patient's medical and surgical histories were unremarkable; there was no positive family history for breast or ovarian cancer. A history of previous tuberculosis or contact with TB patients was denied.

Methods

Laboratory analysis of the blood was performed in Labor Berlin (Allgemeine Laborauskunft, Labor Berlin – Charité Vivantes GmbH, Berlin, Germany). Diagnosis of the current disease was based on the laboratory findings of CA-125 (<35kU/L), human epididymis (HE) protein 4 (premenopausal <70 pmol/L), Risk of Ovarian Malignancy Algorithm (ROMA) index of 7.4% is defined as a high risk for epithelial ovarian cancer (EOC) in premenopausal women and ROMA index of <7.4% is defined as low risk for EOC in premenopausal women. The ROMA was developed by Moore et al. and combines CA125 and HE4 serum levels and the menopausal status of a patient with suspicious pelvic mass, thus stratifying patients into high and low risk groups for having a malignant ovarian lesion (13).

The following blood analyses were also performed: C-reactive protein (CRP), haemoglobin, leukocyte, platelets, procalcitonin, albumin, pro-

tein, alkaline phosphatase, aspartate aminotransferase (AST), alanine aminotransferase (ALT), amylase, lipase, gamma-glutamyltransferase, lactate dehydrogenase (LDH), creatinine, urine acid, sodium, potassium, International Normalized Ratio (INR).

Also, HIV (HIV 1/2 antibody and P24 antigen) (Screen – Elecsys HIV combi PT, Roche, Roche Diagnostics, Penzberg, Germany), hepatitis B (hepatitis B antibody in serum) (Roche Diagnostics) and C tests (hepatitis C antibody in serum) (Roche Diagnostics) were performed.

Abdominal or transvaginal ultrasound was made using transvaginal ultrasound (Siemens' ACUSON S3000) and confirmed by histopathology after diagnostic laparoscopy.

RESULTS

Initial laboratory evaluation showed elevated levels of CA-125 (224.6 kU/L, range: <35kU/L), HE 4 was not increased, 60.91 pmol/L (range: premenopausal: <70 pmol/L), ROMA index: 13.2 % (high risk for EOC). The other blood counts were within the normal range. HIV, hepatitis B and C tests were negative. Transvaginal ultrasound revealed small amounts of free fluid in the pouch of Douglas, dilated fallopian tubes on both sides with the suspicion of sactosalpinx (Figure 1), and a cystic mass with internal echogenicity near the right ovary as well as an unclear structure near the left ovary (Figure 2). Ultrasound of the liver and kidneys was normal.

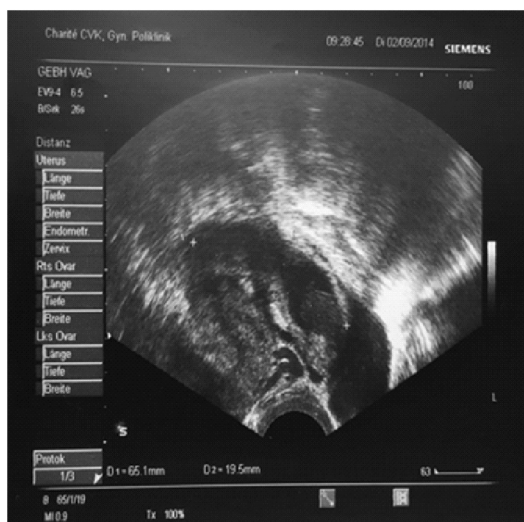


Figure 1. Dilated Fallopian tube on the right side, with small amounts of free fluid in the pouch of Douglas (Rohr I, Charité Universitätsmedizin Berlin, 2014)

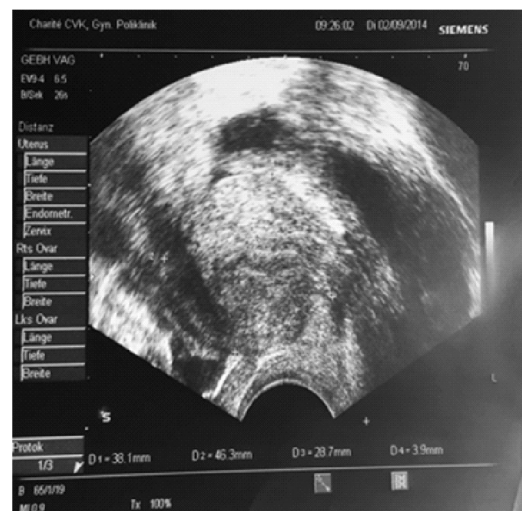


Figure 2. Cystic mass with inhomogeneous echogenicity (right ovary) (38.1x46.3x28.7 mm) (Rohr I, Charité Universitätsmedizin Berlin, 2014)

Suspecting a malignant process of the fallopian tubes or the ovaries, we performed an exploratory laparoscopy for an accurate diagnosis. The operation revealed few adhesions between the abdominal wall and pelvic organs and multiple diffuse, white miliary nodes of the peritoneum referred for presumed peritoneal carcinosis (Figure 3). The fallopian tubes were dilated on both sides and covered in fine miliary nodes. The left ovary seemed inconspicuous, the right ovary was adherent to the pelvic wall, but as far as visible also inconspicuous.

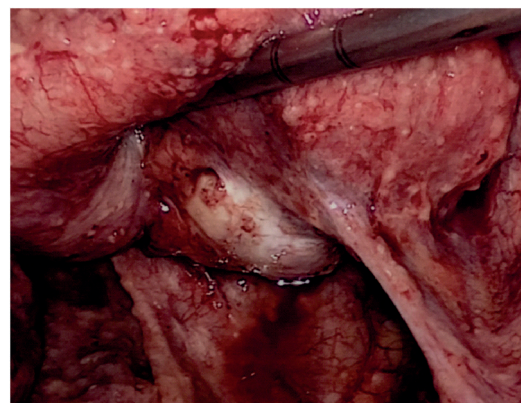


Figure 3. Micro nodules all over the peritoneal cavity mimicking peritoneal cancer (Rohr I, Charité Universitätsmedizin Berlin, 2014)

Peritoneal wall biopsies were taken and 20 mL of ascites was aspirated during surgery and sent for histological investigations. Furthermore, a unilateral salpingectomy on the left side was performed, also for histological investigations. The

histopathological investigation of the peritoneal biopsies revealed necrotizing granulomatous changes consistent with TB with no malignant cells (Figure 4), thus excluding a malignant process. Histopathological investigation of the fallopian tube showed granulomatous abscessifying salpingitis with suspicion of genital tuberculosis.

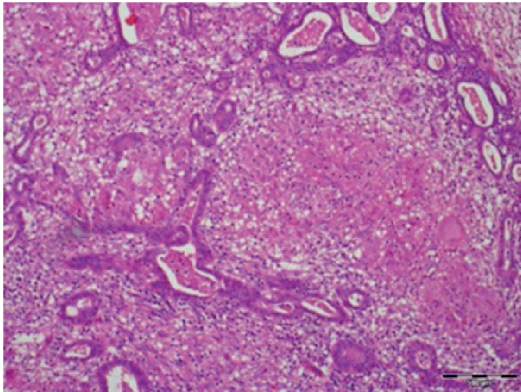


Figure 4. Histopathological examination of the surgical specimen: Tuba uterina showing severe granulomatous inflammation (magnification 10X10) (Arsenić R, Charité Universitätsmedizin Berlin, 2014)

Acid-fast stain and culture were negative for *Mycobacterium tuberculosis*.

A CT scan postop of the abdomen, pelvic and thorax showed a mass of 8x15 mm near the right ovary, as well as a mass of 25x31 mm near the left ovary with a tooth-shaped structure embedded in its centre. Additionally, the CT scan revealed accentuated mesenterial, paraaortal, iliac and inguinal lymph nodes.

Suspecting genital tuberculosis, we started a treatment with eremfat, isozid and myambutol that was continued for nine months. The serum CA-125 level returned to normal levels after antituberculous therapy. The patient is after a follow-up period of 24 months currently asymptomatic. Because of extensive irreparable tubal damage, the patient was waiting for an *in vitro* fertilization cycle.

DISCUSSION

Female genital tuberculosis shows an increasing incidence in the western world due to globalization (14). Patients with genital TB in European countries are usually immigrants from the third world countries where incidence is high, and aged between 20-40. Patients with invasive ovarian epithelial cancer have peak incidence at 56-60 years of age (15). Female genital TB is an important

differential diagnosis for diverse pelvic processes, since symptoms can vary widely from infertility to abnormal bleedings or chronic pelvic pain (7-9). As TB can cause elevated CA-125 levels as well as ascites and pelvic masses, it should be kept in mind as differential diagnosis especially regarding young women from high-TB-incidence areas with suspicion of fallopian tube or ovarian carcinoma without positive family history or BRCA-mutations (14-17). Acid-fast stain and culture as well as CA-125 levels are often insufficient for diagnosis due to their lack of sensitivity and/or specificity (16). Genital and peritoneal tuberculosis have no pathognomonic features, no remarkable physical finding linked to the condition itself, making diagnosis more challenging.

Usually, symptoms are linked with affected neighbouring systems; e.g. dysuria and voiding frequency, anorexia, nausea, vomiting, bowel dysfunction, loss in body weight. Palpable tumour mass in pelvic region can often be misdiagnosed as ovarian cancer or peritoneal carcinomatosis. In some cases, patient's family medical history of TB can be helpful in diagnostics. However, indirect diagnostics such as tuberculin skin test, complete blood count (CBC) and sputum staining for *Mycobacterium* are not helpful, as demonstrated by Hasanzadeh et al. in their case series (11) showing presence of tumour mass in pelvis. Elevated Ca-125 values often point to possible ovarian cancer, stressing necessity for surgical procedure- diagnostic laparoscopy, which can confirm diagnosis by pathohistology and provide sample of ascites for PCR analysis (15). Invasive diagnostics such as laparoscopy may be necessary to obtain biopsies for histological examination, usually showing necrotizing granulomatous infection, or gain ascetic fluid to perform PCR for *M. tuberculosis* (17,18). Diagnosis by intrasurgical frozen section combined with clinical findings can avoid extensive surgery that would be indicated for the treatment of malignancies of the fallopian tubes and ovaries (19). However, to avoid invasive diagnostics, an algorithm for possible differentiation between peritoneal/female genital TB and EOC may be helpful in clinical setting (Table 1). Since a normalization of CA-125 level, like in our patient, seems to correlate with the response to antituberculous therapy, it might be useful as a follow-up marker

Table 1. Possible differentiation between peritoneal/female genital tuberculosis (TB) and high grade epithelial ovarian cancer (EOC)

Characteristic	Tuberculosis	Ovarian cancer
	30 years	70 years
Median age	30 years	70 years
Adnexal mass	+	++
Papillary structures	-	++
Ascites	+/-	+++
Abdominal pain	+	+
Abdominal distention	+	+
Weight loss	++	+
Elevation of Ca 125	+	++
Elevation of HE4	-	+
Bacteriological cultures and cytology positive for TB	-/+	-
Peritoneal micro nodules	++	++

in patients with genital or peritoneal TB (20,21). Human epididymis protein 4 (HE4) shows higher specificity than CA-125 regarding benign gynaecological processes (22), and can also predict surgical outcome in patients with EOC (23). Showing significantly lower levels in lung TB patients than in patients with lung malignancies, it may be used as a marker to differentiate between malignancies and TB (24). One retrospective comparison of CA-125 and HE4 levels in peritoneal TB and epithelial ovarian cancer patients showed significantly lower HE4 and CA-125 le-

vels in TB patients and thus suggests that, using a certain cut-off for both markers (HE4: 151,4 pmol/L and CA125: 563,5 U/l, higher results indicating EOC), the combined evaluation of both biomarkers may help to presurgically differentiate peritoneal TB from EOC (25). Uncommon infectious diseases like TB or actinomycosis (26) must be kept in mind as a differential diagnosis for EOC, to prevent women from unnecessary and life-altering extensive surgery.

Female genital tuberculosis is a rare, forgotten, but very important differential diagnosis and should be kept in mind regarding suspected fallopian tube or ovarian carcinoma to prevent women from extensive surgery. An algorithm for possible differentiation between peritoneal/ female genital tuberculosis and epithelial ovarian cancer may be helpful in clinical setting.

FUNDING

No specific funding received for this study

TRANSPARENCY DECLARATION

Competing interests: None to declare

REFERENCES

- World Health Organization. Tuberculosis. 2018. <http://www.who.int/mediacentre/factsheets/fs104/en/> (18 June 2019)
- World Health Organization. Global Tuberculosis Report. 2018. http://www.who.int/tb/publications/global_report/en/ (18 June 2019)
- Namani S, Qehaja-Buçaj E, Namani D. Screening for genital tuberculosis in a limited resource country: case report. *BMC Infect Dis* 2017; 17:130-8.
- Sharma JB, Sharma E, Sharma S, Dharmendra S. Female genital tuberculosis: revisited. *Indian J Med Res* 2018; 148:S71-S83.
- Grace GA, Devaleenal DB, Natrajan M. Genital tuberculosis in females. *Indian J Med Res* 2017; 145:425-36.
- Djuwantono T, Permadi W, Septiani L, Faried A, Halim D, Parwati I. Female genital tuberculosis and infertility: serial cases report in Bandung, Indonesia and literature review. *BMC Res Notes* 2017; 10:683.
- Aliyu MH, Aliyu SH, Salihu HM. Female genital tuberculosis: a global review. *Int J Fertil Womens Med* 2004; 49:123-36.
- Namavar Jahromi, B, Parsanezhad ME, Ghane-Shirazi R. Female genital tuberculosis and infertility. *Int J Gynaecol Obstet* 2001; 75:269-72.
- Golden M, Vikram HR. Extrapulmonary tuberculosis: an overview. *Am Fam Physician* 2005; 72:1761-8.
- Patel S, Lahamge K, Desai A, Dave I K. Ovarian carcinoma or abdominal tuberculosis? - A diagnostic dilemma: study of fifteen cases. *J Obstet Gynaecol India* 2012; 62:176-8.
- Hasanzadeh M, Naderi RH, Hoshvar AH, Shabane S, Shahidsales S. Female genital tract tuberculosis presenting as ovarian cancer. *J Res Med Sci* 2014; 19:184-9.
- Adali E, Dulger C, Kulusari A, Kurdoglu M, Yildizhan R. Pelvic peritoneal tuberculosis simulating peritoneal carcinomatosis: high clinical suspicion and minimally invasive procedure. *Arch Gynecol Obstet* 2009; 280:867-8.
- Moore R, Miller C, Disilvestro P, Landrum L, Gajewski W, Bal J, Skates SJ. Evaluation of the diagnostic accuracy of the Risk of Ovarian Malignancy Algorithm in women with a pelvic mass. *Obstet Gynecol* 2011; 280-8.
- Institut Robert Koch. Tuberkulose und Migration. 2009. https://www.rki.de/DE/Content/Infekt/Impfen/Migration/Infektkrankheiten/Migration/migration_infektkrankheiten_TBC.html. (15 September 2019)
- Berek JS. Berek and Novak's Gynecology. 14th ed. Lippincot, Philadelphia: Williams and Wilkins, 2014.
- Koc S, Beydilli G, Tulunay G, Ocalan R, Boran N, Ozgul N, Kose MF, Erdogan Z. Peritoneal tuberculosis mimicking advanced ovarian cancer: a retrospective review of 22 cases. *Gynecol Oncol* 2006; 103:565-9.

17. Xi X, Shuang L, Dan W, Ting H, Han MY, Ying C, Quan M, Sun C, Chen Z, Cui F, Ming C, Zhou JF, Xuan WS, Lu YP, Ma D. Diagnostic dilemma of abdominopelvic tuberculosis: a series of 20 cases. *J Cancer Res Clin Oncol* 2010; 136:1839-44.
18. Piura B, Rabinovich A, Leron E, Yanai-Inbar I, Mazor M. Peritoneal tuberculosis mimicking ovarian carcinoma with ascites and elevated serum CA-125: case report and review of literature. *Eur J Gynaecol Oncol* 2002; 23:120-2.
19. Moss EL, Hollingworth J, Reynolds M. The role of CA125 in clinical practice. *J Clin Pathol* 2005; 58:308-12.
20. Gosein MA, Narinesingh D, Narayansingh G, Bhim N, Pearse A. Peritoneal tuberculosis mimicking advanced ovarian carcinoma: an important differential diagnosis to consider. *BMC Res Notes* 2013; 6:88-9.
21. Simsek H, Savas MC, Kadayifci A, Tatar G. Elevated serum CA 125 concentration in patients with tuberculous peritonitis: a case-control study. *Am J Gastroenterol* 1997; 92:1174-6.
22. Wu C, Changchien CC, Tseng CW, Chang HY, Ou YC, Lin H. Disseminated peritoneal tuberculosis simulating advanced ovarian cancer: a retrospective study of 17 cases. *Taiwan J Obstet Gynecol* 2011; 50:292-6.
23. Escudero JM, Auge JM, Filella X, Torne A, Pahisa J, Molina R. Comparison of serum Human Epididymis Protein 4 with Cancer Antigen 125 as a tumor marker in patients with malignant and nonmalignant diseases. *Clin Chem* 2011; 57:1534-4.
24. Liu W, Yang J, Chi PD, Zheng X, Dai SQ, Chen H, Xu BL, Liu WL. Evaluating the clinical significance of serum HE4 levels in lung cancer and pulmonary tuberculosis. *Int J Tuberc Lung Dis* 2013; 17:1346-53.
25. Zhang L, Chen Y, Liu W, Wang K. Evaluating the clinical significances of serum HE4 with CA125 in peritoneal tuberculosis and epithelial ovarian cancer. *Biomarkers* 2016; 21:168-72.
26. Sehouli J, Stupin JH, Schlieper U, Kuemmel S, Henrich W, Denkert C, Dietel M, Lichtenegger W. Actinomycotic inflammatory disease and misdiagnosis of ovarian cancer. A case report. *Anticancer Research* 2006; 26:1727-31.