

Radiological evaluation of lumbosacral spine for post discectomy segmental instability

Rasim Skomorac¹, Jasmin Delić², Hakija Bečulić¹, Aldin Jusić¹

¹Department of Neurosurgery, Canton Hospital Zenica, ²Department of Anatomy, School of Medicine Tuzla; Bosnia and Herzegovina

ABSTRACT

Aim To establish presence of segmental instability in patients operated with standard discectomy comparing measurement of translation and rotation on postoperative functional radiographs of lumbosacral spine with reference values, and to explore difference between patients operated on one or two levels.

Methods The study included 71 patients, who were operated due to herniated lumbar disc. They were divided into two groups operated on one level (group A) or two adjacent levels (group B). All patients had been imaged in a standing position with functional lateral radiography. Radiographic images were digitized and then computerized measurement of translation and rotation was made. Measurement data were compared between the groups and with reference values obtained in healthy adults.

Results Standard lumbar discectomy leads to an increase in translation, however, it reached statistical significance only for L4/L5 level and a decrease of rotation, which showed statistical significance for all samples, relative to the reference values. There was no statistically significant difference in the values of translation and rotation between the groups for corresponding levels, except for the value of the rotation for L4/L5 level as adjacent, unoperated level. Comparison of translation and rotation between the operated and adjacent levels did not show a statistically significant difference. When it comes to comparing the measured and predicted translation, there was a statistically significant difference only at the L5/S1 as an unoperated level.

Conclusion Standard discectomy does not lead to radiologically significant segmental instability, and two-level surgery has not caused more pronounced signs of instability comparing to one-level surgery.

Key words: instability, spine, discectomy, flexion-extension radiographs

Corresponding author:

Rasim Skomorac
Department of Neurosurgery,
Cantonal Hospital Zenica
Crkvice 67, 72000 Zenica,
Bosnia and Herzegovina
Phone: +38732424650;
Fax: +38732405534;
E-mail: skomy@bih.net.ba

Original submission:

04 May 2015;

Revised submission:

01 July 2015;

Accepted:

13 May 2016.

doi: 10.17392/817-16

Med Glas (Zenica) 2016; 13(2):142-147

INTRODUCTION

Clinical instability is defined as an abnormal response to applied loads on the spine and is often characterized by excessive mobility of the spinal segment. In many cases the instability is identified only by functional radiography, but this technique has limited reproducibility(1). Many surgeons use flexion-extension lateral views to disclose abnormal vertebral motion before deciding on surgical fusion (2). However, this method is challenging and debatable for the following three reasons: (a) its diagnostic value cannot be determined because of the lack of a non-traumatic and routinely applicable reference standard to define intervertebral instability; (b)its reproducibility is difficult, a slight variation in patient positioning or in the direction of the x-ray beam may result in a 10–15% variation in the range of vertebral displacement; (c)the appropriate way to obtain flexion-extension radiographs and the method to measure displacements is still not standardized (3). There is no single modality that discriminates with sufficient certainty “normal” and “abnormal” movement, questioning the value of imaging methods for the diagnosis of instability (1). A significant barrier for certain diagnosis is non-specific nature of back pain and uncertain relationship between instability and pain (1). Clinical instability of the spine is defined as a loss of spine’s ability to maintain its patterns of displacement under physiologic loads so there is no initial or additional neurologic deficit, no major deformity and no incapacitating pain (4).

Standard discectomy is a surgical procedure that involves lesion of several anatomical structures important for the stability of the spine and can lead to compromising segmental stability, especially if it is made at two adjacent levels. There is no agreement between surgeons whether to do two-level discectomy or not, because of the fear of consecutive instability. In our material we had a considerable number of patients operated on two levels, but we did not notice a clinical difference in the outcome. Since there is an agreement that discectomy can lead to radiological instability we decided to investigate and compare radiological data of post discectomy spine with reference data from healthy adults and to compare data between patients operated on one or two levels. This study can help neurosurgeons and other spine surgeons to decide whether they should do immediate po-

stoperative stabilization after two-level surgery or wait for signs of clinical instability.

There has been a constant debate on the necessity of spinal fusion after discectomy because of the difficulties in intervertebral instability assessments as a result of anatomical position of disc herniation and loss of the intervertebral disc(5).

In modern spinal surgery solutions for this problem can be either stabilization and fixation or lumbar arthroplasty.

In available literature we did not find a study comparing either radiological or clinical data between patients with discectomy done on one or two levels.

PATIENTS AND METHODS

Patients

This prospective study involved 71 patients of both sexes aged 18-65 years, operated at the Department of Neurosurgeryof Cantonal Hospital Zenica, Bosnia and Herzegovina, in the period 2001-2007. All patients had lumbar disc herniation diagnosed by CT (*computed tomography*) imaging or MRI (magnetic resonance imaging). The patients were divided into two groups:group A (35 patients) operated on one level, and group B (36 patients) operated on two adjacent levels.

Methods

All patients 3-9 years postoperatively underwent functional lateral radiography in flexion and extension in a standing position. Radiographs were digitized and computerized measurement of translation and rotation was done, using absolute numbers by a modified method described previously by Brinckman et al. (6) and Frobin et al. (7). As a basis for measuring the four points on the body of vertebra were used, which can be always identified on radiographs. Raw data cannot be compared directly because the motivation, pain or muscle spasms, the extent of rotation and translation will vary from normal.The predicted value of translation was based on the following formula: Translation (predicted) = Rotation (measured) x TPR (translation per degree of rotation).A comparison of the measured values of individual translation with set points enables quantification of mobility to normal, hyper-or hypo mobility (7).

The degree of translation and rotation on postoperative functional radiographic images of lumbosacral spine was determined in patients operated with standard discectomy and compared with reference values established by measurements in healthy adults: rotation (in degrees) L2/L3 13.9; L3/L4 14.2; L4/L5 16.4; L5/S1 13.2; translation L2/L3 -0.0444; L3/L4 -0.0498; L4/L5 -0.0511; L5/S1 0.0017; TPR (translation per degree of rotation) L2/L3 -0.00325; L3/L4 -0.00371; L4/L5 -0.00313; L5/S1 -0.00012(6). It was compared between patients operated on one level and the patients operated on two levels.

Statistical analysis

To test the statistical significance of the difference between the measured parameters in comparison with the reference values, as well as between the group A and B, ANOVA test, t-test for dependent and independent samples and post hoc experiment (LSD) were used. The threshold for statistical significance was taken at $p < 0.05$. T-test was applied for independent samples and compared the obtained values of rotation and translation after surgery in the total sample (both groups together), both operated and adjacent unoperated levels, with reference values and also for both groups separately. ANOVA test was used for comparing values of translation and rotation between the groups A and B for corresponding levels.

RESULTS

In the patients operated on one level (group A), 16 patients were operated on L4/L5 and 19 patients on the L5/S1 level.

In the patients operated on two levels (group B), one patient was operated on L2/L3/L4 levels, eight on L3/L4/L5 levels, 25 on L4/L5/S1, and two patients operated on L5/S1/S2 levels.

After measurements postoperative values of translation and rotation for the whole sample were established (Table 1), and separately for group A and group B (Tables 2 and 3).

Statistically significant difference ($p < 0.05$) for all levels (L2/L3; L3/L4; L4/L5 and L5/S1) was found for rotation (decreased). Translation for all levels operated and adjacent (L2/L3; L3/L4; L4/L5 and L5/S1) was increased, except for L5/S1 as an operated level, where it was decreased. Increase in translation reached a statistically significant

Table 1. Cumulative measurement results for translation, rotation and predicted translation on postoperative functional images for 71 patients operated on one/two adjacent levels

Level	No of patients	Rotation (degrees) (SD)	Translation (absolute numbers) (SD)	Predicted translation (SD)
L2/L3	1	10.51		
L3/L4	9	2.87 (5.54)	-0.03 (0.06)	-0.011 (0.021)
L4/L5	49	4.23 (6.05)	-0.02 (0.065)	-0.014 (0.021)
L5/S1	45	4.17 (6.24)	-0.007 (0.057)	-0.001 (0.006)
S1/S2	2	-0.31 (3.15)	0.021 (0.081)	0.00004 (0.0004)
L2/L3 adjacent	8	4.46 (4.94)	-0.038 (0.0598)	-0.01398 (0.01658)
L3/L4 adjacent	41	4.60 (3.90)	-0.038 (0.0649)	-0.02011 (0.0259)
L4/L5 adjacent	22	5.15 (6.18)	-0.031 (0.042)	-0.0225 (0.0249)
L5/S1 adjacent	24	0.97 (6.83)	0.0254 (0.0466)	-0.0003 (0.0011)

SD, standard deviation

Table 2. Measurement results for translation and rotation on postoperative functional images for 35 patients operated on one level

Level	No of patients	Rotation (degrees) (SD)	Translation (absolute numbers) (SD)	Predicted translation (SD)
L4/L5	16	3.066 (6.196)	-0.0187 (0.06799)	-0.012 (0.0238)
L5/S1	19	2.43 (5.54)	-0.0073 (0.0543)	-0.0007 (0.0012)
L3/L4 adjacent	16	4.66 (4.099)	-0.0203 (0.05796)	-0.0161 (0.0153)
L4/L5 adjacent	19	3.99 (5.696)	-0.0295 (0.0384)	-0.0192 (0.0249)
L5/S1 adjacent	16	-0.285 (7.81)	0.0188 (0.0496)	-0.0002 (0.00137)

SD, standard deviation

Table 3. Measurement results for translation, rotation and predicted translation on postoperative functional images for 36 patients operated on two adjacent levels

Level	No of patients	Rotation (degrees) (SD)	Translation (absolute numbers) (SD)	Predicted translation (SD)
L3/L4	9	2.87 (5.54)	-0.03 (0.06)	-0.011 (0.021)
L4/L5	33	4.79 (5.99)	-0.02 (0.063)	-0.014 (0.0204)
L5/S1	27	5.44 (6.52)	-0.007 (0.061)	-0.0019 (0.008)
S1/S2	2	-0.32 (3.15)	0.021 (0.081)	0.00004 (0.00038)
L2/L3 adjacent	8	4.46 (4.94)	-0.038 (0.0598)	-0.01398 (0.0166)
L3/L4 adjacent	25	4.56 (3.85)	-0.049 (0.0678)	-0.0226 (0.03088)
L4/L5 adjacent	3	12.51 (3.84)	-0.04 (0.07158)	-0.0435 (0.0120)
L5/S1 adjacent	8	3.01 (4.57)	0.036 (0.04202)	-0.00036 (0.00055)

SD, standard deviation

difference ($p < 0.05$) only for the L4/L5 level, operated and unoperated.

In the group A, statistically significant decrease ($p < 0.01$) was found for all levels for the rotation, operated and adjacent, while for the translation statistically significant increase ($p < 0.05$) was found for adjacent level L3/L4 and for L4/L5 level as the adjacent and operated. In group B, the rotation was significantly different ($p < 0.01$) for all operated and adjacent levels, and it was decreased. A statistically significant increase in translation ($p < 0.05$) was found for treated L4/L5 level and for L5/S1, as an adjacent level (Figure 1).

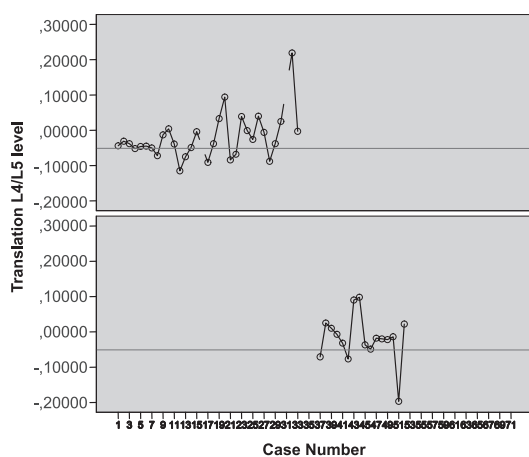


Figure 1. Relationship between translation on operated level L4/L5 and reference values by groups

A statistically significant difference between the groups ($p < 0.05$) was found only for the rotation at the L4/L5 level in the case of neighboring, unoperated level, and it was significantly higher in group B ($p = 0.022$). Comparing the aggregate value of translation and rotation between the groups, the statistically significant difference in the rotation was found, and it was higher in group B ($p < 0.05$), but not for translation.

Comparison of translation and rotation between different levels, for the total sample, showed a statistically significant difference in translation ($p < 0.05$), but not for rotation. *Post hoc* experiment (LSD) differentiated statistically significant difference between the levels for translation for L5/S1 compared to levels L3/L4 and L4/L5.

An analysis within the groups showed a statistically significant difference between the levels for translation within group B ($p = 0.024$).

Post hoc experiment showed that the difference originated between the levels L4/L5 and L5/S1 ($p = 0.007$).

The comparison of the total value of translation and rotation on the whole sample between the operated and adjacent, unoperated levels, showed no statistically significant difference, as well as the comparison between operated and adjacent levels within the groups.

A statistically significant increase ($p < 0.05$) for measured and predicted translation was found in the whole sample at the level L5/S1, when it was not a treated level. When values were compared within the groups, a statistically significant increase ($p < 0.05$) was also found for unoperated, adjacent L5/S1 level, in group B.

DISCUSSION

This study investigated radiological data (segmental translation and rotation) of post discectomy spine and compared them with reference data from healthy adults, as well as between patients operated on one or two levels. Direct comparison of the results of our study with other studies is not possible because of methodological differences and non-existence of similar studies in the literature comparing patients with discectomy done on one or two levels. In our earlier work we tried to identify signs of segmental instability on postoperative standard lateral radiographic images of the lumbosacral spine after discectomy on one or two levels measuring height of disc space (HD), the angle between adjacent vertebrae (A) and translation (T). Comparison of preoperative with postoperative values showed that in patients operated on one level there was a statistically significant difference in HD, while in the other two parameters, there were no statistically significant differences. In patients operated on two levels, we revealed a significant difference in preoperative and postoperative values for HD and A, while for T there was no statistically significant difference (8). White and Panjabi defined the criteria for the diagnosis of instability from flexion/extension images as a translation greater than 4.5 mm or more than 15% of width of the vertebral body, or rotation greater than 15% at L1/L2, L2/L3 and L3/L4, greater than 20% at L4/L5 and greater than 25% at L5/S1 (4). Sagittal translation has a greater effect than segmental angulation on lumbar symptoms and the

presence of two radiological factors may be indicators of the presence of symptoms (9). There can be different types of instability: rear opening, anterior translation in flexion, rear sliding in extension, or combinations of those (10). Segmental stability was radiographically investigated in 50 patients after standard discectomy using the Sato's method of instability classification and it was found that in 30 cases the images showed instability, but there were only 9 symptomatic patients (11).

Different studies using different methods gained often contradictory results. A study comparing segmental motion in the early postoperative phase after lumbar discectomy and outcome after five years suggests that the increased initial displacement of the vertebra in the early postoperative phase was associated with poor clinical outcome (12). Others showed that the intervertebral angle in flexion and a range of motion were the most important prognostic parameters for lumbar distraction instability and medial facetectomy with removal of the rear ligament complex decreases stiffness by 15% (13). Resection of bone or ligamentous posterior elements has a minor effect on the bio-mechanical characteristics of the adjacent levels (14). The study using radiographic analysis before and three months after surgery showed a significant increase in the range of motion in patients with fenestration and limited discectomy (15). Hou et al. showed that partial discectomy significantly affected the stability of the lumbar

spinal mobile segment (16). Other authors reported that at the place of surgical violation there was less translational and rotational instability in subtotal than the total discectomy, but instability at the level above is present regardless of the volume of the removed nucleus (17). This is not confirmed in our study.

Standard discectomy inevitably leads to some radiological changes postoperatively, which can be detected and measured differently. The results of present study suggest that there are not enough elements to conclude that standard discectomy on one or two levels, conducted with maximum preservation of bony and ligamentous elements, leads to statistically significant increase in translation, which is agreed to be a more important element for proclaiming instability. Statistically significant decrease in rotation can be more connected with pronounced stiffness than instability. There are not enough arguments against two level discectomy when it is needed, as long as we adhere to surgical principles of minimal invasiveness and saving of bony and ligamentous structures. There is also no place for immediate postoperative stabilization in case of two level discectomy.

FUNDING

No specific funding was received for this study.

TRANSPARENCY DECLARATION

Competing interests: None to declare.

REFERENCES

1. Ferguson S. Biomechanics of the Spine. In: Boos N, Aebi M. Spinal Disorders Fundamentals of Diagnosis and Treatment. 1sted. Berlin Heidelberg: Springer-Verlag, 2008: 42-60.
2. Leone A, Cassar-Pullicino VN, Guglielmi G, Bonomo L. Degenerative lumbar intervertebral instability: what is it and how does imaging contribute? *Skeletal Radiol* 2009; 38:529-33.
3. Nizard R, Wybier M, Laredo JD. Radiologic assessment of lumbar intervertebral instability and degenerative spondylolisthesis. *Radiol Clin North Am* 2001; 39:55-71.
4. White AA, Panjabi MM (Eds.) *Clinical Biomechanics of the Spine*. 2nd ed. Philadelphia: Lippincott, 1990, 23-45.
5. Young DK, Seung JR, Dong JK. Radiological and clinical outcome after simple discectomy of central massive lumbar disc herniation *J Korean Soc Spine Surg* 2010; 17:169-76.
6. Brinckmann P, Frobin W, Biggemann M, Hilweg D, Seidel S, Burton K, Tillotson M, Sandover J, Atha J and Quinnell R. Quantification of overload injuries to thoracolumbar vertebrae and disc in persons exposed to heavy physical exertions or vibrations at the work-place. Part I. The shape of vertebrae and intervertebral discs-Study of young, healthy population and a middle aged control group. *Clin Biomech* 1994 (Suppl 1):S1-S83,
7. Frobin W, Brinckmann P, Leivseth G, Biggemann M, Reikerås O. Precision measurement of segmental motion from flexion - extension radiographs of the lumbar spine. *Clin Biomech* 1996; 11:457-65.
8. Skomorac R, Delić J, Jusić A, Bečulić H, Bajtarević A, Hadžić E. Morphometric changes of the lumbar intervertebral space following discectomy on one or two levels. *Med Glas (Zenica)* 2011; 8:249-54.

9. Iguchi T, Kanemura A, Kasahara K, Sato K, Kurihara A, Yoshiya S. Lumbar instability and clinical symptoms: which is the more critical factor for symptoms: sagittal translation or segment angulation? *J Spinal Disord Tech* 2004; 17:284-90.
10. Sato H, Kikuchi S. The natural history of radiographic instability of the lumbar spine. *Spine* 1993; 18:2075-79.
11. Padua R, Padua S, Romanini E, Padua, De Santis E. Ten- to 15-year outcome of surgery for lumbar disc herniation: radiographic instability and clinical findings. *Eur Spine J* 1999; 8:70-4.
12. Halldin K, Zoëga B, Kärrholm J, Lind BI, Nyberg P. Is increased segmental motion early after lumbar discectomy related to poor clinical outcome 5 years later? *IntOrthop* 2005; 29:260-4.
13. Kanayama M, Hashimoto T, Shigenobu K, Oha F, Ishida T, Yamane S. Intraoperative biomechanical assessment of lumbar spinal instability: validation of radiographic parameters indicating anterior column support in lumbar spinal fusion. *Spine* 2003; 28:2368-72.
14. Zander T, Rohlmann A, Klockne C, Bergmann G. Influence of graded facetectomy and laminectomy on spinal biomechanics. *Eur Spine J* 2003; 12:427-34.
15. Tibrewal SB, Percy MJ, Portek I, Spivey J. A prospective study of lumbar spinal movements before and after discectomy using biplanar radiography: correlation of clinical and radiographic findings. *Spine* 1985; 10:455-60.
16. Hou TS, Tu KY, Xu YK, Zhang WM, Wang HC, Wang DL. Effect of partial discectomy on the stability of the lumbar spine. A study of kinematics. *Chin Med J (Engl)* 1990; 103:396-9.
17. Goel VK, Goyal S, Clark C. Kinematics of the whole lumbar spine: effect of discectomy. *Spine* 1985; 10:543-54.

Radiološka evaluacija segmentne nestabilnosti lumbosakralne kičme nakon diskektomije

Rasim Skomorac¹, Jasmin Delić², Hakija Bečulić¹, Aldin Jusić¹

¹Služba za neurohirurgiju, Kantonalna bolnica Zenica, ²Katedra za anatomiju, Medicinski fakultet Tuzla; Bosna i Hercegovina

SAŽETAK

Cilj Ustanoviti prisustvo segmentne nestabilnosti kod pacijenata operisanih standardnom diskektomijom, upoređujući mjerenja translacije i rotacije na postoperativnim funkcionalnim rtg-snimcima lumbosakralne kičme s referentnim vrijednostima i ispitati postojanje razlike između pacijenata operisanih na jednom ili dva nivoa.

Metode U studiju je uključen 71 pacijent, operisan zbog hernije lumbalnog diska. Pacijenti su bili podijeljeni u dvije grupe: operisani na jednom nivou (grupa A) ili na dva nivoa (grupa B). Svim pacijentima su napravljeni funkcionalni lateralni rtg-snimci lumbosakralne kičme ustojećem položaju. Radiografski snimci su digitalizirani, a potom su načinjena kompjuterska mjerenja translacije i rotacije. Dobijena mjerenja su komparirana između grupa, kao i s referentnim vrijednostima dobijenim kod zdravih odraslih osoba.

Rezultati Standardna lumbarna diskektomija dovela je do povećanja translacije koje je statistički značajno samo za nivo L4/L5 i smanjenja rotacije koje je statistički značajno za cijeli uzorak, upoređujući s referentnim vrijednostima. Nije ustanovljena statistički značajna razlika u vrijednostima translacije i rotacije između grupa, za odgovarajuće nivoe, osim za vrijednosti rotacije na L4/L5 nivou, kao susjednom, neoperisanom nivou. Poređenje translacije i rotacije između operisanih i susjednih neoperisanih nivoa nije pokazalo statistički značajnu razliku. Kod usporedbe vrijednosti izmjerene i predviđene translacije, ustanovljena je statistički značajna razlika samo za nivo L5/S1 (neoperisani nivo).

Zaključak Standardna diskektomija ne dovodi do radiološki značajne segmentne nestabilnosti, a operacija na dva susjedna nivoa ne uzrokuje izraženije znake segmentne nestabilnosti, u poređenju s diskektomijom na jednom nivou.

KLjučne riječi: nestabilnost, kičma, diskektomija, funkcionalna radiografija