

Transient osteomyelitis of the distal radius in a three-year-old patient

Giuseppe Rinonapoli¹, Michele Bisaccia¹, Luigi Meccariello², Giovanni Battista Mancini³, Flavia Mar-rani⁴, Predrag Grubor⁵, Giuseppe Rollo², Auro Caraffa¹

¹Division of Orthopaedics and Trauma Surgery, University of Perugia, "S. Maria della Misericordia" Hospital, Perugia, ²Department of Orthopaedics and Traumatology, Vito Fazzi Hospital, Lecce, ³Department of Orthopaedics and Traumatology, San Matteo degli Infermi Hospital, Spoleto, ⁴Rehabilitation Unit, University La Sapienza, Roma; Italy, ⁵School of Medicine, University of Banja Luka, Bosnia and Herzegovina

ABSTRACT

Aim Reporting on an atypical case of a three-year-old patient affected by osteomyelitis of the distal radius, completely healed without antibiotic therapy.

Methods The clinical case is related to a three-year-old patient, whose clinical picture began with fever, pain and swelling of the right wrist. After three days, fever and swelling disappeared, but pain persisted. Plain x-rays of the right wrist, hematologic analyses, magnetic resonance imaging (MRI) with contrast medium and biopsy were performed in order to make a differential diagnosis between acute osteomyelitis and a malignant neoplasm, i.e. Ewing's sarcoma.

Results The plain x-rays of the right wrist showed an osteolytic area of the distal radio, with blurred rim. Haematology showed high erythrocyte sedimentation rate (ESR) and C-reactive protein (CRP); MRI confirmed the presence of a lesion, of no certain origin, therefore a biopsy was done. The histology was that of an inflammatory tissue. The patient, after the biopsy, was completely asymptomatic, ESR and CRP were back to normal. Before starting antibiotic therapy, it was preferred repeating x-rays. From the latter, the osteolysis completely disappeared. On the basis of the x-rays, blood exam and symptomatology, it was decided not to submit the patient to any treatment. After two years, the patient never had similar episodes.

Conclusion Patient presented with all characteristics of an osteomyelitis of distal radius, was unexpectedly spontaneously healed, without antibiotic therapy. Two years after the onset of the disease the patient recovered without clinical and radiographic sequelae. No similar cases are found in the literature .

Key words: bone healing, infection, long bone, physis, paediatrics, radius

Corresponding author:

Luigi Meccariello

Department of Orthopaedics and Traumatology, Vito Fazzi Hospital

Piazzetta Filippo Muratore,

Block: A- Floor: V, Lecce, Italy

Phone: +393299419574;

fax: +390823713864;

E-mail: drlordmec@gmail.com

Giuseppe Rinonapoli ORCID ID: <https://orcid.org/0000-0002-3669-189X>

Original submission:

19 August 2019;

Revised submission:

26 August 2019;

Accepted:

01 October 2019

doi: 10.17392/1070-20

Med Glas (Zenica) 2020; 17(1):178-181

INTRODUCTION

When plain radiographs of a child shows an osteolytic area, a differential diagnosis must be made, mainly to distinguish an osteomyelitis from a bone tumour, unfortunately not rare in a child (1,2).

Acute haematogenous osteomyelitis is the most common musculoskeletal infection in children with an annual rate of 1 out of 5,000 in children younger than 13 years of age in the United States (3). The worldwide annual incidence ranges from 1 out of 1,000 to 1 out of 20,000 (1,2).

Primary bone tumours are rare (3,4), but unfortunately, their prevalence is high in people under 20 years of age. The majority of benign bone tumours and tumour-like lesions occur in the first two decades of life (3). Therefore, when a bone lesion is found in an x-ray of a child, the diagnosis of primary bone tumours must always be taken into consideration (2).

The aim of this study was to present a case of a three-year-old boy affected by an osteolytic area of the distal radio, spontaneously healed.

PATIENT AND METHODS

A three-year-old Caucasian boy underwent an orthopaedic examination because of persistent pain at the right wrist. The patient was prescribed paracetamol, which temporarily reduced the symptomatology. After 7 days, pain was still present. For this reason, the boy was submitted to plain x-rays of the right wrist, which showed an osteolytic area, with poorly represented bone rim (Figure 1). This finding caused concern to the physicians and natural anxiety to the patient's parents. The paediatrician had the patient take some hematologic exams and the orthopaedic surgeon suggested a magnetic resonance (MRI) with con-

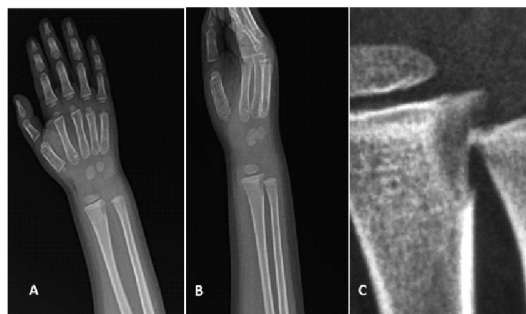

Figure 1. The x-rays done 7 days from the beginning of the symptoms show an osteolytic area at the distal metaphysis of the right radio. No clear rim is present around the lesion. A) anteroposterior view, B) lateral view, C) magnification of the lesion (Rinonapoli G, 2016)

trast medium under anaesthesia. After three days from the last orthopaedic examination (about two weeks from the onset of the symptoms) the pain disappeared. The patient was completely asymptomatic. The mother of the child declared that the clinical picture had begun with pain, swelling and fever (37.5-38 °C). Swelling and fever disappeared after three days, while pain persisted.

Methods

Hematologic analyses (Dasit XE 2100, Cornaredo, Milan, Italy) (in order to make a differential diagnosis between acute osteomyelitis and a malignant neoplasm, i.e. Ewing's sarcoma) were performed (reference value) in the Laboratory Analysis Service of the Santa Maria della Misericordia Hospital of Perugia, Italy: erythrocyte sedimentation rate (ESR) (reference value 1-30), C-reactive-protein (CRP) (0-0.5 mg/dL), haemoglobin (13-17 g/dL), haematocrit (38-52%), erythrocytes ($4.30-5.80 \times 10^6$), leukocytes ($3,60-960 \times 10^3$).

The magnetic resonance imaging (MRI) was performed with contrast medium under anaesthesia (GE Optima 360, 1.5 T, General Electrics, Boston, U.S.A.). Computed tomography (Optima 660 64-slice CT scanner, General Electrics, Boston, U.S.A.)-guided biopsy also was performed. An additional analysis included pharyngeal swab for microbiologic analysis.

RESULTS

Haematological exams showed high 1st hour ESR (57) and a raised CRP (2.78 mg/dL). Leukocytes were normal. The MRI showed a low signal on T1W images and high signal on fluid-sensitive and post-contrast sequences. In STIR T2 sequences the signal was increased, even in soft tissues adjacent to the lesion (Figure 2). The

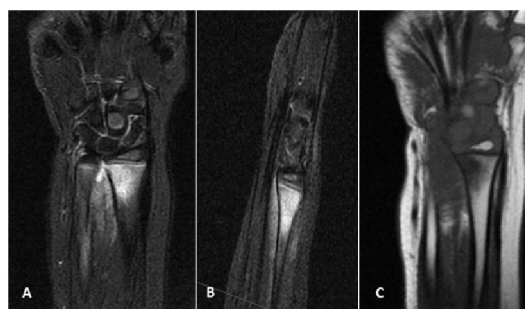


Figure 2. Magnetic resonance with contrast medium (gadolinium) of the distal right radio. A) STIR T2 sequence (coronal view), B) STIR T2 sequence (sagittal view), C) T1W sequence. In these images, it is possible to observe the involvement of the soft tissue around the lesion (Rinonapoli G, 2016)

patient was submitted to a CT-guided biopsy, from which inflammatory tissue was found. The pharyngeal swab was negative. Therapy with antibiotics never started. By 45 days from the first x-ray, the patient repeated the x-ray that showed the complete filling of the osteolytic lesion (Figure 3). The blood inflammatory markers were normal. After 2 years from the first x-ray, the child never had similar symptoms at the wrist, even after two episodes of influenza.

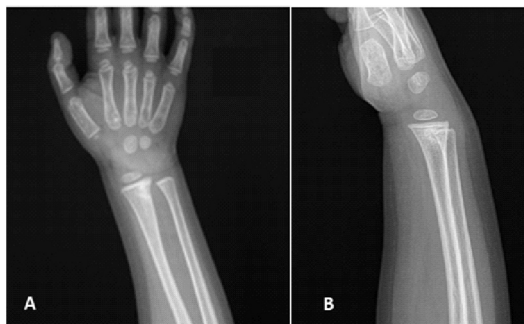


Figure 3. X-rays at 45 days from the onset of the symptomatology. A) anteroposterior view, B) lateral view. The lytic lesion disappeared. The lesion is filled by a tissue with a signal very similar to normal bone (Rinonapoli G, 2016)

DISCUSSION

The estimated incidence of acute osteomyelitis is about 8 cases per 100,000 children/year (5, 6). Children under 5 years of age are affected in about 50% of the cases, with a M:F ratio of 2:1 (7).

The most commonly involved sites are those with the fastest growing metaphases, due to their high vascularity (8). The femur has the highest rate of osteomyelitis (27%), followed by the tibia (22%), humerus (12%), and hands and feet (13%) (9). Distal radius is affected in a percentage of 1-4% (10-13).

The majority of paediatric osteomyelitis cases are secondary to haematogenous spread (14). The infection seeds in the metaphysis where blood flow is rich but sluggish. The route of entry may be the respiratory tract, particularly for *Kingella kingae*, *Streptococcus pyogenes* and *Streptococcus pneumoniae*, while the skin may be a common port of entry for *Staphylococcus aureus* (6).

Early detection is crucial given that a delay in the diagnosis of only 4 days is a risk factor for long-term sequelae (15-19). Unless acute osteomyelitis is diagnosed promptly and treated appropriately (11) it can be a devastating or even fatal disease.

In a recent systematic review in acute and subacute osteomyelitis paediatric patients, the most common presenting features were pain (81%), swelling and erythema (70%), fever (62%), reduced joint movement or pseudo paralysis (50%) (13-21). Another systematic review on acute osteomyelitis found leukocytosis in 36% of children on presentation, raised ESR in 91% and raised CRP in 81%. The sensitivity is highest (98%) when both the ESR and CRP are raised (16). A similar review in paediatric joint infections highlights the variable inflammatory marker response (17). White cell count (WCC) response is age-related, with infants and neonates rarely producing leukocytosis (8,9). Elevations in CRP usually start within 4 to 6 hours after infection and peak in 24 to 72 hours (9). The ESR and CRP together have a sensitivity of 98%; however, their specificity is quite low (17).

The MRI (preferably with paramagnetic contrast medium) is the main investigation tool, having both high sensitivity (82%–100%), and specificity (75%–99%). It is useful to localize the lesion, to define its extension, to follow up the development of the disease and to plan for surgical intervention (18). Biopsy is recommended to secure diagnosis, considering that several conditions, especially Ewing's sarcoma, frequently mimic acute osteomyelitis and a delay of the actual diagnosis would be detrimental (19-22).

The treatment consists in intravenous antibiotic therapy, starting as soon as possible, initially with a broad-spectrum antibiotic (one or two combined antibiotics).

The peculiarity of this case is that, because of the late diagnostic suspect of osteomyelitis, no antibiotic therapy was ever started. The decision of the physicians not to start with the antibiotic therapy was taken because of the complete radiographic healing of the bone osteolysis, the excellent health condition of the patients and negativization of inflammatory markers (ESR, CRP). Despite the lack of treatment, the lesion healed spontaneously after about 45 days from the onset of the first symptoms.

In conclusion, the authors believe that this case that presents all the characteristics of an osteomyelitis of the distal radius, has unexpectedly

healed, without antibiotic therapy. After 2 years after the onset of the disease the patient recovered without clinical and radiographic sequelae. No similar cases are found in the literature.

REFERENCES

- Pugmire BS, Shailam R, Gee MS. Role of MRI in the diagnosis and treatment of osteomyelitis in pediatric patients. *World J Radiol* 2014; 6:530-7.
- Song KM, Sloboda JF. Acute hematogenous osteomyelitis in children. *J Am Acad Orthop Surg* 2001; 9:166-75.
- SEER Cancer Statistics Review, 1975-2008. 2011. http://seer.cancer.gov/csr/1975_2008/results_single/sect_01_table.01.pdf (26 Sept 2019)
- Associazione Italiana Registri Tumori. I tumori in Italia: TREND 2003-2014. 2018. http://www.registri-tumori.it/cms/?q=sede_osso (26 Sept 2019)
- The Pediatric Orthopedic Society of North America (POSNA). Acute Osteomyelitis. 2013. www.posna.org/education/StudyGuide/acuteOsteomyelitis.asp (25 May 2016)
- Yeo A, Ramachandran M. Acute haematogenous osteomyelitis in children. *BMJ* 2014; 348:66.
- Gafur OA, Copley LAB, Hollmig ST, Browne RH, Thornton LA, Crawford SE. The impact of the current epidemiology of pediatric musculoskeletal infection on evaluation and treatment guidelines. *J. Pediatr Orthop* 2008; 28:777-85.
- Pugmire BS, Shailam R, Gee MS. Role of MRI in the diagnosis and treatment of osteomyelitis in pediatric patients. *World J Radiol* 2014; 6:530-7.
- Song KM, Sloboda JF. Acute hematogenous osteomyelitis in children. *J Am Acad Orthop Surg* 2001; 9:166-75.
- Krogstad P. Osteomyelitis. In: Feigin RD, Cherry JD, Demmler-Harrison GJ, Kaplan SL, eds. *Pediatric Infectious Diseases*. 6th ed. Philadelphia: Saunders, 2009:725-42.
- Gillespie WJ, Mayo KM. The management of acute haematogenous osteomyelitis in the antibiotic era: a study of the outcome. *J Bone Joint Surg Br* 1981; 63-B:126-31.
- Peltola H, Pääkkönen M, Kallio P, Kallio MJ. Short-versus long-term antimicrobial treatment for acute hematogenous osteomyelitis of childhood: prospective, randomized trial on 131 culture-positive cases. *Pediatr Infect Dis J* 2010; 29:1123-8.
- Dartnell J, Ramachandran M, Katchburian M. Haematogenous acute and subacute paediatric osteomyelitis: a systematic review of the literature. *J Bone Joint Surg Br* 2012; 94:584-95.
- Parsch K, Nade S. Infections of bones and joints. In: Benson M, Fixsen J, Macnicol M, Parsch K, eds. *Children's Orthopaedics and Fractures*. 3rded. London: Springer-Verlag, 2010:135-259.
- Chiappini E, Mastrangelo G, Lazzeri S. A case of acute osteomyelitis: an update on diagnosis and treatment. *Int J Environ Res Public Health* 2016; 13:539.
- Pääkkönen M, Kallio MJ, Kallio PE, Peltola H. Sensitivity of erythrocyte sedimentation rate and C-reactive protein in childhood bone and joint infections. *Clin Orthop Relat Res* 2010; 468:861-6.
- Kang SN, Sanghera T, Mangwani J, Paterson JM, Ramachandran M. The management of septic arthritis in children: systematic review of the English language literature. *J Bone Joint Surg [Br]* 2009; 91-B:1127-33
- Thomsen I, Creech CB. Advances in the diagnosis and management of pediatric osteomyelitis. *Curr Infect Dis Rep* 2011; 13:451-60.
- Copley LA. Pediatric musculoskeletal infection: trends and antibiotic recommendations. *J Am Acad Orthop Surg* 2009; 17:618-26.
- Cuomo R, Sisti A, Grimaldi L, D'Aniello C. Modified arrow flap technique for nipple reconstruction. *Breast J* 2016 22:710-1.
- Cuomo R, Russo F, Sisti A, Nisi G, Grimaldi L, Brandi C, D'Aniello C. Abdominoplasty in mildly obese patients (BMI 30-35 kg/m²): metabolic, biochemical and complication analysis at one year. *In Vivo* 2015; 29:757-61.
- D'Aniello C, Cuomo R, Grimaldi L, Brandi C, Sisti A, Tassinari J, Nisi G. Superior pedicle mammoplasty without parenchymal incisions after massive weight loss. *J Invest Surg* 2017; 30:410.

FUNDING

No specific funding received for this study

TRANSPARENCY DECLARATION

Competing interests: None to declare